

Case Report

Adjuvant Radiochemotherapy with a 23-Month Overall Survival Time in a Patient after a Surgery due to Splenic Hemangiosarcoma Rupture: A Case Report with the Literature Review

M. Bilski ^{1,2}, D. Surdyka,² I. Paśnik,³ M. Bilska,⁴ P. Cisek ^{1,5}, P. Korona ², J. Szumiło,³
and L. Grzybowska-Szatkowska^{1,6}

¹Chair and Department of Oncology, Medical University of Lublin, Lublin, Poland

²Radiation Therapy Department, Lublin Oncological Center, Lublin, Poland

³Chair and Department of Clinical Pathomorphology, Medical University of Lublin, Lublin, Poland

⁴1st Gynecological Oncology and Gynecology Clinic, Independent Public Clinical Hospital No. 1 in Lublin, Lublin, Poland

⁵Brachytherapy Department, Lublin Oncological Center, Lublin, Poland

⁶Radiotherapy Department, Lublin Oncological Center, Lublin, Poland

Correspondence should be addressed to M. Bilski; bilskimat@gmail.com

Received 31 July 2017; Revised 28 November 2017; Accepted 18 January 2018; Published 11 February 2018

Academic Editor: Peter F. Lenehan

Copyright © 2018 M. Bilski et al. This is an open access article distributed under the Creative Commons Attribution License, which permits unrestricted use, distribution, and reproduction in any medium, provided the original work is properly cited.

Spleen sarcoma is one of the most rare soft tissue malignancies. The annual incidence is 0.14–0.25/1,000,000 and the average age of diagnosis is 50 to 73 years. The incidence of this cancer has been increasing. Treatment of choice is surgical splenectomy, which rarely gives good results due to the aggressive course of the disease as well as the high potential for metastasis. Overall survival in primary spleen sarcomas as described by various authors is between 4 and 14 months. 80% of patients after spleen rupture do not survive 6 months. We report the case of a 42-year-old male diagnosed with spleen angiosarcoma. The patient underwent surgery in an emergency mode because of rapid rupture of the organ. Due to positive surgical margins, he underwent adjuvant radiochemotherapy followed by chemotherapy. Overall survival time was relatively long (23 months). The international guidelines provide information based on limited data. The role of postoperative radiotherapy in angiosarcomas remains controversial. Postoperative radiotherapy may increase local disease control, especially after nonradical operation, but this does not translate into improvement in overall survival time of these patients. The case shows that adjuvant radiotherapy as part of cancer treatment strategy may prolong the overall survival.

1. Introduction

Sarcomas are malignant tumors that develop from mesenchymal tissue. Among soft tissue sarcomas, spleen sarcoma (sarcoma lienale) is one of the most rare neoplasms. The annual incidence is 0.14–0.25 cases per million [1], and the average age of diagnosis is 50 to 73 years [2–4]. In recent years, the incidence of this cancer has been increasing. Because of the rare nature of these neoplasms and the short overall survival time of patients, often no more than 6 months after diagnosis [5], there are no established standards of clinical practice. The case report presents the therapeutic treatment in patient with

splenic hemangiosarcoma, diagnosed at the time of organ rupture.

2. Case Report

A 42-year-old patient was hospitalized for severe abdominal pain in the surgery department. That was the first and foremost symptom of the disease reported by him. The following laboratory tests were out of the norm: leukocytes (WBC) $10.83 \times 10^3/\text{mm}^3$, hemoglobin (HGB) 10.8 g/dL, red blood cell (RBC) count $4.16 \times 10^6 \text{ cells}/\text{mm}^3$, and C-reactive protein (CRP) –79.25 mg/l. The abdominal spiral computed tomography (CT) examination was performed that showed

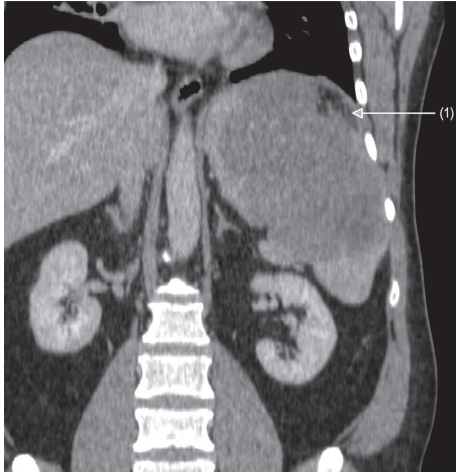


FIGURE 1: Abdominal CT scan showing an enlarged spleen with its visible rupture (1) and bleeding outside the capsule.

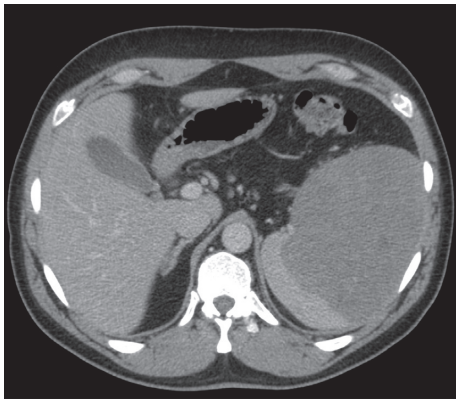


FIGURE 2: Abdominal CT scan performed before the surgery. Significant spleen enlargement is visible with distinctive area of parenchyma affected by the angiosarcoma.

spleen enlargement with a nonhomogeneous polycyclic contrast-enhanced lesion and bleeding in the infiltrative lesion with slight bleeding outside the fibroelastic capsule of the organ (Figures 1 and 2). The affected spleen adhered to the greater curvature of the stomach, so the invasion of its wall could not have been ruled out. On the 7 December 2011, the spleen was dissected with the larger curvature of the stomach. The postoperative course was uneventful.

Gross examination of surgical specimen showed enlarged spleen (15 × 15 × 7.5 cm) with poorly demarcated, infiltrating tumor (size 3 × 3 × 3 cm) of heterogeneous, hemorrhagic appearance with necrotic areas and cystic spaces filled with blood. Capsule of the spleen was ruptured. On histopathological examination, tumor was composed of nodules formed by vascular capillaries of various sizes and cavernous-like spaces filled with red blood cells. Vascular spaces were lined by endothelial cells with high-grade atypia. Multiple haemorrhages with partly organised thrombi, hemophagocytosis, and hemosiderin deposition were present. Tumor cells showed brisk mitotic activity and high-proliferative index (44% of Ki-67-positive nuclei of

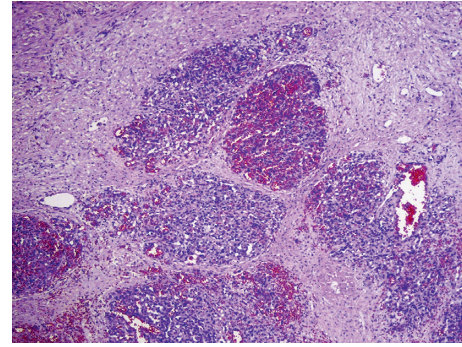


FIGURE 3: Microscopic view of angiosarcoma with hemorrhagic areas and vascular channels lined by endothelial atypical cells (hematoxylin and eosin staining, 100x).

neoplastic cells). Immunohistochemically, the neoplastic cells expressed endothelial antigens—CD31 and CD34—smooth muscle actin (ASMA), and vimentin. Focal expression of factor VIII was also present. Cytokeratin, CD117, and S100 protein immunohistochemical staining were negative (Figures 3–5). A separated sample of the surgical margin from the greater curvature of stomach showed angiosarcoma infiltration. Lymph nodes were not involved. According to TNM (2009) classification, tumor was assessed as T2bN0M0. Patient was qualified for adjuvant chemoradiotherapy. Chemotherapy was administered according to the regimen: paclitaxel 80 mg/m²/d, on days 1, 8, and 15 and every 28 days. With the second course of chemotherapy, 3D conformal radiation therapy (3DCRT) has been launched, with 18 MV radiation and cone beam computed tomography (CBCT). A dose of 45 Gy (fraction dose 1.8 Gy) was given to the tumor bed with additional boost to the area of larger curvature of the stomach to a total dose of 50.4 Gy due to the positive surgical margins (Figures 6(a) and 6(b)). During radiotherapy, the patient received one course of chemotherapy. The treatment was well tolerated. No acute toxicity was observed. The patient received 6 cycles of chemotherapy in total. After the third cycle of chemotherapy, stabilization of disease (SD) was confirmed in CT. The treatment was complicated by side effects such as pneumonia, which resolved after antibiotic therapy with amoxicillin, grade III leucopenia, and grade IV neutropenia. The patient received granulocyte-colony stimulating factors (G-CSFs). CT performed in December 2012 showed no local recurrence or dissemination.

The abdominal magnetic resonance imaging in February 2013 showed the presence of multiple small metastatic changes in the liver. Time to dissemination after completion of the first-line treatment was 13 months. The patient was qualified for the second-line chemotherapy consisting of ifosfamide 5 g/m² i.v. on day 1, cisplatin 100 mg/m² i.v. on day 2, and Adriamycin 60 mg/m² i.v. on day 2, every 21 days. G-CSFs were used as prophylaxis of neutropenia. After the third cycle, the patient had pancytopenia. Laboratory examination showed grade II leucopenia (WBC 1.12 × 3.3/mm³), grade IV neutropenia (neutrophils 0.23 × 10³/mm³), grade III anemia (HGB 8.2 g/dl), and grade II thrombocytopenia (platelets 40 × 10³/mm³). The patient received 3 units of red blood cell concentrates, G-CSFs,

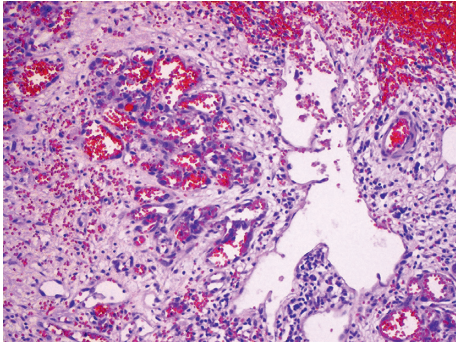


FIGURE 4: Vascular capillaries of various sizes and cavernous-like spaces lined by endothelial cells with high-grade atypia (hematoxylin and eosin staining, 200x).

and prophylactic antibiotic therapy with ceftazidime. SD was confirmed in a CT scan. The patient was qualified for three further cycles of chemotherapy. Second-line systemic treatment consisting of 6 courses ended in September 2013. Control CT scan showed progression of the disease. There was a confirmed enlargement of liver metastasis and multiple metastases to both lungs. The patient was qualified for palliative 3rd-line monotherapy regimen with the Nevelbin 30 mg/m², on days 1, 8, and 15 and every 28 days. After the second cycle of chemotherapy, the patient was hospitalized because of hematuria and anemia: HGB 9.8 g/dl, HCT 29.9%, and D-dimer 59942 ng/ml. In the abdominal ultrasonography, further progression of metastatic changes in the liver and a new hyperechogenic metastasis in the right kidney were demonstrated. Due to a worsening performance status, the patient was qualified for best supportive care (BSC). The patient died in November 2013.

3. Discussion

Spleen sarcomas are characterized by a high metastatic potential and lack of specific clinical signs in early stages. There are cases of these neoplasms in the literature, which were accompanied by symptoms of a tumor in the area of left upper abdomen, abdominal pain, fatigue, weight loss, fever, hepatomegaly, splenomegaly, anemia, and thrombocytopenia [3]. In some cases, leucocytosis and thrombocytosis may occur, as in the case of the patient described by us. In about 30% of reported cases, the first manifestation of the disease was a spontaneous rupture of the spleen [4]. Overall survival time in primary spleen sarcomas as described by various authors is between 4 and 14 months. 80% of patients after spleen rupture do not survive 6 months [5]. A slightly better prognosis of up to 11 months was found only among patients who had the spleen removed before rupture [4, 6]. Histopathological diagnosis shows a heterogeneous, non-specific image. Dominant elements are disorganized vascular connections, which are split by large, atypical endothelial cells distinguished by irregular hyperchromatic nuclei [7]. Both well-differentiated and poorly differentiated changes may have a similar, aggressive course. Mitotic index and tumor size are prognostic factors [8]. The pathologic differential

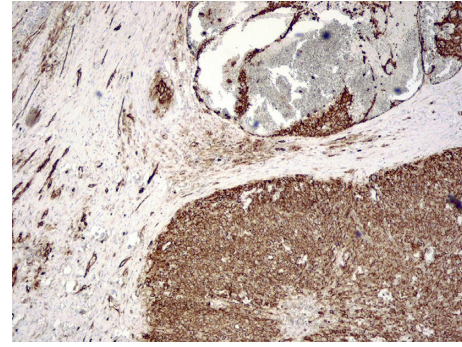


FIGURE 5: Immunohistochemical stain for CD34 highlights the malignant endothelial cells (200x).

diagnosis included hematoma, infarct, hamartoma, and benign vascular neoplasms (hemangioma and lymphangioma). In our case, other vascular tumor (Kaposi sarcoma) was considered, but extensive necrosis, high-grade atypia of tumor cells, and presence of red blood cells supported the diagnosis of angiosarcoma. Other malignant mesenchymal tumors were ruled out based on typical microscopic features, multiple vascular channel formations, and results of immunohistochemical staining (positive endothelial markers CD31 and CD34). Despite the aggressive course of the disease as well as the high potential for metastasis, splenectomy is still the only method described in the literature that gives the opportunity to achieve satisfactory long-term results. Postoperative assessment of the histopathological sample is fundamental. Negative surgical margins are the most important factors affecting disease-free survival time. In the case of unresectable disease, neoadjuvant treatment in the form of chemotherapy, radiotherapy, or chemoradiotherapy is acceptable, although BSC remains the treatment of choice. In cases of disease progression in the form of metastasis which occurs after the primary surgical treatment, doxorubicin can be used as monotherapy [9]. In the next line of treatment, it is possible to administer paclitaxel monotherapy 1x a week. Thirty patients with metastatic or unresectable, locally advanced disease were included into the phase II prospective study. Two-month PFS was achieved in 74% patients and 4-month PFS in 45%. Average time of progression was 4 months, and overall survival (OS) time was 8 months [10]. Similar results were achieved by Hirata et al. [11]. Interestingly, the expression of TLE3 (transducin-like enhancer of split 3) was associated with a better response to taxanes therapy, which makes it a positive predictive factor [12]. Olaratumab monoclonal antibody binding to the platelet-derived growth factor receptor alpha (PDGFRA) was approved by FDA (U.S. Food and Drug Administration) in October 2016 for the treatment of soft tissue sarcomas in association with doxorubicin [13]. Doxorubicin with olaratumab is currently recommended for the use rather than doxorubicin monotherapy in the first-line treatment of metastatic sarcoma, especially in angiosarcoma. It seems that this regimen should be used instead of chemotherapy based on doxorubicin with ifosfamide because of better tolerance. Some data on the use of angiogenesis inhibitors are promising [14] and even described CR (complete remission) [15] although the

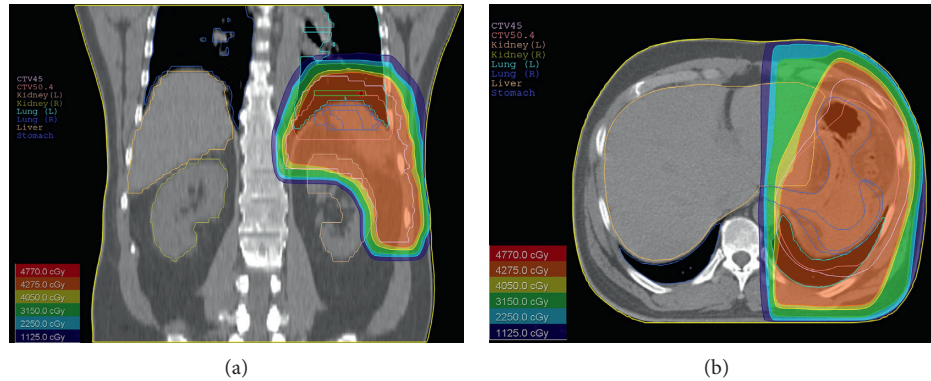


FIGURE 6: The coronal scope (a) and axial scope (b) of radiotherapy plan and dose distribution illustrated by different isodoses.

addition of bevacizumab to paclitaxel resulted in shortening OS (15.9 versus 19.5 months) [16].

There is little information in the literature about the use of radiotherapy in angiosarcoma, particularly in relation to abdominal or retroperitoneal space origination. In retrospective analysis of 48 patients with different head and neck sarcomas (29.2% angiosarcoma), radiotherapy was used as a separate treatment or part of combined therapy. Five-year LC (local control), LRC (local-regional control), DFS (disease-free survival), and OS values were 87, 73, 63, and 83%, respectively. Patients with angiosarcoma had poorer outcomes than those with other types of sarcomas [17]. Other uses of radiotherapy in patients with angiosarcoma have been reported by Hata et al. In that study, radiotherapy was used in 17 patients with scalp angiosarcomas. The percentage of patients without progression, local relapse, and distant metastases after 1-year follow-up was 86, 67, and 38%, respectively. After 3-year follow-up, it was 86, 38, and 16%, respectively. The authors also point out that a dose of 50 Gy or less may be too low for local control, requiring a dose of at least 70 Gy for bigger lesions [18].

It is important to note that, in most cases, the incidence of angiosarcoma irradiation is extremely rare, with most cases concerning other types of intra-abdominal sarcomas. Because of that, it is important to pay particular attention to the possibility of using irradiation on this type of cancer as adjuvant treatment, especially after a surgical procedure carried out because of a life-threatening situation, such as spleen rupture. In our case, the use of adjuvant chemoradiotherapy after radical surgery (positive microscopic margins) enables to achieve significant prolongation of OS which was 23 months, compared to the average OS of patients with this course of disease, which is only 6 months

4. Summary

Treatment results are still very bad in angiosarcoma. Radiotherapy is an important and underestimated treatment for this type of neoplasm, particularly as an adjuvant approach after surgery performed because of splenic rupture. Because of the rarity of the disease, obtaining reliable clinical evidence requires more data.

Conflicts of Interest

The authors declare that they have no conflicts of interest.

Authors' Contributions

M. Bilski, L. Grzybowska-Szatkowska, D. Surdyka, I. Paśnik, and J. Szumiło wrote the first draft and revised the manuscript. D. Surdyka, L. Grzybowska-Szatkowska, P. Korona, and P. Cisek cared for the patients. P. Korona, M. Bilski, and M. Bilaska prepared the figures and drafted legends. M. Bilski, L. Grzybowska-Szatkowska, and M. Bilaska have been crucial in designing the work and supervising the draft revision. All authors read and approved the final manuscript.

References

- [1] W. M. Thompson, A. D. Levy, N. S. Aguilera, L. Gorospe, and R. M. Abbott, "Angiosarcoma of the spleen: imaging characteristics in 12 patients," *Radiology*, vol. 235, no. 1, pp. 106–115, 2005.
- [2] A. Manouras, P. Giannopoulos, L. Toufektzian et al., "Splenic rupture as the presenting manifestation of primary splenic angiosarcoma in a teenage woman: a case report," *Journal of Medical Case Reports*, vol. 2, no. 1, p. 133, 2008.
- [3] S. Falk, J. Krishnan, and J. M. Meis, "Primary angiosarcoma of the spleen, a clinicopathologic study of 40 cases," *The American Journal of Surgical Pathology*, vol. 17, no. 10, pp. 959–970, 1993.
- [4] J. Sauer, "Primary and metastatic cancer of the spleen," *The Spleen*, p. 192, 2011.
- [5] S. Hu, C. E. Bueso-Ramos, S. Verstovsek et al., "Metastatic splenic angiosarcoma presenting with thrombocytopenia and bone marrow fibrosis mimicking idiopathic thrombocytopenic purpura and primary myelofibrosis: a diagnostic challenge," *Clinical Lymphoma Myeloma and Leukemia*, vol. 13, no. 5, pp. 629–633, 2013.
- [6] H. Jun-Te, C. Han-Ming, L. Chin-Yew et al., "Primary angiosarcoma of the spleen," *Journal of Surgical Oncology*, vol. 92, no. 4, pp. 312–316, 2005.
- [7] T. S. Neuhauser, G. A. Derringer, L. D. Thompson et al., "Splenic angiosarcoma: a clinicopathologic and immunophenotypic study of 28 cases," *Modern Pathology*, vol. 13, no. 9, pp. 978–987, 2000.

- [8] N. Naka, M. Ohsawa, and Y. Tomita, "Prognostic factors in angiosarcoma: a multivariate analysis of 55 cases," *Journal of Surgical Oncology*, vol. 61, no. 3, pp. 170–176, 1996.
- [9] F. Kohutek, L. Badik, and B. Bystricky, "Primary angiosarcoma of the spleen: rare diagnosis with atypical clinical course," *Case Reports in Oncological Medicine*, vol. 2016, Article ID 4905726, 6 pages, 2016.
- [10] N. Penel, B. N. Bui, J. O. Bay et al., "Phase II trial of weekly paclitaxel for unresectable angiosarcoma: the ANGIOTAX Study," *Journal of Clinical Oncology*, vol. 26, no. 32, pp. 5269–5274, 2008.
- [11] T. Hirata, K. Yonemori, M. Ando et al., "Efficacy of taxane regimens in patients with metastatic angiosarcoma," *European Journal of Dermatology*, vol. 21, no. 4, pp. 539–545, 2011.
- [12] W. Shon, S. M. Jenkins, D. T. Ross et al., "Angiosarcoma: a study of 98 cases with immunohistochemical evaluation of TLE3, a recently described marker of potential taxane responsiveness," *Journal of Cutaneous Pathology*, vol. 38, no. 12, pp. 961–966, 2011.
- [13] A. Tobias, M. P. O'Brien, and M. Agulnik, "Olaratumab for advanced soft tissue sarcoma," *Expert Review of Clinical Pharmacology*, vol. 10, no. 7, pp. 699–705, 2017.
- [14] C. Yoo, J. E. Kim, S. K. Yoon et al., "Angiosarcoma of the retroperitoneum: report on a patient treated with sunitinib," *Sarcoma*, vol. 2009, Article ID 360875, 4 pages, 2009.
- [15] A. Alvarado-Miranda, L. Bacon-Fonseca, U. Lara-Medina et al., "Thalidomide combined with neoadjuvant chemotherapy in angiosarcoma of the breast with complete pathologic response: case report and review of literature," *Breast Care*, vol. 8, no. 1, pp. 74–76, 2013.
- [16] I. L. Ray-Coquard, J. Domont, E. Tresch-Bruneel et al., "Paclitaxel given once per week with or without bevacizumab in patients with advanced angiosarcoma: a randomized phase II trial," *Journal of Clinical Oncology*, vol. 33, no. 25, pp. 2797–2802, 2015.
- [17] L. K. Vitzthum, L. C. Brown, J. W. Rooney, and R. L. Foote, "Head and neck soft tissue sarcomas treated with radiation therapy," *Rare Tumors*, vol. 8, no. 2, pp. 61–65, 2016.
- [18] M. Hata, H. Wada, I. Ogino et al., "Radiation therapy for angiosarcoma of the scalp: treatment outcomes of total scalp irradiation with X-rays and electrons," *Strahlentherapie und Onkologie*, vol. 190, no. 10, pp. 899–904, 2014.