

Laparoscopic Removal of an Incidental Ectopic Liver: Short Report of a Case

Cem Algin^a Faik Yaylak^a Esra Gurlek Olgun^b
Mehmet Caglikulekci^c

Departments of ^aGeneral Surgery and ^bPathology, Dumlupinar University Hospital, Kutahya, and ^cDepartment of General Surgery, Mersin University Faculty of Medicine, Mersin, Turkey

Key Words

Laparoscopy · Ectopic liver · Choristoma · Ectopic nodule

Abstract

Ectopic liver is a rare clinical entity, which may be rarely of clinical importance. It is generally reported to be small in size and without a connection to the mother liver. A case of an incidental ectopic liver nodule that was connected with a vascular peduncle to the Couinad segment IVa of the liver has been reported. Microscopic examination revealed chronic inflammatory changes, which should be considered to be the result of intermittent circulatory disturbances.

Introduction

Ectopic livers have been reported to be rare developmental errors which may be found incidentally during laparoscopy, laparotomy or autopsy [1, 2]. They are usually small in diameter, and do not generally cause a clinical problem [2, 3]. The basic difference between the ectopic livers and the accessory liver lobes is the lack of a connection between mother liver and ectopic liver [3]. We report a case of an incidental ectopic liver nodule that was connected with a vascular pedicle to the Couinad segment IVa of the liver.

Case Report

A 39-year-old woman with symptomatic gallstone disease was scheduled for a routine laparoscopic cholecystectomy. Blood biochemistry evaluation was in normal ranges. Transabdominal ultrasonography revealed a 12 mm gallstone in the gallbladder.

Under general anesthesia laparoscopy was performed and a pedunculated ectopic liver tissue 5 × 7 mm in size was observed in the medial superior segment of the right hepatic lobe during the

exploration. The vascular peduncle was clipped and the ectopic tissue was removed successfully after a routine laparoscopic cholecystectomy was completed. The postoperative course was uneventful.

Histopathological examination showed hydropic degeneration in the hepatocytes and periportal bile ducts with minimal chronic inflammatory process ([fig. 1](#)).

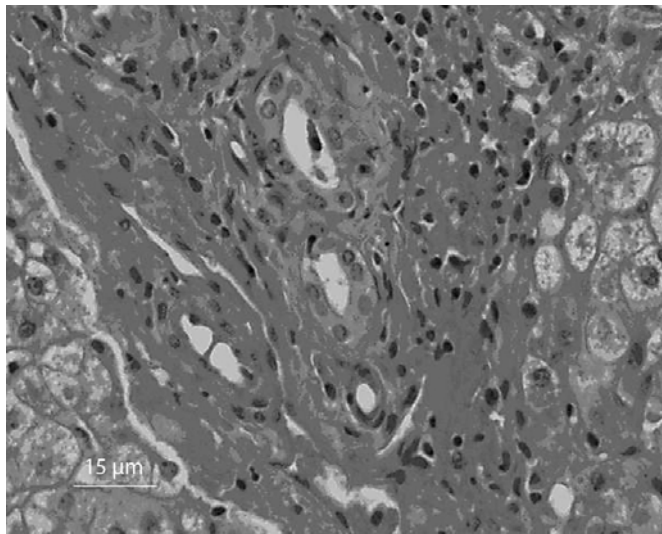
Discussion

Ectopic livers and accessory liver lobes have been reported to be rare clinical entities, which generally are of no clinical importance [1, 3]. However, development of hepatocellular carcinoma in ectopic livers, compression of the adjacent structures due to the mass effect and torsion of ectopic livers have been reported. They have been described usually in the vicinity of liver such as on the gallbladder, hepatic ligaments, diaphragm, thoracic cavity, adrenal glands, pancreas, omentum, spleen, esophagus and umbilical cord [1–8]. Ectopic livers have been generally reported not to have a connection to the mother liver. This may be explained with disappearance of the previously presented connection by time [3]. In our case a vascular peduncle was observed. After ligation of the vascular peduncle ischemic color changes were observed during the excision of the ectopic liver.

Most reports of ectopic liver cases indicate normal microscopic examination findings. However, cases have been reported with HCC in ectopic livers [1, 9]. In our case, chronic inflammatory changes were observed under microscopic examination. Since the ectopic liver was connected to the mother liver with a vascular peduncle, it was considered that intermittent disturbances of circulation had lead to these changes as a result of tissue ischemia. However, as the ectopic liver was relatively small in size, these ischemia periods were not referred to the clinic of the patient.

In conclusion, although incidental ectopic livers are rare and do not have clinical importance, they should be looked for during laparoscopy and/or laparotomy and microscopic examination should be carried out to exclude pathological changes since development of hepatocellular carcinoma is a possible issue.

Fig. 1. Microscopic appearance of the ectopic liver.



References

- 1 Akarawa M, Kimura Y, Sakata K, et al: Propensity of ectopic liver to hepatocarcinogenesis: Case reports and a review of literature. *Hepatology* 1999;29:57–61.
- 2 Watanabe M, Matsura T, Takatori Y, et al: Five cases of ectopic liver and a case of accessory lobe of the liver. *Endoscopy* 1989;21:39–42.
- 3 Collan Y, Hakkiluoto A, Hastbacka J: Ectopic liver. *Ann Chir Gynaecol* 1978;67:27–29.
- 4 Babu R, Van der Avoirt A: Ectopic intrathoracic liver. *Pediatr Surg Int* 2001;17:461–462.
- 5 Iber T, Rintala R: Intrapulmonary ectopic liver. *J Pediatr Surg* 1999;34:1425–1426.
- 6 el Haddad MJ, Currie AB, Honeyman M: Pyloric obstruction by ectopic liver tissue. *Br J Surg* 1985;72:917.
- 7 Preminger A, Udassin R, Pappo O, Arad I: Ectopic liver tissue within the umbilical cord. *J Pediatr Surg* 2001;36:1085–1086.
- 8 Elsayes HB, Elzein MA, Razik AM, Olude IO: Torsion of an ectopic liver in a young child. *J Pediatr Surg* 2005;40:E55–E58.
- 9 Kim KA, Park CW, Kim CH, Choi SY, Park SW, Hong SJ, Seol HY, Cha IH: Hepatocellular carcinoma in an ectopic liver: CT findings. *Eur Radiol* 2003;13:L45–L47.