



# The Efficacy and Safety of Radiofrequency Ablation for Bilateral Papillary Thyroid Microcarcinoma

Lin Yan, Mingbo Zhang, Qing Song, Jing Xiao, Ying Zhang and Yukun Luo\*

Department of Ultrasound, First Medical Center, Chinese PLA General Hospital, Beijing, China

## OPEN ACCESS

### Edited by:

Terry Francis Davies,  
Icahn School of Medicine at Mount  
Sinai, United States

### Reviewed by:

Brian Lang,  
The University of Hong Kong, China  
Cristiane Jeyce Gomes-Lima,  
MedStar Health Research Institute  
(MHRI), United States

### \*Correspondence:

Yukun Luo  
lyk301@163.com

### Specialty section:

This article was submitted to  
Thyroid Endocrinology,  
a section of the journal  
Frontiers in Endocrinology

Received: 03 February 2021

Accepted: 03 May 2021

Published: 11 June 2021

### Citation:

Yan L, Zhang M, Song Q,  
Xiao J, Zhang Y and Luo Y (2021)  
The Efficacy and Safety of  
Radiofrequency Ablation for Bilateral  
Papillary Thyroid Microcarcinoma.  
*Front. Endocrinol.* 12:663636.  
doi: 10.3389/fendo.2021.663636

**Objective:** To investigate the long-term clinical results of radiofrequency ablation (RFA) for bilateral papillary thyroid microcarcinoma (PTMC).

**Materials and Methods:** From October 2014 to February 2018, 47 patients (37 females, 10 males, mean age  $43.39 \pm 9.26$  years) with 100 bilateral PTMC (mean volume  $75.22 \pm 73.87$  mm<sup>3</sup>) treated by RFA were included in this retrospective study. Bilateral PTMC was defined as at least one tumor located in the contralateral lobe. Patients were followed up at 1, 3, 6, 12 months and every 6–12 months thereafter. Volume, volume reduction ratio (VRR) and local tumor recurrence were evaluated during the follow-up period.

**Results:** After a mean follow-up period of  $47.77 \pm 11.54$  months, the mean volume of bilateral PTMC decreased from  $75.22 \pm 73.87$  mm<sup>3</sup> to  $0.09 \pm 0.44$  mm<sup>3</sup>. The mean VRR was  $99.94 \pm 0.28\%$  and the complete disappearance rate was 92.00%. During the follow-up, one patient (2.13%) developed lymph node metastasis and two patients (4.26%) had recurrent PTMC. All the recurrent lesions underwent additional RFA and two of them disappeared completely. No life-threatening or delayed complications occurred.

**Conclusions:** With sufficient preoperative evaluation, RFA might be a promising alternative for bilateral PTMC patients who were unsuitable for surgery or refused surgery.

**Keywords:** radiofrequency ablation, papillary thyroid carcinoma, thyroid, ultrasound, clinical outcomes

## INTRODUCTION

The incidence of thyroid cancer has increased worldwide, ranking in ninth among all cancers (1–4). Approximately 50% of the increase was attributed to the detection of papillary thyroid microcarcinoma (PTMC), which is a form of papillary thyroid cancer with a maximum diameter of 1 cm, with or without high-risk features (5). Bilateral lesions are very common in PTMC with an incidence of approximately 10–30% (6). It was previously correlated with a higher risk of locoregional recurrence. However, some studies have shown that tumor bilaterality was not associated with an increased risk of recurrence/persistence (7). According to the 8th AJCC/TNM risk of mortality system and American thyroid guideline (ATA) risk stratification, intrathyroidal bilateral PTMC was classified stage I with a low-risk of recurrence (8, 9). Surgery is the first-line treatment for bilateral PTMC. However, its drawbacks include invasiveness, cosmetic problems and life-long thyroid hormone replacement, which affect the quality of life (10). Moreover, the incidence of transient vocal fold paralysis and transient hypocalcemia after surgery were 5.5 and 4.3%,

respectively (11). Radiofrequency ablation (RFA) as a minimally invasive technique, might be a potentially alternative for bilateral PTMC who were unsuitable for surgery or are contraindicated for surgery.

RFA is a commonly used thermal technique, has been reported as an effective and safe treatment for low-risk PTMC patients who refuse surgery or active surveillance (12–19). After ablation, the pooled proportion of volume reduction rate (VRR) was 98.1% (20) and the pooled proportion of complete disappearance rate was 57.6–76.2% (20, 21). However, the results were based mainly on the clinical outcomes of RFA for unifocal PTMC. To the best of our knowledge, no study has reported the long-term clinical outcomes of ablation for bilateral PTMC.

Therefore, the purpose of this study was to evaluate the efficacy and safety of RFA for bilateral PTMC.

## MATERIALS AND METHODS

The Institutional Review Board of our institution approved this retrospective study. All the patients were provided written information consent before RFA. The RFA informed consent emphasized that surgery was the routine treatment recommended by guidelines.

### Patients

Bilateral PTMC was defined as at least one tumor located in the contralateral lobe (11). The inclusion criteria were: (1) PTMC lesions were confirmed by core-needle biopsy (CNB) or fine-needle aspiration (FNA); (2) no evidence of extrathyroidal extension (ETE) or lymph node (LN)/distant metastasis on US and chest CT; (3) patients who were unsuitable for surgery or refused surgery; (4) no neck irradiation history; (5) follow-up period was  $\geq 24$  months. The exclusion criteria of patients were: (1) no convincing evidence of aggressive disease by biopsy (9); (2) the maximum diameter of the tumor was  $\geq 10$  mm; (3) ETE was found; (4) LN metastasis or distant metastasis was detected; (5) patients with conscious disturbance or coagulation disorder or serious primary disease; (6) follow-up period was  $< 24$  months.

From October 2014 to February 2018, 468 patients with bilateral PTMC underwent treatment in this institution. Among them, 76 patients who were unsuitable for surgery or rejected surgery underwent RFA. Among them, patients with follow-up period less than 24 months ( $N = 29$ ) were excluded. At last, a total of 47 patients with 100 low-risk PTMC were evaluated.

### Pre-Ablation Evaluation

Before RFA, patients all underwent thorough examinations, including complete blood count, thyroid function tests, coagulation tests and imaging evaluation, including ultrasound and chest CT (12–14). The volume of PTMC was calculated with the equations:

$$V = \pi abc / 6$$

$V$  is the volume, while  $a$  is the largest diameter,  $b$  and  $c$  are the other two perpendicular diameters.

US were performed using a Siemens Acuson Sequoia 512 Ultrasound System (Siemens) or a Philips iU22 Ultrasound System (Philips Healthcare) or a Mindray M9 Ultrasound System (Mindray). CNB and RFA were all performed using a Siemens Acuson Sequoia 512 Ultrasound System. Contrast-enhanced ultrasound (CEUS) was used to assess the tumor before and immediately after RFA procedure. The ultrasound contrast agent was sulfur hexafluoride (SonoVueR). After injection of 2.4 ml SonoVue followed by a 5 ml of normal saline flush, CEUS was applied to observe the real-time microbubble perfusions within the tumor and the surrounding thyroid tissues.

### Ablation Procedures

All RFA procedures were performed by an experienced US physician. A bipolar RFA generator (CelonLabPOWER) and an 18-gauge bipolar RF applicator with 0.9 cm active tip (CelonProSurge micro 100-T09) were used.

Patients lay on an operating table in the supine position with the neck hyperextended. The targeted tumor was evaluated by multi-angle scanning to determine a practical and proper approach. Doppler ultrasound was used to access the detailed vascular anatomy along the approach route to prevent bleeding. Local anesthetic (1% lidocaine) was injected at the subcutaneous puncture site and the thyroid anterior capsule. During the RFA procedure, the smaller lesion was ablated first.

RFA procedure was performed using trans-isthmus approach and moving-shot technique. To prevent thermal injury, hydrodissection technique was performed by injection of normal saline to separate the target tumor from critical structures (trachea, carotid artery, jugular vein, esophagus and recurrent laryngeal nerve). Normal saline was injected using another needle (23 gauge) to form at least 1 cm distance between the tumor and the critical structure (13, 14).

The initial RFA power was 3 W and was increased to 5 to 9 W if a transient hyperechoic zone did not form at the electrode tip in 10 s. To prevent marginal residue and recurrence, we enlarged the ablation area which exceeded the tumor edge (at least 3–5 mm) (21, 22). CEUS was performed immediately after the RFA procedure to assess the ablation area. If any enhancement existed, a complementary RFA should be applied.

### Post-Ablation Assessment

Patients were followed up at 1, 3, 6 months and every 6–12 months thereafter by US, CEUS and chest CT. At 3 or 6 months after RFA, the ablated area was evaluated by CNB, which was performed to the central zone, the peripheral zone and surrounding thyroid parenchyma (22–24). The development of metastatic LNs and the suspicious new lesions were submitted to biopsy. The volume reduction rate (VRR) was calculated by the equations:

$$VRR = \frac{(\text{initial volume} - \text{final volume})}{\text{initial volume}} \times 100\%$$

RFA was considered to successful when one of the criteria were met (25): (1) the ablated tumor was completely disappearance;

(2) the ablated tumor remained as scar-like on US but absence of enhancement on both arterial and venous phase on CEUS; (3) If the ablation area still existed, no malignant cells was confirmed by CNB. Local tumor recurrence was defined to include two situations (26): (1) new lesion was confirmed to be PTMC after CNB; (2) cervical LN metastasis was confirmed after biopsy. Distant metastasis was diagnosed by CT, positron emission tomography or bone scan when there were suspicious symptoms. Delayed surgery is defined as that patients received surgery due to tumor progression or anxiety during the follow-up.

## Statistical Analysis

Statistical analysis was performed using the SPSS statistical software (Version 25.0). Continuous data were presented as mean  $\pm$  SD (range). Non-parametric Wilcoxon signed-rank tests were used to compare the pre-ablation with post-ablation volume as each follow-up period. A  $P < 0.05$  was considered as statistically significant.

## RESULTS

Clinical characteristics of patients before RFA are shown in **Table 1**. Among the 47 patients, 41 had two tumors and six had three tumors. The mean diameter was  $4.82 \pm 1.57$  mm and the mean volume was  $75.22 \pm 73.87$  mm<sup>3</sup>. The volume of dominant tumor was  $108.77 \pm 87.08$  mm<sup>3</sup>.

**TABLE 1** | Clinical characteristics of patients.

Characteristics	Data
No. of patients	47
No. of tumors	100
Patients with two tumors, n (%)	41 (87.23)
Patients with three tumors, n (%)	6 (12.77)
Age (years)	43.39 $\pm$ 9.26 (23–63)
Female (%)	37 (78.72)
Mean diameter (mm)	4.81 $\pm$ 1.57 (0.20–0.93)
Mean Volume (mm <sup>3</sup> )	75.22 $\pm$ 73.87 (4.19–424.10)
Volume of dominant tumor (mm <sup>3</sup> )	108.77 $\pm$ 87.08 (8.12–424.10)

Data are expressed as mean  $\pm$  SD (range).

**TABLE 2** | Changes of the volume and VRR after RFA at each follow-up.

Time	Volume (mm <sup>3</sup> )		<i>p</i> value (Vs initial volume)	VRR (%)	
	Mean $\pm$ SD	range		Mean $\pm$ SD	range
initial	75.22 $\pm$ 73.87	4.19–424.10	–	NA	
After RFA	664.13 $\pm$ 410.00	109.95–1,858.20	<0.001	NA	
1 month	314.35 $\pm$ 331.09	10.47–2,205.33	<0.001	–511.78 $\pm$ 569.06	–2,600–100
3 months	114.02 $\pm$ 231.45	0–1,910.03	<0.001	–76.40 $\pm$ 227.17	–985.71–100
6 months	44.31 $\pm$ 105.58	0–680.66	<0.001	43.01 $\pm$ 123.00	–585.71–100
12 months	21.11 $\pm$ 64.77	0–376.98	<0.001	77.85 $\pm$ 62.28	–255.56–100
18 months	9.76 $\pm$ 37.86	0–241.90	<0.001	84.97 $\pm$ 62.85	–350.00–100
24 months	3.29 $\pm$ 11.97	0–75.40	<0.001	96.97 $\pm$ 12.84	3.57–100
36 months	0.25 $\pm$ 1.42	0–9.42	<0.001	98.78 $\pm$ 1.28	91.43–100
48 months	0.09 $\pm$ 0.44	0–2.09	<0.001	99.94 $\pm$ 0.28	98.64–100

NA, not applicable.

For each tumor, the mean power was  $3.92 \pm 0.98$  W. The mean RFA time was  $224.09 \pm 156.68$  s and the mean energy was  $853.64 \pm 614.39$  J.

## Efficacy

The changes of volume and VRR after RFA at each follow-up visit are presented in **Table 2**. The mean follow-up period was  $47.77 \pm 11.54$  months (range 24–76 months). The mean volume of the ablation areas was significantly larger than the initial volume at first 3 months ( $P < 0.001$ ) because of the enlarge ablation, which was gradually decreased from 6 months after RFA (**Figure 1**). The mean VRR was  $99.94 \pm 0.28\%$  (**Figure 2**) and the overall complete disappearance rate was 92.00% (92/100). The numbers of completely disappearance were 1 (1.00%), 12 (12.00%), 21 (21.00%), 26 (26.00%), 18 (18.00%), 10 (10.00%) and 4 (4.00%) at 1, 3, 6, 12, 18, 24, and 36 months after RFA, respectively. A representative case underwent RFA is presented in **Figure 3**.

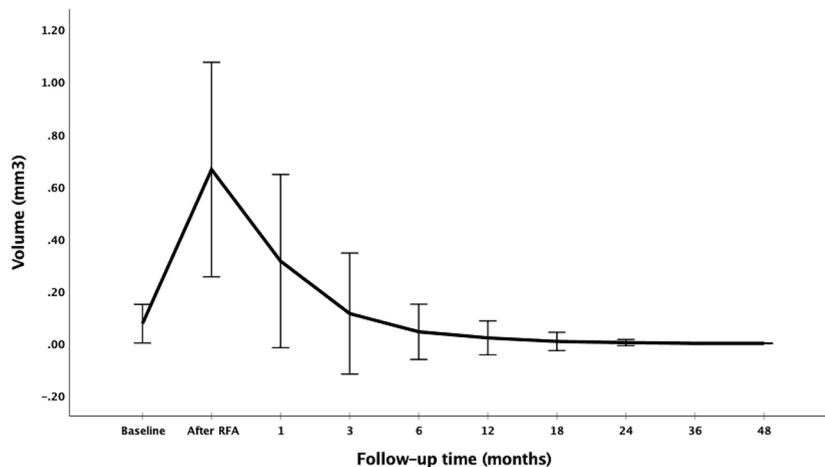
## Local Tumor Recurrence

Because 13 tumors disappeared in the first 3 months and another six tumors disappeared at 6 months, a total of 81 tumors underwent post-ablation CNB and the results were all negative.

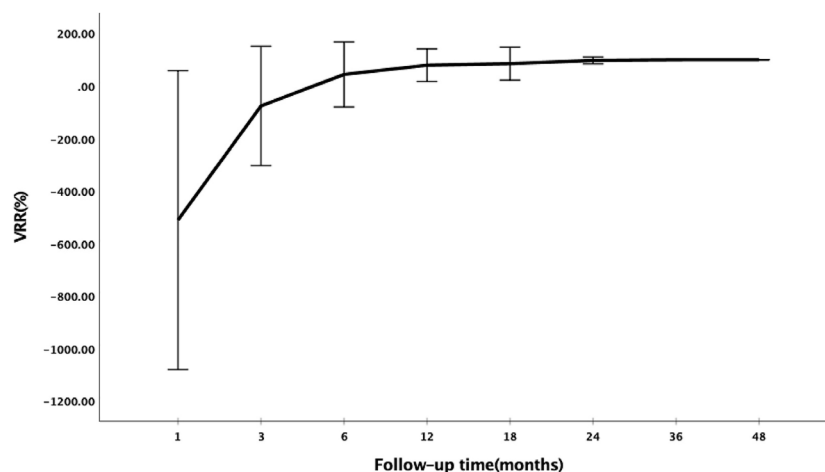
The incidence of LN metastasis and of recurrence PTMC was 2.13% (1/47) and 4.26% (2/47), respectively. No distant metastasis was detected. No patient underwent delayed surgery during the follow-up. The clinical characteristics and outcomes of PTMC patients with local tumor recurrence are showed in **Table 3**. One patient developed LN metastasis in the central compartments at 12 months after RFA with a volume of 100.53 mm<sup>3</sup>. Two patients had recurrent PTMC and the volume was 18.85 mm<sup>3</sup> and 153.93 mm<sup>3</sup>, respectively. All of these three patients underwent additional RFA. Two recurrent PTMCs were completely disappeared during the follow-up. The metastatic LN shrunk to 37.70 mm<sup>3</sup> after 1-year follow-up. This lesion underwent CNB and demonstrated no malignancy.

## Safety

All the 47 patients were tolerable to RFA. Four patients underwent local pain or discomfort and they all resolved spontaneously within 3 days. No patients had major or delayed complications.



**FIGURE 1** | Changes of volume at each follow-up period after RFA.



**FIGURE 2** | Changes of VRR at each follow-up period after RFA.

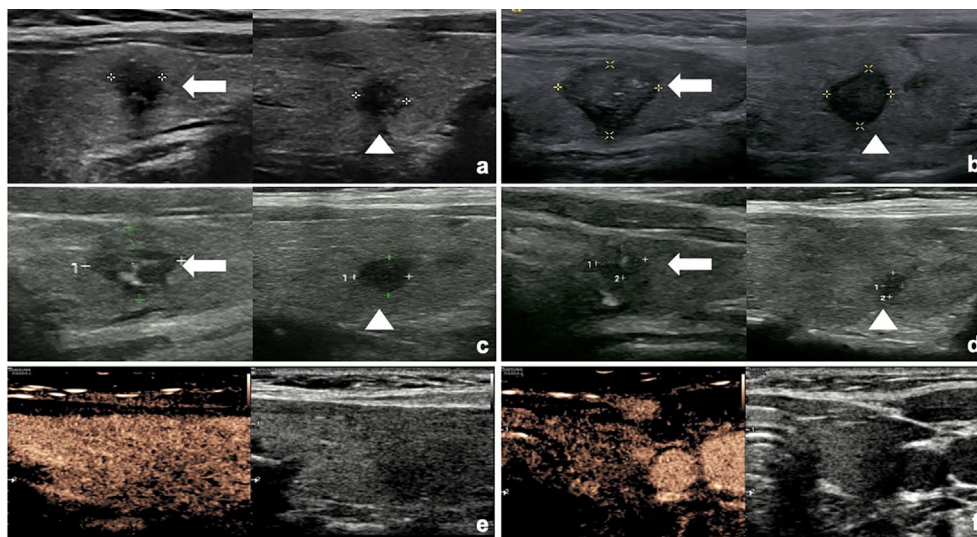
## DISCUSSION

To date, no study has been evaluated the clinical application of RFA for bilateral PTMC. In this study, after a mean follow-up period of  $47.77 \pm 11.54$  months, the mean volume of bilateral PTMC decreased from  $75.36 \pm 73.86 \text{ mm}^3$  to  $0.09 \pm 0.43 \text{ mm}^3$  with a mean VRR of  $99.94 \pm 0.28\%$ . A total of 92 tumors disappeared completely. The incidences of LN metastasis and of recurrent PTMC were 2.13 and 4.26%, respectively. All recurrent lesions were successfully treated with an additional RFA. No major complications or sequelae were observed.

Bilaterality has been observed in approximately 10–30% of patients with PTMC (6). It refers to the presence of multiple synchronous primary tumors, arising from independent clones, instead of intraglandular metastasis from a single primary tumor *via* intraglandular lymphatics (27, 28). However, the prognostic

value of bilateral PTMC remains controversial. Studies recommended more aggressive treatments such as total thyroidectomy with central neck dissection and subsequent radioactive iodine ablation therapy for bilateral PTMC, which has an increased loco-regional recurrence rate (29, 30). In contrast, Choi et al. (7) found that bilateral PTMC was not an important prognostic factor in PTMC patients, but in the non-PTMC patients. Zhou et al. (6) also reported that bilateral PTMC was significantly associated with central LN metastasis on the univariate analysis. However, this was not an independent risk factor after multivariate logistic regression analysis. The conflicting results were likely due to the early detection and treatment of bilateral lesions, which did not fully exhibit its biological behavior.

Although thermal ablation is not the first-line treatments for PTMC, it has been applied to unifocal low-risk PTMC patients



**FIGURE 3** | The US and CEUS images of a 32-year-old female with bilateral PTMC during the follow-up. **(A)** Before RFA, two PTMC lesions were confirmed by CNB. One tumor was located in the left lobe with an initial volume of  $78.54 \text{ mm}^3$  (arrow) and the other one was in right lobe with an initial volume of  $65.45 \text{ mm}^3$  (arrowhead). **(B)** At 1 month after RFA, the volume of left tumor (arrow) was  $898.47 \text{ mm}^3$  and the volume of right tumor (arrowhead) was  $234.57 \text{ mm}^3$ . **(C)** At 3 months after RFA, the volume of left tumor (arrow) was  $226.19 \text{ mm}^3$  and the volume of right tumor (arrowhead) was  $78.54 \text{ mm}^3$ . **(D)** At 6 months after RFA, the volume of left tumor (arrow) was  $50.26 \text{ mm}^3$  and the volume of right tumor (arrowhead) was  $12.57 \text{ mm}^3$ . **(E, F)** At 12 months after RFA, these two ablated tumors both disappeared.

**TABLE 3** | The clinical characteristics and outcomes of patients with local tumor recurrence.

	No. of patients	Sex/age	No. of PTMC lesions	Dominant tumor Location/Volume ( $\text{mm}^3$ )	Developed Time (months)	Location	Volume ( $\text{mm}^3$ )	Treatment	Outcomes
LN metastasis (N = 1)	1	F/34	2	Isthmus/150.79	12	Right, Level VI	100.53	RFA	$37.70^a$
Recurrent PTMC (N = 2)	1	F/43	2	Left/43.33	6	Right lobe	18.85	RFA	Disappeared at 12-month after additional RFA
	2	F/32	2	Right/53.33	12	Right lobe	153.93	RFA	Disappeared at 12-month after additional RFA

<sup>a</sup>Data are represented as the volume at last follow-up ( $\text{mm}^3$ ).

concerned about active surveillance or complications after surgery (17, 25, 31–38). A few patients with multifocal or bilateral PTMC were also treated with ablation, but the clinical outcomes were not reported separately (14–16, 39). The viability of RFA as an alternative for bilateral PTMC patients who refuse surgery or are unsuitable for surgery is unknown. This study included 100 bilateral PTMC lesions in 47 patients who were unsuitable for surgery or refused surgery. This was the first study to evaluate the clinical results of RFA for bilateral PTMC. After a mean follow-up period of  $47.77 \pm 11.54$  months, the VRR was  $99.94 \pm 0.28\%$  and 92% of tumors completely disappeared. This was consistent with previous studies on RFA for unifocal PTMC, which reported a VRR of 90–100%, with a complete disappearance rate of 15.22–100% (17, 25, 31–38). This demonstrated that the efficacy of RFA for bilateral PTMC was comparable to that of unifocal PTMC.

In terms of safety, a meta-analysis reported that the pooled proportion of overall complications after thermal ablation was 3.1% and major complications occurred in 0.7% (20). The pooled proportion of complications after RFA was 1.7% (21). In this study, only four patients experienced local pain or discomfort. None of the patients experienced major complications. Several strategies were related to the low incidence of complications. First, RFA was performed by an experienced physician. A detailed preoperative evaluation and adequate knowledge of neck anatomy on US could minimize the incidence of complication (40). Second, during the RFA procedure, smaller lesion was usually treated first and the needle tip was monitored continuously and cautiously *via* US. Third, safe precautions against thermal injuries, such as the moving-shot technique, trans-isthmus approach and hydrodissection technique, were also performed during the RFA procedure (40).

The local tumor recurrence rate after ablation for unifocal PTMC is low. A previous study showed that the incidence of LN metastasis and recurrent PTMC following unifocal PTMC ablation were 0.84–2.98 and 1.19–2.78%, respectively (25, 34–38). A similar incidence of LN metastasis (2.13%) was observed in this study. However, the incidence of recurrent PTMC for bilateral PTMC was 4.26%, which was higher than that for unifocal PTMC. This was likely due to the low sensitivity of US in detecting multiple tumors. Thus, occult tumor foci may have been missed by preoperative evaluation. Although all recurrent lesions were successfully treated by additional RFA, sufficient preoperative evaluation was crucial in identifying the number and location of tumors and formulating an appropriate treatment strategy. Surgery remains the first-line treatment for bilateral PTMC. However, patients who refuse or are ineligible for surgery can opt for RFA for palliative purposes, with fully informed consent and thorough follow-up management.

This study had some limitations. First, it was a single-center retrospective study. Second, the sample size of bilateral PTMC cases was relatively small. Third, the follow-up period was relatively short. Given the good prognosis of PTMC, further studies with a larger number of bilateral PTMC patients and a more extended follow-up period are needed. Fourth, this study did not compare RFA with surgery for the treatment of bilateral PTMC.

In conclusion, with sufficient preoperative evaluation, RFA might be a promising treatment for bilateral PTMC patients who were unsuitable for surgery or refused surgery.

## REFERENCES

- Bray F, Ferlay J, Soerjomataram I, Siegel RL, Torre LA, Jemal A. Global Cancer Statistics 2018: GLOBOCAN Estimates of Incidence and Mortality Worldwide for 36 Cancers in 185 Countries. *CA Cancer J Clin* (2018) 68 (6):394–424. doi: 10.3322/caac.21492
- Lubitz CC, Sosa JA. The Changing Landscape of Papillary Thyroid Cancer: Epidemiology, Management, and the Implications for Patients. *Cancer* (2016) 122(24):3754–9. doi: 10.1002/cncr.30201
- Chmielik E, Rusinek D, Oczko-Wojciechowska M, Jarzab M, Krajewska J, Czarniecka A, et al. Heterogeneity of Thyroid Cancer. *Pathobiology* (2018) 85 (1–2):117–29. doi: 10.1159/000486422
- La Vecchia C, Malvezzi M, Bosetti C, Garavello W, Bertuccio P, Levi F, et al. Thyroid Cancer Mortality and Incidence: A Global Overview. *Int J Cancer* (2015) 136(9):2187–95. doi: 10.1002/ijc.29251
- Miyauchi A, Ito Y, Oda H. Insights Into the Management of Papillary Microcarcinoma of the Thyroid. *Thyroid* (2017) 28(1):23–31. doi: 10.1089/thy.2017.0227
- Zhou YL, Gao EI, Zhang W, Yang H, Guo GL, Zhang XH, et al. Factors Predictive of Papillary Thyroid Micro-Carcinoma With Bilateral Involvement and Central Lymph Node Metastasis: A Retrospective Study. *World J Surg Oncol* (2012) 10:67. doi: 10.1186/1477-7819-10-67
- Choi WR, Roh JL, Gong G, Cho KJ, Choi SH, Nam SY, et al. Multifocality of Papillary Thyroid Carcinoma as a Risk Factor for Disease Recurrence. *Oral Oncol* (2019) 94:106–10. doi: 10.1016/j.oraloncology.2019.05.023
- Tuttle RM, Haugen B, Perrier ND. Updated American Joint Committee on Cancer/Tumor-Node-Metastasis Staging System for Differentiated and Anaplastic Thyroid Cancer (Eighth Edition): What Changed and Why? *Thyroid* (2017) 27(6):751–6. doi: 10.1089/thy.2017.0102
- Haugen BR, Alexander EK, Bible KC, Doherty GM, Mandel SJ, Nikiforov YE, et al. 2015 American Thyroid Association Management Guidelines for Adult Patients With Thyroid Nodules and Differentiated Thyroid Cancer: The

## DATA AVAILABILITY STATEMENT

The raw data supporting the conclusions of this article will be made available by the authors, without undue reservation.

## ETHICS STATEMENT

The studies involving human participants were reviewed and approved by The Institutional Review Board of Chinese PLA General Hospital. The patients/participants provided their written informed consent to participate in this study.

## AUTHOR CONTRIBUTIONS

LY interpreted the patient data and drafted the manuscript. YKL performed RFA procedure, and conceived of the study and coordination. MBZ, QS, JX, and YZ collected and analyzed the patient data. All authors contributed to the article and approved the submitted version.

## FUNDING

This study is supported by Beijing Municipal Science & Technology Commission (No. Z181100001718017) and the Research of Healthcare Big Data of Chinese PLA General Hospital (2019MBD-040).

- American Thyroid Association Guidelines Task Force on Thyroid Nodules and Differentiated Thyroid Cancer. *Thyroid* (2015) 26(1):1–133. doi: 10.1089/thy.2015.0020
- Zanocco KA, Hershman JM, Leung AM. Active Surveillance of Low-Risk Thyroid Cancer. *JAMA* (2019) 321(20):2020–1. doi: 10.1001/jama.2019.5350
- Jeon YW, Gwak HG, Lim ST, Schneider J, Suh YJ. Long-Term Prognosis of Unilateral and Multifocal Papillary Thyroid Microcarcinoma After Unilateral Lobectomy Versus Total Thyroidectomy. *Ann Surg Oncol* (2019) 26(9):2952–8. doi: 10.1245/s10434-019-07482-w
- Cho SJ, Baek SM, Lim HK, Lee KD, Son JM, Baek JH. Long-Term Follow-Up Results of Ultrasound-Guided Radiofrequency Ablation for Low-Risk Papillary Thyroid Microcarcinoma: More Than 5-Year Follow-Up for 84 Tumors. *Thyroid* (2020) 30(12):1745–51. doi: 10.1089/thy.2020.0106
- Zhang Y, Zhang MB, Luo YK, Li J, Zhang Y, Tang J. Effect of Chronic Lymphocytic Thyroiditis on the Efficacy and Safety of Ultrasound-Guided Radiofrequency Ablation for Papillary Thyroid Microcarcinoma. *Cancer Med* (2019) 8(12):5450–8. doi: 10.1002/cam4.2406
- Zhang M, Luo Y, Zhang Y, Tang J. Efficacy and Safety of Ultrasound-Guided Radiofrequency Ablation for Treating Low-Risk Papillary Thyroid Microcarcinoma: A Prospective Study. *Thyroid* (2016) 26(11):1581–7. doi: 10.1089/thy.2015.0471
- Wu R, Luo YK, Tang J, Yang M, Li J, Zhang Y, et al. Ultrasound-Guided Radiofrequency Ablation for Papillary Thyroid Microcarcinoma: A Retrospective Analysis of 198 Patients. *Int J Hyperthermia* (2020) 37 (1):168–74. doi: 10.1080/02656736.2019.1708480
- Lim HK, Cho SJ, Baek JH, Lee KD, Son CW, Son JM, et al. US-Guided Radiofrequency Ablation for Low-Risk Papillary Thyroid Microcarcinoma: Efficacy and Safety in a Large Population. *Korean J Radiol* (2019) 20(12):1653–61. doi: 10.3348/kjr.2019.0192
- Kim J-h, Baek JH, Sung JY, Min HS, Kim KW, Hah JH, et al. Radiofrequency Ablation of Low-Risk Small Papillary Thyroidcarcinoma: Preliminary Results

- for Patients Ineligible for Surgery. *Int J Hyperthermia* (2017) 33(2):212–9. doi: 10.1080/02656736.2016.1230893
18. Ding M, Tang X, Cui D, Chi J, Shi Y, Wang T, et al. Clinical Outcomes of Ultrasound-Guided Radiofrequency Ablation for the Treatment of Primary Papillary Thyroid Microcarcinoma. *Clin Radiol* (2019) 74(9):712–7. doi: 10.1016/j.crad.2019.05.012
  19. Zhang M, Tufano RP, Russell J, Zhang Y, Zhang Y, Qiao Z, et al. Ultrasound-Guided Radiofrequency Ablation Versus Surgery for Low Risk Papillary Thyroid Micro-Carcinoma: Results of Over 5 Years Follow-Up. *Thyroid* (2020) 30(3):408–17. doi: 10.1089/thy.2019.0147
  20. Choi Y, Jung SL. Efficacy and Safety of Thermal Ablation Techniques for the Treatment of Primary Papillary Thyroid Microcarcinoma: A Systematic Review and Meta-Analysis. *Thyroid* (2020) 30(5):720–31. doi: 10.1089/thy.2019.0707
  21. Tong M, Li S, Li Y, Li Y, Feng Y, Che Y. Efficacy and Safety of Radiofrequency, Microwave and Laser Ablation for Treating Papillary Thyroid Microcarcinoma: A Systematic Review and Meta-Analysis. *Int J Hyperthermia* (2019) 36(1):1278–86. doi: 10.1080/02656736.2019.1700559
  22. Nikfarjam M, Muralidharan V, Christophi C. Mechanisms of Focal Heat Destruction of Liver Tumors. *J Surg Res* (2005) 127(2):208–23. doi: 10.1016/j.jss.2005.02.009
  23. Ahmed M, Brace CL, Lee FT, Goldberg SN. Principles of and Advances in Percutaneous Ablation. *Radiology* (2011) 258(2):351–69. doi: 10.1148/radiol.10081634
  24. Shin JH, Baek JH, Ha EJ, Lee JH. Radiofrequency Ablation of Thyroid Nodules: Basic Principles and Clinical Application. *Int J Endocrinol* (2012) 2012:919650–. doi: 10.1155/2012/919650
  25. Yan L, Lan Y, Xiao J, Lin L, Jiang B, Luo Y. Long-Term Outcomes of Radiofrequency Ablation for Unifocal Low-Risk Papillary Thyroid Microcarcinoma: A Large Cohort Study of 414 Patients. *Eur Radiol* (2021) 31(2):685–94. doi: 10.1007/s00330-020-07128-6
  26. Teng DK, Li WH, Du JR, Wang H, Yang DY, Wu XL. Effects of Microwave Ablation on Papillary Thyroid Microcarcinoma: A Five-Year Follow-Up Report. *Thyroid* (2020). doi: 10.1089/thy.2020.0049
  27. So YK, Kim MW, Son YI. Multifocality and Bilaterality of Papillary Thyroid Microcarcinoma. *Clin Exp Otorhinolaryngol* (2015) 8(2):174–8. doi: 10.3342/ceo.2015.8.2.174
  28. Kaliszewski K, Diakowska D, Wojtczak B, Migon J, Kasprzyk A, Rudnicki J. The Occurrence of and Predictive Factors for Multifocality and Bilaterality in Patients With Papillary Thyroid Microcarcinoma. *Medicine (Baltimore)* (2019) 98(19):e15609. doi: 10.1097/md.00000000000015609
  29. Karatzas T, Vasileiadis I, Charitoudis G, Karakostas E, Tseleni-Balafouta S, Kouraklis G. Bilateral Versus Unilateral Papillary Thyroid Microcarcinoma: Predictive Factors and Associated Histopathological Findings Following Total Thyroidectomy. *Hormones* (2013) 12(4):529–36. doi: 10.14310/horm.2002.1441
  30. Cheng F, Chen Y, Zhu L, Zhou B, Xu Y, Chen Y, et al. Risk Factors for Cervical Lymph Node Metastasis of Papillary Thyroid Microcarcinoma: A Single-Center Retrospective Study. *Int J Endocrinol* (2019) 2019:8579828. doi: 10.1155/2019/8579828
  31. Yue W, Wang S, Yu S, Wang B. Ultrasound-Guided Percutaneous Microwave Ablation of Solitary T1N0M0 Papillary Thyroid Microcarcinoma: Initial Experience. *Int J Hyperthermia* (2014) 30(2):150–7. doi: 10.3109/02656736.2014.885590
  32. Zhou W, Jiang S, Zhan W, Zhou J, Xu S, Zhang L. Ultrasound-Guided Percutaneous Laser Ablation of Unifocal T1N0M0 Papillary Thyroid Microcarcinoma: Preliminary Results. *Eur Radiol* (2017) 27(7):2934–40. doi: 10.1007/s00330-016-4610-1
  33. Li J, Liu Y, Liu J, Qian L. Ultrasound-Guided Percutaneous Microwave Ablation Versus Surgery for Papillary Thyroid Microcarcinoma. *Int J Hyperthermia* (2018) 34(5):653–9. doi: 10.1080/02656736.2018.1453092
  34. Zhang L, Zhou W, Zhan W, Peng Y, Jiang S, Xu S. Percutaneous Laser Ablation of Unifocal Papillary Thyroid Microcarcinoma: Utility of Conventional Ultrasound and Contrast-Enhanced Ultrasound in Assessing Local Therapeutic Response. *World J Surg* (2018) 42(8):2476–84. doi: 10.1007/s00268-018-4500-6
  35. Ji L, Wu Q, Gu J, Deng X, Zhou W, Fan X, et al. Ultrasound-Guided Percutaneous Laser Ablation for Papillary Thyroid Microcarcinoma: A Retrospective Analysis of 37 Patients. *Cancer Imaging* (2019) 19(1):16. doi: 10.1186/s40644-019-0204-x
  36. Li J, Liu Y, Liu J, Yang P, Hu X, Qian L. A Comparative Study of Short-Term Efficacy and Safety for Thyroid Micropapillary Carcinoma Patients After Microwave Ablation or Surgery. *Int J Hyperthermia* (2019) 36(1):640–6. doi: 10.1080/02656736.2019.1626492
  37. Zhou W, Ni XF, Xu SY, Zhang L, Chen YD, Zhan WW. Ultrasound-Guided Laser Ablation Versus Surgery for Solitary Papillary Thyroid Microcarcinoma: A Retrospective Study. *Int J Hyperthermia* (2019) 36(1):897–904. doi: 10.1080/02656736.2019.1649475
  38. Yue WW, Qi L, Wang DD, Yu SJ, Wang XJ, Xu HX, et al. US-Guided Microwave Ablation of Low-Risk Papillary Thyroid Microcarcinoma: Longer-Term Results of a Prospective Study. *J Clin Endocrinol Metab* (2020) 105(6):1791–1800. doi: 10.1210/clinem/dgaa128
  39. Yan L, Luo Y, Zhang Y, Zhu Y, Xiao J, Lan Y, et al. The Clinical Application of Core-Needle Biopsy After Radiofrequency Ablation for Low-risk Papillary Thyroid Microcarcinoma: A Large Cohort of 202 Patients Study. *J Cancer* (2020) 11(18):5257–63. doi: 10.7150/jca.42673
  40. Kim JH, Baek JH, Lim HK, Ahn HS, Baek SM, Choi YJ, et al. 2017 Thyroid Radiofrequency Ablation Guideline: Korean Society of Thyroid Radiology. *Korean J Radiol* (2018) 19(4):632–55. doi: 10.3348/kjr.2018.19.4.632

**Conflict of Interest:** The authors declare that the research was conducted in the absence of any commercial or financial relationships that could be construed as a potential conflict of interest.

Copyright © 2021 Yan, Zhang, Song, Xiao, Zhang and Luo. This is an open-access article distributed under the terms of the Creative Commons Attribution License (CC BY). The use, distribution or reproduction in other forums is permitted, provided the original author(s) and the copyright owner(s) are credited and that the original publication in this journal is cited, in accordance with accepted academic practice. No use, distribution or reproduction is permitted which does not comply with these terms.