

# Phacoemulsification without hydroprocedure: A novel technique to deal with posterior polar cataracts

Narayan Bardoloi<sup>1</sup>, Sandip Sarkar<sup>1,2</sup>, Himangshu Das<sup>1</sup>, Pankaj S. Burgute<sup>1</sup>

Videos available on:  
www.saudijophthalmol.org

Access this article online

Quick Response Code:



Website:  
www.saudijophthalmol.org

DOI:  
10.4103/sjopt.sjopt\_22\_21

## Abstract:

**PURPOSE:** The purpose of the study was to describe a new phacoemulsification technique without hydroprocedures in patients of posterior polar cataract (PPC) and determine the posterior capsular rupture (PCR) and postoperative outcomes.

**METHODS:** We conducted a retrospective study with 115 eyes of 77 patients. After capsulorhexis, we insert the phaco tip inside the eye and do shaving of the cortex and epinucleus within the capsulorhexis area. The tip of the phacoemulsification probe is buried deep into the center of the nucleus and a anterior-posterior crack is fashioned. Then, the tip is placed at 7 o'clock position to chop away a triangular piece of the nucleus. A similar maneuver is done at 4 o'clock position to take out another piece. The phacoemulsification tip and the chopper are now positioned at the cracked site of the lower fragments. Using the two instruments, the fragments are now pushed away and easily emulsified.

**RESULTS:** The mean age of the study population was  $51.87 \pm 14.19$  years (range: 22–87 years). Of 77 patients, 39 (50.64%) patients had unilateral PPC and 38 (49.35%) had bilateral PPC. PCR occurred in 9 eyes (7.82%), among them two patients had fragment drop and only 1 (0.87%) patient was left aphakic. Best-corrected visual acuity (BCVA) at postoperative day 30 was 20/20 or better in 102 (88.69%) eyes, 20/32–20/80 was in 11 (9.56%) eyes, and BCVA 20/80–20/200 was in 2 (1.73%) eyes.

**CONCLUSION:** Phacoemulsification without hydroprocedure is a novel technique that can be successfully implemented in cases of PPC and can expect an excellent visual outcome.

## Keywords:

Hydroprocedure, phacoemulsification, posterior polar cataract

## INTRODUCTION

Posterior polar cataract (PPC) is a developmental cataract where an abnormal adhesion of the posterior capsule to the polar opacity or a preexisting weakness of the posterior capsule exists.<sup>[1]</sup> The promoting mechanism of development of PPC proposed is the persistence of hyaloid artery,<sup>[2,3]</sup> invasion of the lens by mesoblastic tissue,<sup>[4,5]</sup> and genetic mutations.<sup>[6,7]</sup> A positive family history has also been linked in 40%–55% of the cases.<sup>[8,9]</sup> PPC develops during embryonic life or early in infancy and becomes symptomatic at 30–50 years of age. However, the exact mechanism of formation is yet to be found. The reported incidence of PPC ranges

from 3 to 5 in 1000, with bilateral involvement in 65%–80% of cases.<sup>[2,3,8–10]</sup>

PPC can be classified based on the classification given by Singh, that is, Type 1: posterior polar opacity associated with a posterior subcapsular cataract; Type 2: sharply defined round or oval opacity with a ringed appearance like an onion, with or without greyish spots at the edge; Type 3: sharply defined round or oval white opacity with dense white spots at the edge often associated with thin or absent posterior capsule; Type 4: the combination of the above three types with nuclear sclerosis.<sup>[2]</sup>

PPC is characteristically different from other types of cataract because of the inherently weak, thin posterior capsule or the preexisting defect.<sup>[1,8]</sup> This makes phacoemulsification in

This is an open access journal, and articles are distributed under the terms of the Creative Commons Attribution-NonCommercial-ShareAlike 4.0 License, which allows others to remix, tweak, and build upon the work non-commercially, as long as appropriate credit is given and the new creations are licensed under the identical terms.

For reprints contact: WKHLRPMedknow\_reprints@wolterskluwer.com

**How to cite this article:** Bardoloi N, Sarkar S, Das H, Burgute PS. Phacoemulsification without hydroprocedure: A novel technique to deal with posterior polar cataracts. Saudi J Ophthalmol 2022;36:218-23.

<sup>1</sup>Cataract and Cornea Services, Chandraprabha Eye Hospital, Jorhat, Assam, <sup>2</sup>Department of Ophthalmology, Jawaharlal Institute of Post Graduate Medical Education and Research, Puducherry, India

## Address for correspondence:

Dr. Sandip Sarkar,  
Department of Ophthalmology,  
Jawaharlal Institute of Post  
Graduate Medical Education  
and Research, Gorimedu,  
Puducherry - 605 006, India.  
E-mail: drsandip19@gmail.  
com

Submitted: 04-Feb-2021

Revised: 08-Mar-2022

Accepted: 09-Mar-2022

Published: 29-Aug-2022

PPC a very challenging task due to the high risk of posterior capsular rupture (PCR) and nucleus drop. Previously published studies reported PCR rates varied from 0% to 36%.<sup>[8-16]</sup> Hydrodissection is primarily avoided in PPC because it may lead to accidental posterior capsule rupture (PCR) and result in nucleus drop.<sup>[17]</sup> Over the last few decades, many techniques have been described in the literature to deal with this challenge. “Hydrodelineation,”<sup>[18]</sup> “femto-delineation,”<sup>[18]</sup> “inside out delineation,”<sup>[16]</sup> “bimanual Phacoemulsification,”<sup>[12]</sup> “lambda technique,”<sup>[10]</sup> “V” groove technique,<sup>[19]</sup> “layer by layer phacoemulsification,”<sup>[20]</sup> “inverse horseshoe technique,”<sup>[21]</sup> and “Hook and flip technique”<sup>[22]</sup> for nucleus removal are few of these techniques. These techniques have one thing in common: all of them involve some or the other kind of hydroprocedure, i.e., hydrodissection or hydrodelineation.

We have described a new phacoemulsification technique in PPC s that does not require any kind of hydroprocedure. The present study was conducted to evaluate the PCR rate and assess the postoperative outcomes of the technique.

## METHODS

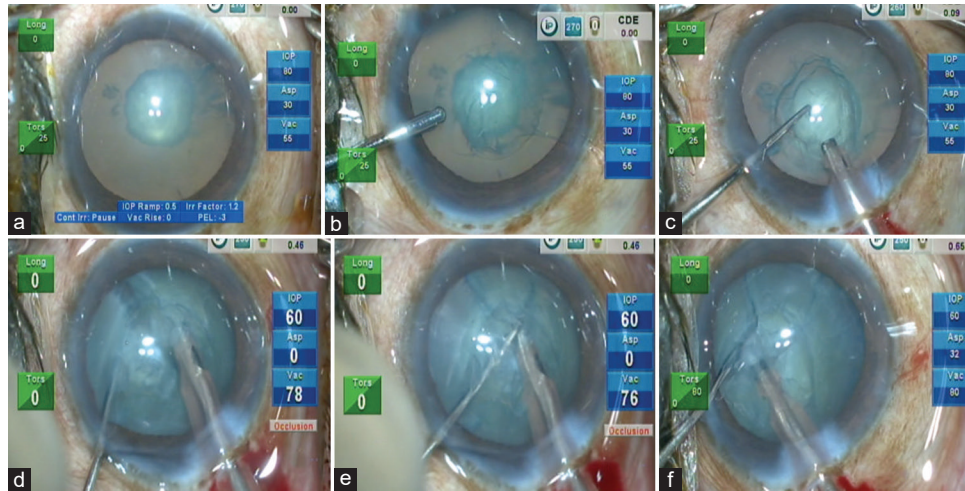
A retrospective, descriptive study was conducted at a tertiary eye care center in North-East India from January 2017 to December 2019. All the data were collected from the electronic medical records of the hospital. The study was approved by our hospital’s institutional review board (CPEH/IEC/2019-01-27) and adhered to the tenets of the Declaration of Helsinki. Informed written consent was obtained from all the participants. Patients aged 15–90 years with visually significant PPC scheduled for phacoemulsification surgery were included in the study. Patients with very soft PPC, traumatic cataracts, complicated cataracts, corneal opacity, uveitis, glaucoma, subluxated cataracts, pseudoexfoliation, and posterior segment disorders were excluded from the study.

A detailed preoperative ophthalmological evaluation including uncorrected visual acuity, best-corrected visual acuity (BCVA), intraocular pressure measurement with Goldmann Applanation Tonometer, slit-lamp examination to grade the cataract, and dilated fundus examination to rule out any posterior segment pathology was performed. Pupillary retro illumination was used to look for preexisting capsular defects. In cases of a dense cataract where fundus examination was inadequate due to hazy media, B-scan ultrasonography was performed. IOL Master-500 (Zeiss, Jena, Germany) used partial coherence laser interferometry for biometry. In cases of hazy media due to dense cataract, the axial length was obtained by immersion A-scan.

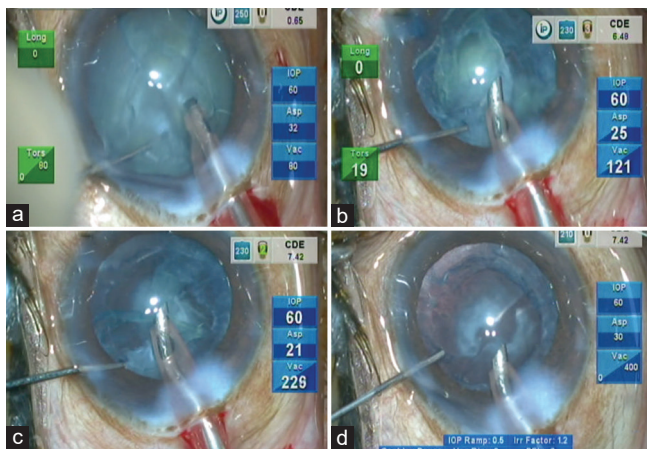
### Surgical technique

All surgeries were performed by a single experienced surgeon (NB) under topical anesthesia using proparacaine (0.5%) eye drops instilled into the lower conjunctival sac 10 min before surgery. All eyes had undergone torsional phacoemulsification (OZIL) using Centurion Vision System with balanced tip (Alcon laboratories, USA) under active

fluidics. Two 1 mm side port incisions were made at 2.30 and 9.30 o’clock. The bimanual irrigation/aspiration cannula’s irrigation cannula was introduced through the left-handed side port and 5 mm capsulorhexis was created under irrigation using 30G bent needle cystotome introduced through the right-hand side port incision [Figure 1a].<sup>[23]</sup> With the help of a dual bevel keratome, a 2.2 mm temporal limbal incision was fashioned under irrigation. The phacoemulsification probe was inserted into the eye on continuous irrigation mode without any hydroprocedure. The IOP was kept at 60 mmHg, phaco power: 80% OZIL, vacuum: 90 mmHg, and aspiration flow rate: 24 cc/min. Since most PPCs are soft nuclear cataracts, the parameters mainly remained the same in the subsequent steps. In the first step, aspiration of the loose cortex and epinucleus was done within the capsulorhexis margins [Figure 1b]. Then, sculpting was done to create a small groove in the middle of the nucleus. The nucleus was held at the designed groove with a phacoemulsification probe, and chop *in situ* was performed to produce a through-and-through anteroposterior crack in the nucleus [Figure 1c and Video 1].<sup>[24]</sup> The probe was then positioned at 7 o’clock position of the nucleus, and similar chopping was performed to fashion a pie-shaped nuclear piece [Figure 1d]. The piece was maneuvered into the phaco tip by the second instrument and emulsified. A similar maneuver was done at 4 o’clock to produce another piece of the nucleus that was subsequently emulsified [Figure 1e]. The remaining two pieces have adhered to the sub incisional area. These two were cracked but not separated. The phaco probe and the chopper were placed at the crack of the two pieces. The right sided nuclear fragment was hold with the phaco probe and the left sided fragment was separated using a chopper. The left sided fragment was brought in 6 o’clock position and subsequently emulsified [Figure 1f]. The other piece, which was then free of any attachment, could be easily rotated to be emulsified in the iris or capsular plane [Figure 2a]. In the cases of harder nuclei, a central crater was made, and then, the subsequent chops were being performed as discussed above. Most of the time, the epinucleus came out along with the nuclear pieces [Figure 2b]. It was pulled to the center from all sides to be aspirated at the end if that did not happen. On a few occasions, after initial chopping of the first two fragments, we did not emulsify them instantly; in spite, we separated all four pieces and then started the emulsification [Video 1]. Before removing the phaco probe from the anterior chamber, every time, we had filled the AC with dispersive OVD (Viscoat, Alcon Laboratories, Inc.,) to prevent the sudden collapse of the anterior chamber [Figure 2c]. Cortical material was aspirated using bimanual irrigation and aspiration cannula. A single-piece hydrophobic acrylic foldable intraocular lens (IOL) was implanted into the capsular bag [Figure 2d]. Preservative-free 0.5% moxifloxacin (Vigamox, Alcon laboratories, USA) 0.5 mg was injected into the anterior chamber. Main incision and side port incisions were sealed using stromal hydration. Postoperatively, all the patients received moxifloxacin eye drops (Vigamox, Alcon laboratories, USA) 4 times/day for 2 weeks and prednisolone acetate (1%) eye drops in tapering doses for 4 weeks.



**Figure 1:** (a) Approximately 5 mm capsulorhexis is performed using 30 G cystotome under irrigation, (b) Shaving of the cortex and epinucleus done within capsulorhexis area, (c) Primary chop and division of the nucleus into two halves done using chop in technique, (d) Nucleus is held at 7 o'clock position and chopping being done to take out a triangular piece of the nucleus, (e) Similar chopping performed at a 4 o'clock position of the nucleus with subsequent removal of a triangular piece of the nucleus, (f) The phaco tip and the chopper are being positioned at the cracked site of the lower two fragments. Using the two instruments, the fragments are pushed in the opposite direction and quickly taken out one after another



**Figure 2:** (a) The last nuclear piece rotated and emulsified, (b) The epinuclear sheet comes off very quickly and can be aspirated with the phaco probe with lower parameters, (c) Injection of viscoelastic agents before removing the phaco probe to prevent the collapse of the AC, (d) Intraocular lens implanted in the capsular bag

## RESULTS

Table 1 demonstrates the baseline characteristics of all the patients. In our study, 77 patients were there, among them 47 (61.03%) were male and 30 (38.96%) were female patients. The mean age of the study population was  $51.87 \pm 14.19$  years (range: 22–87 years). Of 77 patients, 39 (50.64%) patients had unilateral PPC s and 38 (49.35%) patients had bilateral involvement. Type 1, Type 2, Type 3, and Type 4 cataract was seen in 7 eyes (6.08%), 48 eyes (41.73%), 39 eyes (33.91%), and 21 eyes (18.26%), respectively [Table 2].

Phacoemulsification was completed in all the 115 cases. Of 115 operated eyes, PCR occurred in 9 eyes (7.82%) [Table 3]. Except in 2 eyes, the PCR occurred during the removal of the plaque. Prolapsed vitreous was stained with diluted

**Table 1: Baseline demographic of the patients**

Parameters	Values
Number of patients	77
Gender, n (%)	
Male	47 (61.03)
Female	30 (38.96)
Age (years), mean±SD (range)	51.87±14.19 (22-87)
Number of eyes, n (%)	115
Unilateral PPC	39 (50.64)
Bilateral PPC	38 (49.35)
PPC grade (according to Singh classification), n (%)	
Grade 1	7 (6.08)
Grade 2	48 (41.73)
Grade 3	39 (33.91)
Grade 4	21 (18.26)
UCVA, mean±SD	0.867±0.57 logMAR
BCVA, mean±SD	0.523±0.40 logMAR
Intraocular pressure (mmHg), mean±SD	13.34±2.34
Endothelial cell count (cells/mm <sup>2</sup> ), mean±SD	2356±256

UCVA: Uncorrected visual acuity, BCVA: Best-corrected visual acuity, SD: Standard deviation, PPC: Posterior polar cataract, logMAR: Logarithm of the Minimum Angle of Resolution

triamcinolone acetonide. Automated anterior vitrectomy was performed in every PCR case [Video 2]. Except for 1 case where anterior capsular support was inadequate, in every other case, a 3-piece hydrophobic IOL was implanted over the sulcus. The two cases which had PCR during chopping ended up with a small fragment drop into the vitreous cavity. Of two cases, one case had adequate capsular support, so a 3-piece hydrophobic IOL implanted on the table and pars plana vitrectomy with the fragmentation of the dropped fragment was done by the vitreoretinal surgeon on the same day. However, in another case, capsular support was <50%, so we left the case aphakic after complete anterior vitrectomy and scleral fixated IOL (SFIOL) was implanted 2 weeks later by our vitreoretinal surgeon.

The mean best-corrected visual acuity (BCVA) improved from a preoperative value of  $0.523 \pm 0.40$  log MAR to  $0.119 \pm 0.05$  log MAR at 1 month postoperatively ( $P < 0.00001$ , Wilcoxon rank-sum test). Meanwhile, BCVA at postoperative day 30 was 20/20 or better in 102 (88.69%) eyes, 20/32–20/80 was in 11 (9.56%) eyes, and BCVA 20/80–20/200 was in 2 (1.73%) eyes. One patient with proliferative diabetic retinopathy had a final postoperative BCVA of 6/24. There was no case of preexisting posterior capsular defect. Primary IOL implantation was successful in 114 cases. Secondary IOL (SFIOL) implantation was needed in 1 case. There was no case of nucleus drop, but nuclear fragment drop was noted occurred in 2 cases. Only 1 (0.87%) case left aphakic due to inadequate capsular support.

## DISCUSSION

Bardoloi *et al.* previously described the phacoemulsification without hydroprocedure technique.<sup>[23,25]</sup> The technique employs the natural flow of balanced salt solution to create a natural hydrodissection. First of all, aspiration of the cortex and epinucleus within the capsulorhexis margin allows the passage of fluid into the subcapsular space. Second, the nucleus is divided into two halves which allow fluid to pass and produce natural hydrodissection. Once the nucleus is chopped and emulsified, there is extensive “inside out” hydrodissection by the fluid of the phaco probe management of the remaining pieces becomes easy.<sup>[23,26]</sup> Incorporating this technique into the phacoemulsification of PPC gives us an advantage as hydrodissection could be harmful in this patient. We adhere to four basic principles while applying this procedure in PPC

surgery. The first principle is the creation of a central, round 5 mm sized capsulorhexis. The size of the capsulorhexis assumes much importance when there is PCR, and an IOL has to be placed in sulcus. Second, the phaco parameters were kept on the lower side and low bottle height. This ensures less turbulence in an already compromised eye with a vulnerable posterior capsule. Third, the anterior chamber is always filled up by injecting ophthalmic viscosurgical devices before withdrawing phaco or irrigating handpieces from the eye. This prevents vitreous pressure on the posterior capsule. Adequate use of the chopper by the left hand to pull or scoop out the chopped fragments from the bag constitutes the fourth principle applied in this technique. This prevents stress on the posterior capsule.

Phacoemulsification in PPC s has been challenging for cataract surgeons due to its propensity to produce more PCR than other cataracts. To date, there is no foolproof technique to tackle the challenges of PPC. Many techniques have been described in the literature to minimize the risk of posterior capsule rupture in this type of cataract. Hydrodelineation, inside-out hydrodelineation, femtodelineation, lambda technique of phacoemulsification, etc., are many such techniques.<sup>[10,16,18,21]</sup> All these techniques involve some sort of hydroprocedure. With any kind of hydroprocedure in PPC, the risk of PCR increases, as there is a chance of inadvertent subcapsular injection of the fluid and may cause an early tear in the posterior capsule.<sup>[16]</sup> Our technique is different in that respect, it does not involve any kind of hydroprocedure and hence negates the minimum risk involved with it. To the best of our knowledge, this is the first published study in literature where phacoemulsification has been performed without doing any hydroprocedure in PPC.

PPC is characterized by a central, dense, disk-shaped opacity located on the posterior capsule with concentric rings around the central plaque opacity that appear like a bull’s eye. The opacity has a cone-shaped projection in the subcapsular region of the central posterior cortex. There are two types of PPC: stationary and the other is progressive. The stationary type of PPC is compatible with good vision, and such patients do not seek early surgery. In progressive PPC, changes take place in the posterior cortex in the form of radiating rider opacities. Patients with progressive opacity become more symptomatic and come for early intervention.<sup>[1,27]</sup>

**Table 2: Distribution of cases according to the type of posterior polar cataract and their visual outcome**

Type of PPC	Number of eyes, n (%)	Postoperative BCVA		
		20/20 or better, n (%)	20/32-20/80, n (%)	20/80-20/200, n (%)
Grade I	7 (6.08)	7 (100)		
Grade II	48 (41.73)	44 (91.67)	4 (8.33)	
Grade III	39 (33.91)	36 (92.30)	3 (7.69)	
Grade IV	21 (18.26)	15 (71.42)	4 (19.04)	2 (9.52)
Total	115 (100)	102 (88.69)	11 (9.56)	2 (1.73)

BCVA: Best-corrected visual acuity, PPC: Posterior polar cataract

**Table 3: Demographic of all posterior capsular rupture cases**

Age	Sex	Eye	PCR in eye	Preoperative BCVA	PCR occurred	Postoperative BCVA on day 30	Remarks
54	Male	OU	OD	20/40	Plaque removal	20/32	AAV, 3-P IOL in sulcus
62	Male	OU	OS	20/40	Fragment removal	20/25	AAV, 3-P IOL in sulcus
68	Male	OS	OS	20/125	Plaque removal	20/63	AAV, 3-P IOL in sulcus
72	Female	OD	OD	20/63	Plaque removal	20/40	AAV, 3-P IOL in sulcus
62	Male	OS	OS	CF 3 mt	Chopping	20/200	Nuclear drop, AAV, 3-P IOL in sulcus
71	Male	OD	OD	20/200	Plaque removal	20/40	AAV, 3-P IOL in sulcus
31	Male	OU	OS	20/80	Epinucleus removal	20/32	AAV, 3-P IOL in sulcus
33	Male	OU	OS	20/40	Plaque removal	20/32	AAV, 3-P IOL in sulcus
68	Female	OD	OD	CF 2 mt	Chopping	20/200	Aphakia, SFIOL

CF: Counting fingers, AAV: Automated anterior vitrectomy, IOL: Intraocular lens, 3-P IOL: 3-piece IOL, SFIOL: Scleral fixated IOL, PCR: Posterior capsular rupture, BCVA: Best-corrected visual acuity, OU: Both eyes, OD: Right eye, OS: Left eye

**Table 4: Comparison of outcomes between our study and previously published studies**

Authors	Technique	Total number of eyes in series	PCR rate % (eyes)	Outcomes
Osher <i>et al.</i> <sup>[8]</sup>	Low power, low infusion, slow-motion phaco (+hydrodissection)	31	26 (8)	Vitreous loss 13% (4/31) Decentred IOL 6% (2/31)
Vasavada and Singh <sup>[9]</sup>	Delineation	25	36 (9)	
Lee and Lee <sup>[10]</sup>	Delineation	25	8 (2)	RD 7% (2/28) Dropped nucleus 4% (1/25)
Vasavada and Raj <sup>[16]</sup>	Inside out delineation	25	8 (2)	Dropped nucleus 4% (1/25)
Haripriya <i>et al.</i> <sup>[12]</sup>	Bimanual microphaco	8	12.5 (1)	
Das <i>et al.</i> <sup>[14]</sup>	Chip and flip for soft cataracts. Stop and chop for hard cataracts	81	31 (25)	Dropped nucleus 3% (2/81)
Malhotra <i>et al.</i> <sup>[31]</sup>	V or lambda sculpting, Viscodissection of epinucleus	80	7.5 (6)	Aphakia - 1.25% (1/80)
Siatiri and Moghimi <sup>[13]</sup>	Hydrodissection-free phacoemulsification technique <sup>*</sup>	38	0	
Salahuddin <sup>[21]</sup>	Inverse horseshoe technique	28	7.1	Two patients left with plaque
Current study	Phacoemulsification without hydroprocedure	115	7.82 (9)	1 aphakia, 1 fragment drop

PCR: Posterior capsular rupture, IOL: Intraocular lens, RD: Retinal detachment

One may ask why we avoided any hydroprocedure in our technique? The plaque in PPC may or may not be attached to the posterior capsule. The posterior capsule underneath the plaque may be extremely thin or maybe normal. It is challenging to put forward a firm opinion regarding the status of the posterior capsule or adherence of the plaque to it. The preexisting tear in the posterior capsule can be ascertained greatly by examination under the slit lamp, anterior segment optical coherence tomography (AS-OCT), and Scheimpflug imaging.<sup>[28-30]</sup> We have only used the pupillary retro illumination technique to look for PC defects, although AS-OCT or Scheimpflug imaging would have been a better option for identifying PC defects. According to the previous data, anterior segment OCT has a high negative predictive value and can predict the intactness of posterior capsule during phacoemulsification in PPC.<sup>[28]</sup> There was not a single eye with a preexisting tear in our series. Compared to the previously published study, the incidence of such tears in our finding is a little surprising. Geographical variation may be one explanation for lack of such type of PPC in our study.

The idea of delineation of the PPC by hydro, visco, or femto is to disassemble the endonucleus–epinucleus complex so that the vulnerable area at the posterior capsule remains protected. The high incidence of posterior capsule rupture during surgery might be due to two reasons. First, the plaque might be tight adherence to an otherwise normal capsule. Second, the posterior capsule underlying the plaque is exceptionally thin and ruptures to minimal trauma. Although looks innocuous, hydrodelamination may cause inadvertent hydrodissection, which may be dangerous in some PPC.<sup>[16]</sup> Forceful passage of fluid between the plaque and the capsule on attempted hydrodelineation may cause a tear in the capsule. Considering all these, we have developed the technique of phacoemulsification without hydroprocedure, which causes the slightest disturbance to the integrity of the posterior capsule in PPC.

Table 4 shows that the incidence of PCR, in our study, is 7.82%, which, when compared to other studies, is substantially lower in comparison to previously published studies such as Osher

*et al.* reported a 26% PCR rate, Vasavada and Singh reported 36% incidence, Hayashi *et al.* reported 7.1% PCR, Haripriya *et al.* reported 12.5% PCR, while Malhotra *et al.* reported 7.6% incidence rate of PCR in their respective studies.<sup>[8,9,11,12,31]</sup>

There were 38 cases of bilateral PPC, who had undergone bilateral cataract surgery sequentially. The mean time difference between the first and the second eye operation is  $11.28 \pm 7.28$  months, ranging from 1 to 71 months. The posterior capsular rupture occurred in four eyes among them. In two patients, the PCR was in the first eye, while it happened in the second eye in another two patients. Hence, this implies that the fate of the second eye surgery has no bearing on the result of the first eye.

In our case series, 102 (88.69%) patients got BCVA 20/20 or better after 1 month postoperatively which is better than few of the previously published studies such as Malhotra *et al.* reported 55 (68.75%) cases gaining BCVA of 20/20 or better, Salahuddin said 85.7% cases achieving BCVA 20/40 or better, and Osher *et al.* reported 96.7% of patients gaining BCVA 20/40 or better.<sup>[8,21,31]</sup>

### Limitation

Our study is descriptive, noncomparative, and retrospective in nature. An experimental study involving two groups, such as one without hydroprocedure and the other with a hydroprocedure, especially that done with hydrodelamination, would have given a direct comparison between the two techniques.

### CONCLUSION

Murphy's law states that whatever can go wrong will go wrong. This applies to phacoemulsification of PPC s too. Despite all these techniques and technologies, the incidence of PCR in PPC is still 7%. This is relatively high in comparison to the rate of PCR in general phacoemulsification surgery. This indicates that we are still to understand the behavior of PPC, and most of the time, we cannot prevent what is destined to happen.

### Financial support and sponsorship

Nil.

## Conflicts of interest

There are no conflicts of interest.

## REFERENCES

- Duke-Elder S. Normal and abnormal development; congenital deformities. In: System of Ophthalmology. Vol. 3. Mosby, St. Louis; 1964. p. 648-50.
- Consultation section. Cataract surgical problem. J Cataract Refract Surg 1997;23:1437-41.
- Vogt G, Horváth-Puhó E, Czeizel E. A population-based case-control study of isolated congenital cataract. Orv Hetil 2006;147:1077-84.
- Greeves R. Two cases of microphthalmia. Trans Ophthalmol Soc UK 1914;34:289-300.
- Szily A. The Doyne Memorial Lecture: The contribution of pathological examination to elucidation of the problems of cataract. Trans Ophthalmol Soc UK 1938;58:595-660.
- Addison P, Berry V, Ionides A, Francis P, Bhattacharya S, Moore A. Posterior polar cataract is the predominant consequence of a recurrent mutation in the PITX3 gene. J Med Genet 2005;42:313.
- Berry V, Francis P, Reddy MA, Collyer D, Vithana E, MacKay I, *et al.* Alpha-B crystallin gene (CRYAB) mutation causes dominant congenital posterior polar cataract in humans. Am J Hum Genet 2001;69:1141-5.
- Osher RH, Yu BC, Koch DD. Posterior polar cataracts: A predisposition to intraoperative posterior capsular rupture. J Cataract Refract Surg 1990;16:157-62.
- Vasavada A, Singh R. Phacoemulsification in eyes with posterior polar cataract. J Cataract Refract Surg 1999;25:238-45.
- Lee MW, Lee YC. Phacoemulsification of posterior polar cataracts – A surgical challenge. Br J Ophthalmol 2003;87:1426-7.
- Hayashi K, Hayashi H, Nakao F, Hayashi F. Outcomes of surgery for posterior polar cataract. J Cataract Refract Surg 2003;29:45-9.
- Haripriya A, Aravind S, Vadi K, Natchiar G. Bimanual microphaco for posterior polar cataracts. J Cataract Refract Surg 2006;32:914-7.
- Siatiri H, Moghimi S. Posterior polar cataract: Minimizing risk of posterior capsule rupture. Eye (Lond) 2006;20:814-6.
- Das S, Khanna R, Mohiuddin SM, Ramamurthy B. Surgical and visual outcomes for posterior polar cataract. Br J Ophthalmol 2008;92:1476-8.
- Nagappa S, Das S, Kurian M, Braganza A, Shetty R, Shetty B. Modified technique for epinucleus removal in posterior polar cataract. Ophthalmic Surg Lasers Imaging Retina 2011;42:78-80.
- Vasavada AR, Raj SM. Inside-out delineation. J Cataract Refract Surg 2004;30:1167-9.
- Vasavada AR, Vasavada VA. Managing the posterior polar cataract: An update. Indian J Ophthalmol 2017;65:1350-8.
- Vasavada AR, Vasavada V, Vasavada S, Srivastava S, Vasavada V, Raj S. Femtodelineation to enhance safety in posterior polar cataracts. J Cataract Refract Surg 2015;41:702-7.
- Kelman C. Groove phaco technique: Fast, easy, safe: Interview with. Dr Kelman Ophthalmol Times 1994;19:12.
- Vajpayee RB, Sinha R, Singhvi A, Sharma N, Titiyal JS, Tandon R. 'Layer by layer' phacoemulsification in posterior polar cataract with pre-existing posterior capsular rent. Eye (Lond) 2008;22:1008-10.
- Salahuddin A. Inverse horse-shoe technique for the phacoemulsification of posterior polar cataract. Can J Ophthalmol 2010;45:154-6.
- Gupta S, Selvan H, Khokhar S. Hook and flip technique: For phacoemulsification in non-rotating nuclei and posterior polar cataracts. Int Ophthalmol 2019;39:1219-23.
- Bardoloi N, Sarkar S, Pilania A, Das H. Pure phaco: Phacoemulsification without ophthalmic viscosurgical devices. J Cataract Refract Surg 2020;46:174-8.
- Vasavada AR, Desai JP. Stop, chop, chop, and stuff. J Cataract Refract Surg 1996;22:526-9.
- Bardoloi N, Sarkar S. A new technique of phacoemulsification without hydroprocedures. Kerala J Ophthalmol 2021;33:189.
- Lim Z, Goh J. Modified epinucleus pre-chop for the dense posterior polar cataract. Ophthalmic Surg Lasers Imaging Retina 2008;39:171-3.
- Vasavada AR, Vasavada VA, Raj SM. Approaches to a posterior polar cataract. Saudi J Ophthalmol 2012;26:51-4.
- Pavan Kumar G, Krishnamurthy P, Nath M, Baskaran P, Janani M, Venkatesh R. Can preoperative anterior segment optical coherence tomography predict posterior capsule rupture during phacoemulsification in patients with posterior polar cataract? J Cataract Refract Surg 2018;44:1441-5.
- Grewal DS, Jain R, Brar GS, Grewal SP. Scheimpflug imaging of pediatric posterior capsule rupture. Indian J Ophthalmol 2009;57:236-8.
- Arora R, Mehta S, Goyal JL, Jain S, Gupta D. Tear-drop sign of posterior capsule dehiscence on Scheimpflug imaging. Eye (Lond) 2010;24:737-8.
- Malhotra C, Dhingra D, Nawani N, Chakma P, Jain AK. Phacoemulsification in posterior polar cataract: Experience from a tertiary eye care Centre in North India. Indian J Ophthalmol 2020;68:589-94.