

## Case Report

DOI: 10.22114/ajem.v0i0.44

**Upper Gastrointestinal Bleeding as Delayed Presentation of Traumatic Diaphragmatic Hernia; a Case Report**

Ali Arhami-Dolatabadi, Mohammadmehdi Forouzanfar, Sahar Mirbaha\*

Department of Emergency Medicine, Faculty of Medicine, Shahid Beheshti University of Medical Sciences, Tehran, Iran.

\*Corresponding author: Sahar Mirbaha; Email: dr.saharmirbaha@gmail.com

Published online: 2018-01-15

**Abstract**

**Introduction:** Traumatic diaphragmatic hernia (TDH) is one of the critical complications resulting from penetrating chest trauma. The rate of undiagnosed TDH equivocates 12-60%. The significant part of complications happens 1-4 years after the primary damage. Here, we report a case of delayed TDH presented with upper gastrointestinal bleeding (GIB) as an excuse to discuss this issue.

**Case presentation:** The patient was a 35-year-old man, admitted with objection of abdominal pain. A nasogastric tube was inserted and fixed that resulted in drainage of about 500cc dark blood. He was candidate for emergent endoscopy due to upper GIB. During resuscitation measures, he suddenly developed respiratory distress that could not be justified by upper GIB alone. Therefore, bedside sonography discovered some soft tissue apart from lung tissue in the left hemithorax. After performing diagnostic measures, with diagnosis of diaphragmatic herniation and strangulation he underwent emergent surgery.

**Conclusion:** Small diaphragmatic lesions, which usually result from stab wounds, may develop into larger injuries if left untreated and they might lead to a diaphragmatic hernia with a potential risk of early or late complications and mortality. One of the rare complications is GIB, which should be considered in a patient with past history of trauma and presentation of GIB.

**Key words:** Case reports; Gastrointestinal hemorrhage; Hernia, diaphragmatic, traumatic; Wounds, stab

**Cite this article as:** Arhami-Dolatabadi A, Forouzanfar M, Mirbaha S. Upper Gastrointestinal Bleeding as Delayed Presentation of Traumatic Diaphragmatic Hernia; a Case Report. *Adv J Emerg Med.* 2018;2(3): e36.

**INTRODUCTION**

Traumatic diaphragmatic hernia (TDH) is one of the serious complications following penetrating chest trauma that is occasionally diagnosed years after the primary event. TDH has been reported in about 10% of diaphragmatic injuries, but due to its silent nature, the diagnosis is frequently missed (1-3). The early diagnosis of a traumatic diaphragmatic injury is usually difficult. The rate of undiagnosed TDH was reported as 12-60%. It remains asymptomatic in almost 50% of the cases. Therefore, delayed presentation, days or even years after the primary traumatic event could be possible. Actually, most of them have been presented with a secondary complication such as anemia, bleeding, reflux, dyspnea, and ulcer or erosion formation (4, 5). Here we report a case of delayed TDH presenting with upper gastrointestinal bleeding (GIB) as an excuse to discuss this issue.

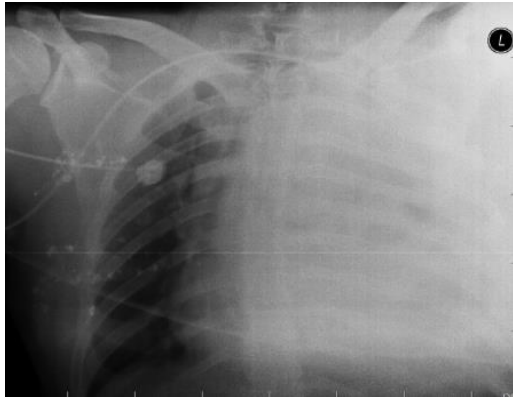
**CASE PRESENTATION**

The patient was a 35-year-old man admitted to the emergency department (ED) with chief complaint of abdominal pain after having an outdoor dinner 3 days before. The pain had

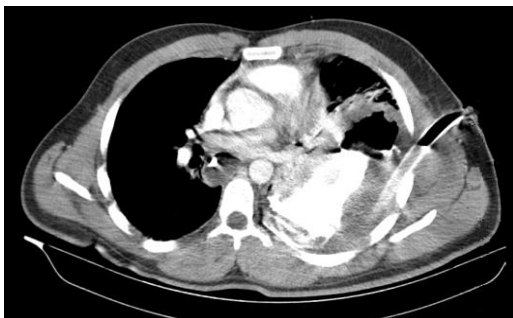suddenly manifested in the epigastric area with a steady nature and propagation to the back. The pain got worse with motion and coughing. Concomitant symptoms were nausea and bilious vomiting. He had no defecation apart from gas passing since 2 days before with no evidence of melena or hematemesis. The patient had been admitted to another hospital 2 days before and was candidate for performing endoscopy, but he left that hospital against medical advice. He had a history of stab wound 4 months ago. He did not use drugs or alcohol.

His was ill and tachypneic on admission and the vital signs were as follow: blood pressure (BP)=110/70 mmHg, pulse rate (PR)=137/min, respiratory rate (RR)=26/min, O<sub>2</sub>saturation (O<sub>2</sub>sat) = 98% (room air), oral temperature (OT)=36.5°C. On physical examination, the epigastric area was tender in palpation and revealed voluntary guarding, but no distention. There was a scar of the previous injury on his chest wall, left hemithorax, posterior axillary line, between 8th and 9th ribs. No other abnormal findings were found.

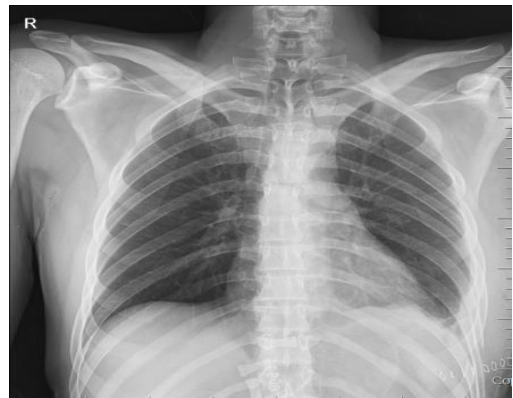He was hydrated with 1-liter of 9% normal saline



**Figure 1:** Primary portable anteroposterior CXR of the patient before surgery



**Figure 2:** Axial cut of patient's thoracic chest computed tomography with contrast



**Figure 3:** Posteroanterior CXR of the patients after surgery

(NS). A nasogastric tube (NGT) was inserted and fixed that resulted in drainage of about 500cc dark blood. He was sent to cardiopulmonary resuscitation (CPR) room and following cardiac monitoring and continuous pulse oximetry, foley catheter and central venous line (CV-line) were inserted. Blood and fresh frozen plasma (FFP) were prepared and pantoprazole infusion was started. He was candidate for emergent endoscopy for upper GIB. About 3 hours after admission, he had received 3liters of NS 0/9% and had about 2 liters of blood output via NGT. Thereafter

BP=120/80 mmHg, his PR rose to 150/min. During resuscitation measures, he suddenly developed respiratory distress and O<sub>2</sub>sat dropped to 76% in spite of O<sub>2</sub> administration with mask reservoir. The patient's respiratory distress could not be justified by upper GIB alone, therefore bedside ultrasonography was done by an emergency medicine professor and some soft tissue without peristaltic motions was seen and lung tissue did not seem normal in the left side. He got intubated and immediately a portable chest x-ray (CXR) was done, the result of which showed a white-lung on the left side (figure 1).

Pleural tap was performed, which was grossly bloody. After improvising chest tube, about 700cc bloody fluid was drained. His O<sub>2</sub>sat raised and reached 89%. He was sent to thoracic and abdominal spiral computed tomography (CT) scan with contrast, which showed the stomach in the left hemithorax (figure 2).

With diagnosis of stomach strangulation and diaphragmatic herniation of gastro thorax, the patient underwent emergent surgery and the diaphragmatic defect was restored and total gastrectomy plusesophagojejunostomy and jejunostomy were done. Pathology reported gastric tissue's full thickness necrosis. Figure 3 shows the patient's CXR the day after surgery. The patient was discharged after 2 days with follow up recommendation.

## DISCUSSION

Thoraco-abdominal penetrating wounds are known as common causes of diaphragmatic injuries. These injuries are of smaller size compare with those induced from blunt trauma, however they may develop into larger injuries if left untreated. Such lesions could lead to a diaphragmatic hernia with a potential risk of complications such as strangulation that could lead to higher mortality (6). The significant part of complications happens 1-4 years after the primary damage. The progression of the diaphragmatic lesion would be expected into three phases: a) Acute phase that mediastinum compression cause respiratory difficulty; b) Latent phase that presented with non-specific respiratory or gastrointestinal symptoms; c) Late phase that abdominal viscera herniation happened and may accompanied with obstruction or incarceration (7). It is likely that increasing the abdominal pressure, respiratory movements and intrapleural negative pressure could precipitate the herniation process. These events may result in incarceration, strangulation, gangrene and perforation. Mortality

rate is very high when undergoing emergency repair for treating this condition and is estimated to be about 32%. Having these important notes in mind lead to proper physician clinical judgment considering diaphragmatic lesion after a thoraco-abdominal penetrating injury (8, 9).

The plain CXR is diagnostic in about 73% of patients, and is commonly considered as the initial diagnostic imaging test. Intrathoracic visceral herniation, hemi-diaphragm elevation, diaphragmatic margin distortion and contralateral mediastinal shift are among the signs of diaphragmatic hernia on CXR (10).

Ultrasonography can also be diagnostic in this regard. It allows detecting the absence of diaphragmatic movements, herniation of viscera or flaps of ruptured diaphragm (11). CT scan is also an accurate test to detect diaphragmatic injuries in such patients. Helical CT shows enhanced specificity and sensitivity for diagnosis of TDH, almost reaching 100%, and could be considered as a proper option in hemodynamically stable patients (12). In spite of all mentioned, laparoscopy is the gold standard modality for diaphragmatic examinations in patients with penetrating chest trauma (13). Thoracentesis for diagnosis should be avoided due to the risk of any fistula being present between the alimentary tract and the pleural space. The surgical repair is the treatment of choice and regularly, laparotomy is considered when associated intra-abdominal complications are suspected (14, 15). General surgeons carry out laparotomy in about 92% of the patients and thoracic surgeons perform thoracotomy in almost 78% of them. Mortality rate of early presented TDH is about 3%, and it is 25% in those with

delayed presentations. The presence of gangrenous or perforated abdominal visceral in the chest cavity is commonly accompanied with higher mortality rate (16).

To the best of our knowledge, although there are some cases of congenital TDH presented with GIB, this is one of the rare cases of delayed presentation of missed diaphragmatic violation via perforating chest trauma that resulted in TDH and presented with GIB and respiratory distress.

#### CONCLUSIONS

Small diaphragmatic lesions, which usually result from stab wounds, may develop into larger injuries if left untreated and they might lead to a diaphragmatic hernia with a potential risk of early or late complications and mortality. One of the rare complications is GIB, which should be considered in a patient with past history of trauma and presentation of GIB.

#### ACKNOWLEDGMENTS

We express our thanks to the ED staff who were involved in management of this case.

#### AUTHORS' CONTRIBUTION

All authors passed four criteria for authorship contribution based on the recommendations of the International Committee of Medical Journal Editors.

#### CONFLICTS OF INTEREST

None declared.

#### FUNDING

None declared.

#### REFERENCES

1. Lu J, Wang B, Che X, Li X, Qiu G, He S, et al. Delayed traumatic diaphragmatic hernia: A case-series report and literature review. *Medicine*. 2016;95(32):e4362.
2. Stawicki SP, Lindsey DE. Missed traumatic injuries: a synopsis. *Int J Acad Med*. 2017;3(3):13-23.
3. Lim B, Teo L, Chiu M, Asinas-Tan M, Seow E. Traumatic diaphragmatic injuries: a retrospective review of the 12-year experience at a tertiary trauma centre. *Singapore Med J*. 2016;58(10):595-600.
4. Patlas MN, Leung VA, Romano L, Gagliardi N, Ponticiello G, Scaglione M. Diaphragmatic injuries: why do we struggle to detect them? *Radiol Med*. 2015;120(1):12-20.
5. Kapadia S, Jagroop S, Kumar A. Cameron ulcers: An atypical source for a massive upper gastrointestinal bleed. *World J Gastroenterol*. 2012;18(35):4959-61.
6. Ganie FA, Lone H, Lone GN, Wani ML, Ganie SA, Wani N-u-d, et al. Delayed Presentation of Traumatic Diaphragmatic Hernia: a Diagnosis of Suspicion with Increased Morbidity and Mortality. *Trauma Mon*. 2013;18(1):12-6.
7. Shreck G, Toalson T. Delayed presentation of traumatic rupture of the diaphragm. *J Okla State Med Assoc*. 2003;96(4):181-3.

8. Rafael AA, Rodrigues P, do Carmo L, Nascimento C, Machado J, da Fonseca JR. Late traumatic diaphragmatic hernia complicated by intrathoracic perforation and haemorrhagic gastric cyst: a rare combination. *Acta Med Port.* 2005;18(4):295-301 (abstract).
9. Khan M, Verma G. Traumatic diaphragmatic hernia presenting as a tension fecopneumothorax. *Hernia.* 2011;15(1):97-9.
10. Shanmuganathan K, Matsumoto J. Imaging of penetrating chest trauma. *Radiol Clin North Am.* 2006;44(2):225-38.
11. Blaivas M, Brannam L, Hawkins M, Lyon M, Sriram K. Bedside emergency ultrasonographic diagnosis of diaphragmatic rupture in blunt abdominal trauma. *Am J Emerg Med.* 2004;22(7):601-4.
12. Yucel M, Bas G, Kulali F, Unal E, Ozpek A, Basak F, et al. Evaluation of diaphragm in penetrating left thoracoabdominal stab injuries: The role of multislice computed tomography. *Injury.* 2015;46(9):1734-7.
13. Leung VA, Patlas MN, Reid S, Coates A, Nicolaou S. Imaging of Traumatic Diaphragmatic Rupture: Evaluation of Diagnostic Accuracy at a Level 1 Trauma Centre. *Can Assoc Radiol J.* 2015;66(4):310-7.
14. Baldassarre E, Valenti G, Gambino M, Arturi A, Torino G, Porta IP, et al. The role of laparoscopy in the diagnosis and the treatment of missed diaphragmatic hernia after penetrating trauma. *J Laparoendosc Adv Surg Tech A.* 2007;17(3):302-6.
15. Matz A, Alis M, Charuzi I, Kyzer S. The role of laparoscopy in the diagnosis and treatment of missed diaphragmatic rupture. *Surg Endosc.* 2000;14(6):537-9.
16. Haciibrahimoglu G, Solak O, Olcmen A, Bedirhan MA, Solmazer N, Gurses A. Management of traumatic diaphragmatic rupture. *Surg Today.* 2004;34(2):111-4.