

# Hip Joint Venting Decreases the Traction Force Required to Access the Central Compartment During Hip Arthroscopy



Alexander J. Mortensen, M.D., Allan K. Metz, B.S., Joseph Featherall, M.D.,  
Dillon C. O'Neill, M.D., Reece M. Rosenthal, B.S., and Stephen K. Aoki, M.D.

**Purpose:** To investigate the effect of hip joint venting on the magnitude of traction force required to arthroscopically access the central compartment of the hip. **Methods:** Patients who underwent hip arthroscopy for femoroacetabular impingement syndrome prospectively underwent an intraoperative traction protocol. Joint space was measured on fluoroscopic images obtained at 50 and 100 lbs of axial traction in the prevented and vented state, and joint space values were normalized to millimetric values using preoperative anteroposterior pelvis radiographs. Venting was performed by inserting a large gauge spinal needle into the hip joint through the hip capsule and removing the stylet. Joint space differences were compared with paired *t*-tests, Wilcoxon signed-rank tests, and McNemar tests. **Results:** Fifty hips in 46 patients were included. Mean joint space before venting was  $7.4 \pm 2.6$  mm and  $13.3 \pm 2.8$  mm at 50 and 100 lbs of traction, respectively. Mean joint space after venting was  $13.9 \pm 2.3$  mm and  $15.5 \pm 2.4$  mm at 50 and 100 lbs of traction, respectively. Mean differences in joint space at 50 and 100 lbs were 6.5 mm ( $P < .001$ ) and 2.2 mm ( $P < .001$ ), respectively. Mean joint space at 50 lbs in the vented state was significantly greater than in the pre-vented state at 100 lbs (13.9 mm vs. 13.3 mm;  $P = .002$ ). The increase in joint space between 50 and 100 lbs of traction was significantly greater in the prevented state than in the vented state (5.9 mm vs 1.6 mm;  $P = .021$ ). **Conclusions:** Venting the hip reduces the traction force necessary to arthroscopically visualize and instrument the central compartment of the hip by at least 50%. Further, residual negative pressurization of the hip joint remains after breaking the labral suction seal and venting effectively eliminates this phenomenon to aid in hip joint distraction at lower traction force. **Level of Evidence:** Level IV, case series.

Hip joint distraction is critical to visualizing and performing arthroscopic hip procedures. Sufficient traction force to provide adequate distraction for safe and effective central compartment instrumentation should be balanced with the risk of iatrogenic traction-related nerve and soft-tissue injuries. Traction-related injuries during hip arthroscopy are significantly

influenced by patient positioning and type of distraction table used and most commonly present as a neuropraxia affecting the pudendal, sciatic, lateral femoral cutaneous, or superficial peroneal nerves.<sup>1-7</sup> Previous studies have shown both the duration and magnitude of traction are related to the incidence of traction-related nerve injury.<sup>3,8,9</sup> Furthermore, some studies suggest the magnitude of traction on the development of traction-related neuropraxias is more important than the duration of traction application.<sup>5,10</sup>

Previous research has demonstrated venting increases the distractibility of the hip, which is most commonly attributed to the effect venting has on breaking the labral suction seal.<sup>11,12</sup> The labral suction seal of the central compartment of the hip is a well-described phenomenon created by the labrum, articular congruity, and synovial fluid to stabilize the hip joint.<sup>1,13-15</sup> The labral suction seal has been shown to provide the greatest resistance to distraction in the initial 1 to 3 mm of distraction<sup>2,13,15</sup>; thus, the observed effect venting has on distraction past this threshold (>3 mm) is likely

From the Department of Orthopaedics, University of Utah, Salt Lake City, Utah, U.S.A.

The authors report the following potential conflicts of interest or sources of funding: S.K.A. reports personal fees from Stryker, outside the submitted work. Full ICMJE author disclosure forms are available for this article online, as [supplementary material](#).

Received September 1, 2022; accepted February 19, 2023.

Address correspondence to Stephen K. Aoki, M.D., Department of Orthopaedics, 590 Wakara Way, Salt Lake City, UT 84108. E-mail: [Stephen.aoki@hsc.utah.edu](mailto:Stephen.aoki@hsc.utah.edu)

© 2023 THE AUTHORS. Published by Elsevier Inc. on behalf of the Arthroscopy Association of North America. This is an open access article under the CC BY-NC-ND license (<http://creativecommons.org/licenses/by-nc-nd/4.0/>).  
2666-061X/221148

<https://doi.org/10.1016/j.asmr.2023.02.011>

the result of its effect on the intracapsular mechanics of the hip. Furthermore, cadaveric research has shown hip venting results in an inverse exponential relationship between distraction and traction, allowing for greater distraction to be obtained at lower traction forces.<sup>11</sup> Less is known regarding residual negative pressurization within the hip joint capsule after the labral suction seal has been broken and how it may influence hip joint distractibility.<sup>16-18</sup>

The purpose of this study was to investigate the effect of hip joint venting on the magnitude of traction force required to arthroscopically access the central compartment of the hip. We hypothesized venting the hip would increase the overall hip distraction distance relative to an unvented state and provide increased distraction at lower traction intervals.

## Methods

Following institutional review board approval (institutional review board #71733), patients undergoing primary hip arthroscopy for femoroacetabular impingement (FAI) syndrome by the senior author (S.K.A.) between July 8, 2021, and December 17, 2021, prospectively underwent an intraoperative traction protocol. Inclusion criteria were (1) primary hip arthroscopy, and (2) diagnosis of FAI syndrome. Exclusion criteria were (1) patients whose hips did not break the labral suction seal effect at 100 lbs of traction without venting, and (2) patients who did not have complete traction protocol data. Demographic data was obtained through chart review. Alpha angle, sourcil and bone edge LCEA values,<sup>19</sup> and acetabular index were measured on preoperative radiographs.

After general anesthesia induction, patients were placed in the supine position and positioned in 0-15° of Trendelenburg with the hip in neutral position compared with the patient's torso (0° abduction/adduction, 0° flexion/extension, neutral rotation) on a post-free distraction table (Guardian Hip Distraction System; Stryker, Kalamazoo, MI). Axial traction was applied to the operative hip using traction controls on the distraction table. Traction force was measured using the built-in tensiometer on the distraction table. Before

gathering traction data on the first patient in our series, the tensiometer accuracy was validated through a process in which we suspended free weights perpendicular to the floor at 25, 50, 75, and 100 lbs, and ensured the tensiometer readings were accurate to the applied weights. All cases used the same model of fluoroscopy machine (OEC 9900 Elite Mobile C-Arm, GE Healthcare, Chicago, IL) with standard image intensifier and identical magnification and collimation settings to minimize the parallax phenomenon. Before instrumentation of the operative hip, fluoroscopic images were obtained at axial traction intervals of 0, 50, and 100 lbs for the native, unvented state, followed by removal of hip traction. The operative hip was fully prepped and draped followed by reapplication of 100 lbs of axial distraction force. Venting was then immediately performed by inserting a large gauge spinal needle into the joint and removing the stylet. Traction was then reduced to 50 lbs and another fluoroscopic image was obtained in the vented state. Traction was then increased to 100 lbs and a final fluoroscopic image was obtained in the vented state (Fig 1). Each fluoroscopic image was obtained immediately after achieving the traction intervals in both the unvented and vented states.

Imaging measurements were made by a single author (A.K.M.) on fluoroscopic and preoperative anteroposterior (AP) radiographs in a picture archiving and communication system. Normalization of fluoroscopic images to preoperative AP radiographs was performed to convert fluoroscopic measurements to millimetric values using previously published methodology,<sup>12,20,21</sup> as follows: femoral head diameter on the preoperative AP radiograph and every fluoroscopic image was measured using the diameter of a best fit circle. Total lateral joint space was defined as the shortest distance between the lateral edge of the acetabular sourcil and the superolateral aspect of the femoral head (Fig 2) and was measured on all fluoroscopic images in both the unvented and vented states. Units of measurement were millimeters for all radiographs and pixels for all fluoroscopic images. Total joint space was then normalized to millimetric values using Equation 1:

---

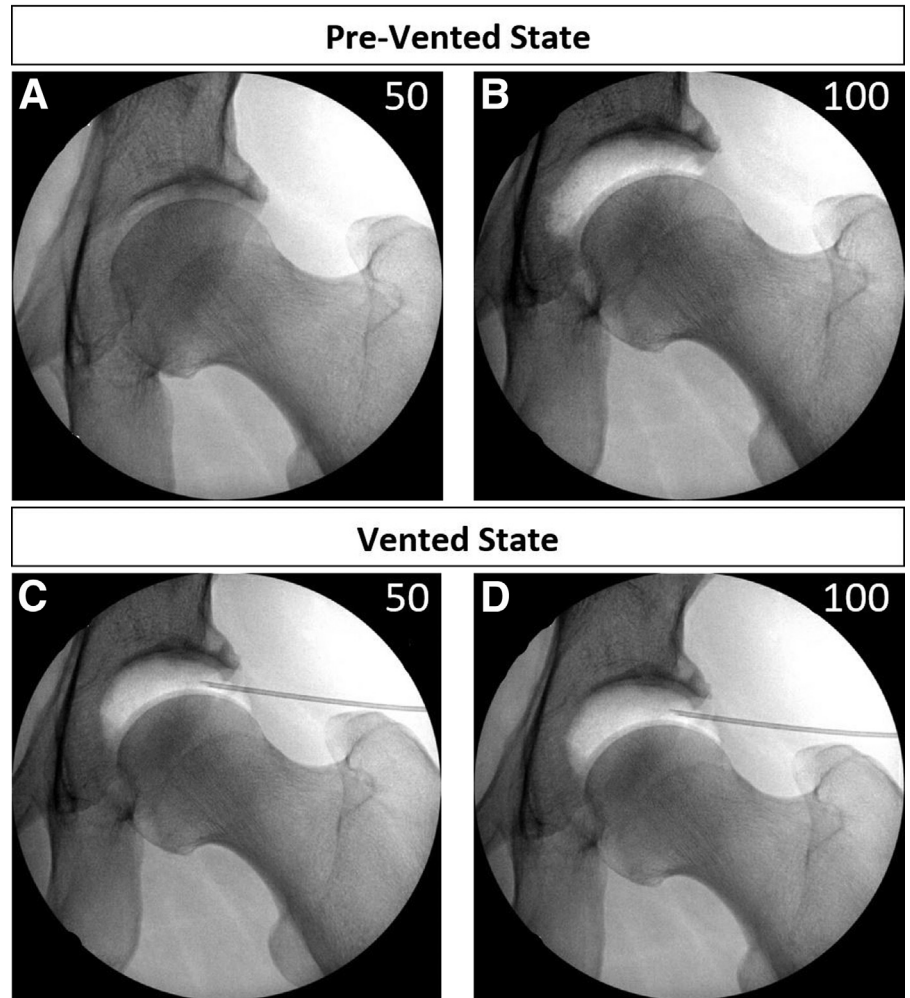

$$\frac{\text{Joint Space, XR (mm)}}{\text{Femoral Head Diameter, XR (mm)}} = \frac{\text{Joint Space, Fluro (pixels)}}{\text{Femoral Head Diameter, Fluro (pixels)}}$$


---

---


$$\text{Joint Space, XR (mm)} = \text{Femoral Head Diameter, XR (mm)} \times \frac{\text{Joint Space, Fluro (pixels)}}{\text{Femoral Head Diameter, Fluro (pixels)}}$$


---



**Fig 1.** Fluoroscopic images of a left hip obtained at 50 and 100 lbs of axial traction in both prevented and vented states demonstrating substantially greater distraction in the vented state relative to the prevented state. (A) Prevented at 50 lbs. (B) Prevented at 100 lbs. (C) Vented at 50 lbs. (D) Vented at 100 lbs.

### Statistical Analysis

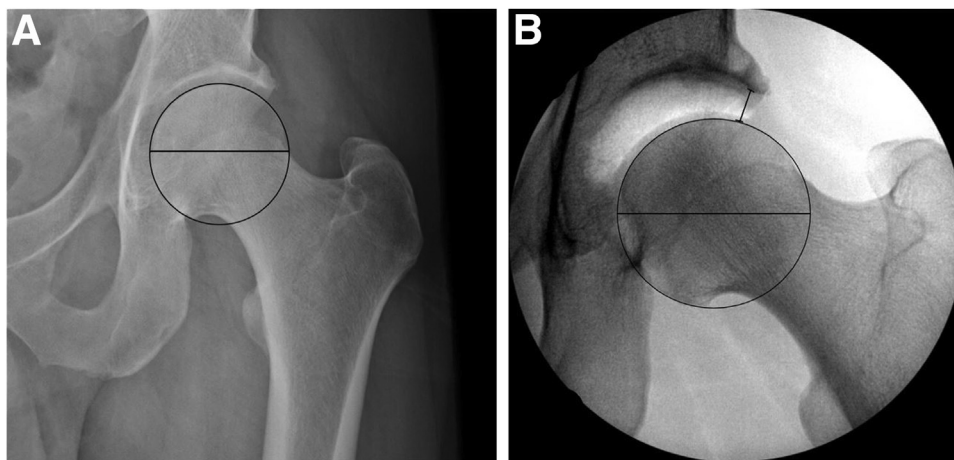
All statistical analysis was performed using Excel, version 2111 (Microsoft, Redmond, WA) and SPSS version 27 (IBM Corp., Armonk, NY). Descriptive statistics were calculated. The Kolmogorov–Smirnov test was used to assess for normality of continuous variables. Normally distributed continuous variables were compared using paired *t*-tests, whereas non-normally distributed continuous variables were compared using Wilcoxon signed rank tests. McNemar tests were used to compare categorical variables.

### Results

Sixty-five hips in 57 patients underwent primary hip arthroscopy with the senior author during the study period. Four hips were excluded because they did not have complete traction protocol data. Eleven hips were excluded because they did not break the labral suction seal at 100 lbs of axial distraction. Thus, 50 hips in 46 patients were included.

Cohort characteristics are presented in [Table 1](#). Mean age at the time of surgery was  $31.2 \pm 11.9$  years. Thirty-two (64%) patients were female. Mean weight, height, and body mass index were  $73.5 \pm 20.5$  kg,  $169.9 \pm 11.5$  cm, and  $25.2 \pm 5.9$ , respectively. Mean sourcil and bone edge LCEA values were  $31.1^\circ \pm 6.5^\circ$  and  $35.3^\circ \pm 6.2^\circ$ , respectively. Mean acetabular index was  $5.7^\circ \pm 4.4^\circ$ . Mean alpha angle was  $58.8^\circ \pm 5.2^\circ$ . All hips were Tönnis grade 0 or 1.

Mean joint space before venting was  $7.4 \pm 2.6$  mm and  $13.3 \pm 2.8$  mm at 50 and 100 lbs of axial distraction, respectively. Mean joint space after venting was  $13.9 \pm 2.3$  mm and  $15.5 \pm 2.4$  mm at 50 and 100 lbs of axial distraction, respectively. Joint space was significantly greater in vented hips than in prevented hips at 50 and 100 lbs with mean differences of 6.5 mm ( $P < .001$ ) and 2.2 mm ( $P < .001$ ), respectively. Mean joint space at 50 lbs in the vented state was significantly greater than in the prevented state at 100 lbs (13.9 mm vs 13.3 mm;  $P = .002$ ). The increase in joint space



**Fig 2.** Joint space was measured at the lateral edge of the sourcil on fluoroscopic images of a left hip and converted to millimetric values using the femoral head diameter measured on both preoperative AP radiographs and intraoperative AP fluoroscopic images, according to Equation 1. (A) Preoperative AP radiograph and (B) intraoperative AP fluoroscopic image with the diameter of the best-fit circles measured and overlying the femoral head. (AP, anteroposterior.)

between 50 and 100 lbs of traction was significantly greater in the prevented state than in the vented state (5.9 mm vs 1.6 mm;  $P = .021$ ). Prevented and vented hips at 50 lbs of traction achieved 56% and 106% of the mean joint space obtained at 100 lbs in the prevented state, respectively ( $P \leq .001$ ; Table 2; Fig 3).

At 50 lbs, 9 (18%) hips in the prevented state and 48 (96%) of hips in the vented state achieved  $>10$  mm of joint space ( $P < .001$ ). Further, 45 (90%) hips in the prevented state at 100 lbs achieved  $>10$  mm of joint space, which was less than the 96% rate at which vented hips at 50 lbs achieved  $>10$  mm of joint space ( $P = .250$ ) (Fig 4). Joint space in 36 (72%) hips in the vented state at 50 lbs was greater than joint space at 100 lbs in the pre-vented state. Joint space in all 50 (100%)

hips in the vented state at 100 lbs was greater than joint space at 100 lbs in the prevented state.

## Discussion

The most important finding of this study was that venting the hip reduces the traction force necessary to arthroscopically visualize and instrument the central compartment of the hip by at least 50%. Further, the difference in joint space between 50 and 100 lbs was significantly greater in the prevented state compared with the vented state, suggesting venting aids in achieving sufficient distraction without the need to apply additional, unnecessary traction through the nerves and soft tissues of the operative lower extremity. In addition, the study findings support the concept that residual negative intracapsular pressurization of the hip joint exists after breaking the labral suction seal, and venting the hip effectively eliminates this phenomenon to aid in hip joint distraction at lower traction intervals.

Previous research on venting the hip joint has focused primarily on the effect venting has on disrupting the labral suction seal of the central compartment.<sup>11,12</sup> The labral suction seal has been shown to be the primary restraint to distraction throughout the first 1 to 3 mm of hip distraction.<sup>2,13,15</sup> Therefore, beyond the labral suction seal effect, any additional distraction afforded with venting is caused by the effect venting has on the residual intracapsular pressurization created by axial distraction, the hip vacuum effect. In the cadaveric study by Dienst et al,<sup>11</sup> a spinal needle was inserted into the hip central compartment to facilitate passive, unobstructed airflow between the central compartment and atmosphere. Their method effectively disrupted the pressurization effect of the suction seal and provided increased distraction compared to traction without venting. The present study is similar in that venting the joint was accomplished passively without injecting air to disrupt negative pressurization, demonstrating the

**Table 1.** Basic Demographic and Morphologic Characteristics of the Cohort

|                     | Mean ( $\pm$ SD)    | Count (%) |
|---------------------|---------------------|-----------|
| Age at surgery, y   | 31.2 ( $\pm$ 11.9)  |           |
| Sex                 |                     |           |
| Female              |                     | 32 (64%)  |
| Male                |                     | 18 (36%)  |
| Weight, kg          | 73.5 ( $\pm$ 20.5)  |           |
| Height, cm          | 169.9 ( $\pm$ 11.5) |           |
| BMI                 | 25.2 ( $\pm$ 5.9)   |           |
| Beighton score*     |                     |           |
| $\leq 4$            |                     | 25 (100%) |
| $> 4$               |                     | 0         |
| Laterality          |                     |           |
| Left                |                     | 21 (42%)  |
| Right               |                     | 29 (58%)  |
| LCEA - sourcil      | 31.1° ( $\pm$ 6.5°) |           |
| LCEA - bone edge    | 35.3° ( $\pm$ 6.2°) |           |
| Acetabular index    | 5.7° ( $\pm$ 4.4°)  |           |
| Alpha angle         | 58.8° ( $\pm$ 5.2°) |           |
| Tönnis grade 0 or 1 |                     | 50 (100%) |

BMI, body mass index; LCEA, lateral center-edge angle; SD, standard deviation.

\*Beighton score not recorded and thus unavailable for 25 patients.

**Table 2.** Joint Space Obtained at 50 and 100 lbs of Axial Traction Compared Between the Prevented and Vented States

|                                                     | Prevented,<br>Mean $\pm$ SD | Vented,<br>Mean $\pm$ SD | P Value |
|-----------------------------------------------------|-----------------------------|--------------------------|---------|
| Joint space, mm, 50 lbs                             | 7.4 $\pm$ 2.6               | 13.9 $\pm$ 2.3           | <.001*  |
| Joint space, mm, 100 lbs                            | 13.3 $\pm$ 2.8              | 15.5 $\pm$ 2.4           | <.001*  |
| Increase in joint space, mm, Between 50 and 100 lbs | 5.9 $\pm$ 2.2               | 1.6 $\pm$ 0.8            | <.021*  |
| Percentage of unvented joint space at 100 lbs       |                             |                          |         |
| 50 lbs                                              | 56 $\pm$ 15%                | 106 $\pm$ 18%            | <.001*  |
| 100 lbs                                             | $\pm$                       | 119 $\pm$ 20%            | —       |

SD, standard deviation.

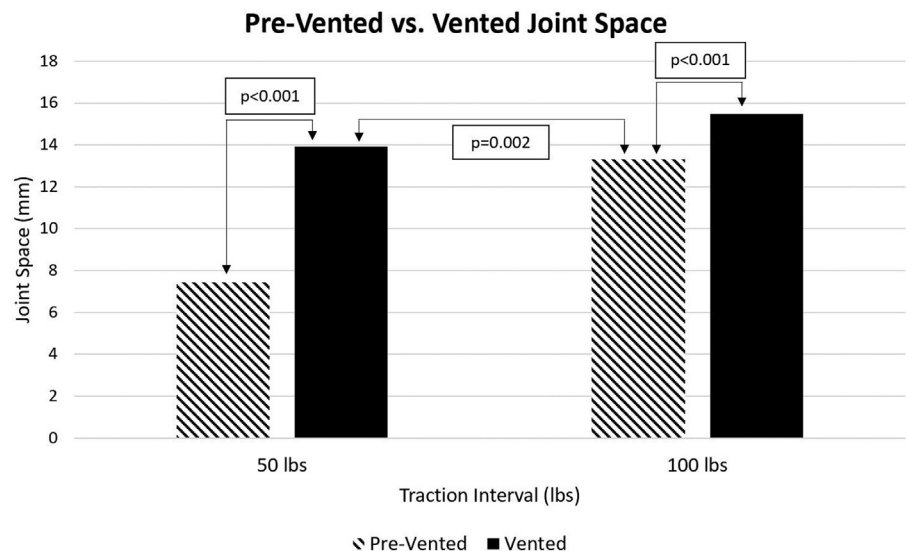
\*Significant P-value,  $\alpha < 0.05$ .

isolated effect of venting on residual negative intracapsular pressurization after the labral suction seal is broken.

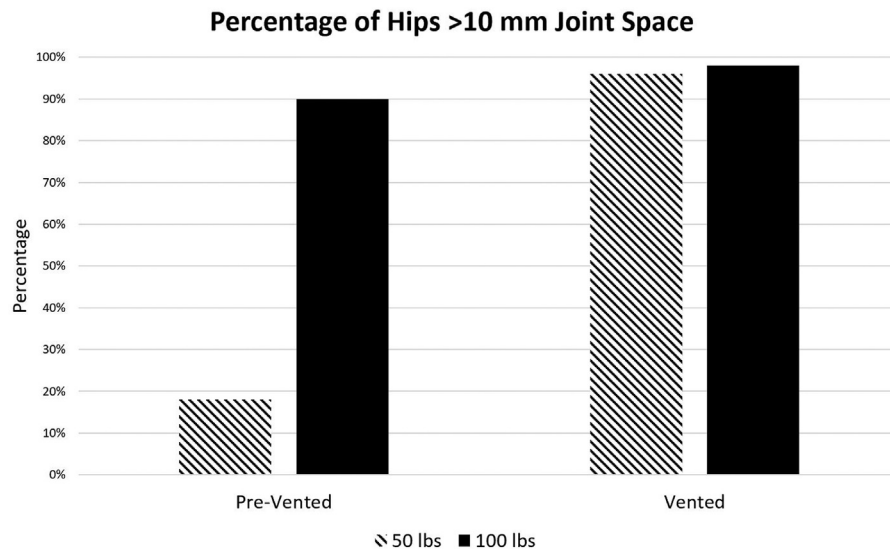
An in vivo study by O'Neill et al<sup>12</sup> demonstrated venting the hip joint with injection of 20 mL of air intracapsularly before applying axial traction resulted in significantly greater distraction distance compared with the prevented state at 25 lb traction force intervals, up to 100 lbs. Thus, demonstrating venting the hip joint before the application of traction effectively disrupted the negative pressurization of the hip joint to improve the distractibility of the hip. The findings of the current study also support the effect of venting on the overall distractibility of the hip. In combination, the findings of O'Neill et al<sup>12</sup> and the present study provide support to the effects that venting has on both breaking the labral suction seal and relieving any residual hip joint intracapsular negative pressurization to afford maximal distraction at significantly lower traction force. Clinically, these data can be used to decrease the maximum distraction force exerted on the lower extremity by

either (1) venting before the application of traction for disruption of the labral suction seal and the negative intracapsular pressurization generated with axial distraction, or (2) inserting a spinal needle after obtaining adequate hip distraction to release the intracapsular pressure and then subsequently manually reducing the traction force on the lower extremity before instrumentation of the hip. Both minimize overall traction force while maintaining adequate joint distraction distance during instrumentation and central compartment procedures.

In an in vivo study by Ellenrieder et al<sup>18</sup> in which they distracted hip joints to approximately 10 mm then penetrated the hip capsule to disrupt the vacuum effect, they found this caused a mean decrease in traction by 17%. In another in vivo study by Rölting et al<sup>17</sup> in which they also distracted hip joints to approximately 10 mm then relieved the suction seal effect with insertion of a spinal needle, they found the median traction force decreased by 27%. In contrast to these studies, the present study evaluated distraction at fixed



**Fig 3.** Bar chart displaying the comparison of prevented versus vented joint space obtained at 50 and 100 lbs of axial traction. Notably, mean joint space at 50 lbs in the vented state was significantly greater than in the prevented state at 100 lbs (13.9 mm vs 13.3 mm;  $P = .002$ ).



**Fig 4.** Bar chart displaying the percentage of hips that achieved >10 mm of distraction in the prevented and vented states at 50 and 100 lbs of axial traction.

traction force intervals, and by doing so was able to quantify the effect venting has on overall distraction. Interestingly, joint space at 50 lbs of traction in the vented state was significantly greater than joint space at 100 lbs of traction in the prevented state. Further, the mean increase in distraction between 50 and 100 lbs was only 1.6 mm in the vented state, which was significantly less than the mean increase in distraction of 5.9 mm in the prevented state. These results are consistent with the findings of the aforementioned study by Dienst et al<sup>11</sup> in which they describe the inverse exponential (logarithmic) shape of the “distraction plus distension” curve, which demonstrates increasingly smaller amounts of distraction are achieved with increasing traction forces. In other words, venting allows for the ability to obtain the maximal amount of distraction afforded by the restraints of the surrounding soft tissues at much lower traction force than is needed without venting.

Similar to the effect of intracapsular cannulization with a spinal needle, the act of establishing intracapsular portals and creating a capsulotomy has a similar effect on equilibrating the intracapsular pressure to that of the atmosphere. Furthermore, previous work has demonstrated that disruption to the ligamentous fibers of the hip capsule serves to further reduce mechanical restraint to distraction.<sup>6,18,20,22</sup> Therefore, even if hip venting is not used before establishing capsular portals and performing a capsulotomy, we recommend reassessing and potentially reducing the amount of traction needed to complete central compartment procedures.

Ten millimeters of distraction is commonly cited as the distraction distance necessary to adequately access

the central compartment of the hip joint arthroscopically. In the present study at 50 lbs of applied traction, joint space was >10 mm in only 18% of hips in the prevented state, whereas joint space was >10 mm in 96% of hips in the vented state. These findings suggest the absolute joint space provided by 50 lbs after venting may be sufficient in the majority of patients with cam-type FAI syndrome. Venting may be especially important in achieving distraction in patient populations that are more difficult to distract, including male patients and hips with early osteoarthritis.<sup>18,23</sup>

Traction-related complications are thought to be the result of a cumulative traction, a product of traction force magnitude and distraction time. Historically, hip arthroscopy literature has suggested traction time should be limited to less than two hours in order to minimize traction-related nerve injury,<sup>24</sup> which is consistent with tourniquet literature in which the mechanism of injury is a time-dependent ischemic event.<sup>25</sup> Interestingly, a study by Telleria et al<sup>5</sup> demonstrated the single greatest risk factor related to traction-related sciatic nerve dysfunction was the amount of traction applied. In their study, the effect of traction on nerve events was studied in patients undergoing hip arthroscopy in the lateral decubitus position. Mean traction was greater in the nerve dysfunction group (84 lbs) compared with the group without nerve dysfunction (73 lbs). Further, they found the odds of a traction-related nerve event increased by 4% with every 1-lb increase in traction. Their results and the findings of the present study highlight the significant role reducing traction force may have on traction-related injury, and the importance of recognizing that traction can be reduced after releasing the

intracapsular vacuum effect through venting or capsular manipulation to decrease tension on lower extremity nerves and soft-tissue structures.

### Limitations

There are several limitations to this study. First, myotendinous relaxation may occur after application of 100 lbs in the prevented state before obtaining the joint space measurements of the vented state and may contribute to increased joint space values in the vented state; however, the process of obtaining fluoroscopic images was brief in each case (<1 minute). Second, the timing of venting in this study occurred at 100 lbs of traction, followed by reduction of traction to 50 lbs and obtaining distraction in the vented state at 50 and 100 lbs. The traction force at which venting occurs may influence hip joint distraction, and this effect was not studied in the present study. Third, 4 hips in 4 patients were excluded during the study period because of a lack of obtaining full traction protocol fluoroscopy images. Fourth, the joint space measurements were made on 2-dimensional fluoroscopic images and normalized to millimetric values using preoperative radiographs. There is likely a small amount of magnification effect which leads to slight over estimation of true joint space values.

### Conclusions

Venting the hip reduces the traction force necessary to arthroscopically visualize and instrument the central compartment of the hip by at least 50%. Further, residual negative pressurization of the hip joint remains after breaking the labral suction seal and venting effectively eliminates this phenomenon to aid in hip joint distraction at lower traction force.

### References

1. Ferguson SJ, Bryant JT, Ganz R, Ito K. An in vitro investigation of the acetabular labral seal in hip joint mechanics. *J Biomech* 2003;36:171-178.
2. Suppauksorn S, Parvareh KC, Rasio J, Shewman EF, Nho SJ. The effect of rim preparation, labral augmentation, and labral reconstruction on the suction seal of the hip. *Arthroscopy* 2022;38:365-373.
3. Bailey TL, Stephens AR, Adeyemi TF, et al. Traction time, force and postoperative nerve block significantly influence the development and duration of neuropathy following hip arthroscopy. *Arthroscopy* 2019;35:2825-2831.
4. Mei-Dan O, Kraeutler MJ, Garabekyan T, Goodrich JA, Young DA. Hip distraction without a perineal post: A prospective study of 1000 hip arthroscopy cases. *Am J Sports Med* 2018;46:632-641.
5. Telleria JJM, Safran MR, Gardi JN, Harris AHS, Glick JM. Risk of sciatic nerve traction injury during hip arthroscopy—is it the amount or duration? An intraoperative nerve monitoring study. *J Bone Joint Surg Am* 2012;94:2025-2032.
6. Fagotti L, Kemler BR, Utsunomiya H, et al. Effects of capsular reconstruction with an iliotibial band allograft on distractive stability of the hip joint: A biomechanical study. *Am J Sports Med* 2018;46:3429-3436.
7. Frandsen L, Lund B, Grønbech Nielsen T, Lind M. Traction-related problems after hip arthroscopy. *J Hip Preserv Surg* 2017;4:54-59.
8. Shelton TJ, Patel A, Agatstein L, Haus BM. What neuro-monitoring changes can be expected during hip arthroscopy in the pediatric population? *Am J Sports Med* 2020;48:409-414.
9. Larson CM, Clohisy JC, Beaulé PE, et al. Intraoperative and early postoperative complications after hip arthroscopic surgery: A prospective multicenter trial utilizing a validated grading scheme. *Am J Sports Med* 2016;44:2292-2298.
10. Kern MJ, Murray RS, Sherman TI, Postma WF. Incidence of nerve injury after hip arthroscopy. *J Am Acad Orthop Surg* 2018;26:773-778.
11. Dienst M, Seil R, Göttsche S, et al. Effects of traction, distension, and joint position on distraction of the hip joint: An experimental study in cadavers. *Arthroscopy* 2002;18:865-871.
12. O'Neill DC, Mortensen AJ, Tomasevich KM, et al. Joint venting prior to hip distraction minimizes traction forces during hip arthroscopy. *Arthroscopy* 2021;37:2164-2170.
13. Nepple JJ, Philippon MJ, Campbell KJ, et al. The hip fluid seal—Part II: The effect of an acetabular labral tear, repair, resection, and reconstruction on hip stability to distraction. *Knee Surg Sports Traumatol Arthrosc* 2014;22:730-736.
14. Philippon MJ, Nepple JJ, Campbell KJ, et al. The hip fluid seal—Part I: The effect of an acetabular labral tear, repair, resection, and reconstruction on hip fluid pressurization. *Knee Surg Sports Traumatol Arthrosc* 2014;22:722-729.
15. Crawford MJ, Dy CJ, Alexander JW, et al. The 2007 Frank Stinchfield Award. The biomechanics of the hip labrum and the stability of the hip. *Clin Orthop Relat Res* 2007;465:16-22.
16. Byrd JWT, Chern KY. Traction versus distension for distraction of the joint during hip arthroscopy. *Arthroscopy* 1997;13:346-349.
17. Röling MA, Mathijssen NM, Blom I, Lagrand T, Minderman D, Bloem RM. Traction force for peroperative hip dislocation in hip arthroscopy. *Hip Int* 2019;30:333-338.
18. Ellenrieder M, Tischer T, Bader R, Kreuz PC, Mittelmeier W. Patient-specific factors influencing the traction forces in hip arthroscopy. *Arch Orthop Trauma Surg* 2017;137:81-87.
19. Hanson JA, Kapron AL, Swenson KM, Maak TG, Peters CL, Aoki SK. Discrepancies in measuring acetabular coverage: revisiting the anterior and lateral center edge angles. *J Hip Preserv Surg* 2015;2:280-286.
20. O'Neill DC, Tomasevich KM, Mortensen AJ, Featherall J, Ohlsen SM, Aoki SK. Capsular repair during hip arthroscopy demonstrates restoration of axial distraction resistance in an in vivo intraoperative testing model. *J Bone Joint Surg Am* 2021;103:1977-1985.

21. Tomasevich K, Ohlsen S, Dillon O, Featherall J, Aoki S, Mortensen A. Poster 193: Increased hip distractability in the revision hip arthroscopy setting: A comparison between revision and native contralateral hips with an intraoperative axial stress exam under anesthesia. *Orthop J Sports Med* 2022;10(7 suppl 5).
22. Khair MM, Grzybowski JS, Kuhns BD, Wuerz TH, Shewman E, Nho SJ. The effect of capsulotomy and capsular repair on hip distraction: A cadaveric investigation. *Arthroscopy* 2017;33:559-565.
23. Kapron AL, Karns MR, Aoki SK, et al. Patient-specific parameters associated with traction in primary and revision hip arthroscopic surgery. *Orthop J Sports Med* 2018;6(11).
24. O'Neill DC, Hadley ML, Adeyemi TF, Aoki SK, Maak TG. The effects of venting and capsulotomy on traction force and hip distraction in hip arthroscopy. *J Hip Preserv Surg* 2020;7:487-495.
25. Fitzgibbons PG, Di Giovanni C, Hares S, Akelman E. Safe tourniquet use: A review of the evidence. *J Am Acad Orthop Surg* 2012;20:310-319.