

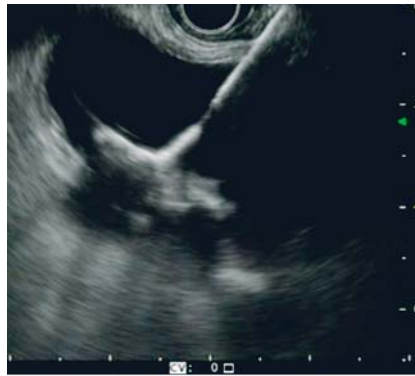Symptomatic cholelithiasis and acute cholecystitis treated by EUS-guided gallbladder drainage with gallbladder toilette



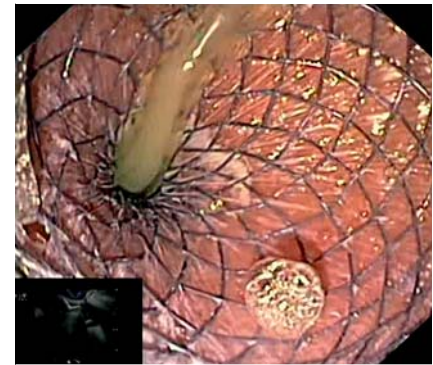
An 81-year-old woman with a history of colorectal cancer, connective tissue disease, previous dorsal spine stabilization, and late mild cognitive impairment was admitted to our emergency department with abdominal pain, fever, and jaundice. She had experienced recurrent upper right abdominal pain for the past 2 years and had been diagnosed with cholelithiasis. Laboratory findings showed leukocytosis, elevated C-reactive protein levels, elevated alkaline phosphatase, and hyperbilirubinemia. A computed tomography (CT) scan revealed gallbladder distention and wall thickening with pericholecystic fluid and a 25-mm gallstone impacted in the infundibulum.

Because of her age and comorbidities, the patient was at high risk for surgery. After joint discussion, we decided on an endoscopic ultrasound (EUS)-guided gallbladder drainage with placement of an electrocautery-enhanced lumen-apposing metal stent (EC-LAMS) (10×20-mm Hot-Spaxus; Taewoong Medical Co., Gimpo, Korea) [1,2]. The cholecystogastrostomy was successfully performed using the freehand technique and intrachannel release of the proximal flange (► Fig. 1, ► Fig. 2). The patient was discharged on the fifth day with antibiotic therapy after improvement of clinical and lab tests.

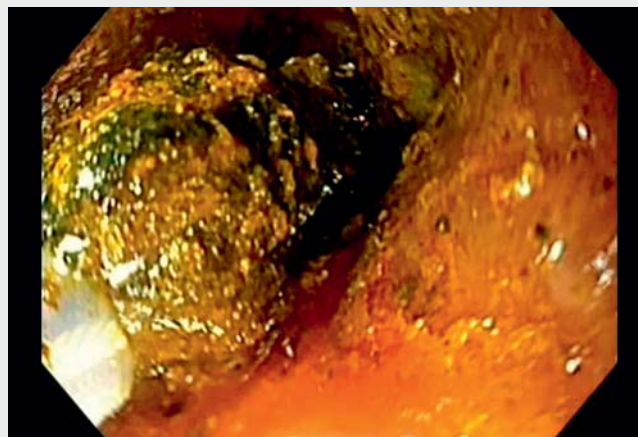
A per-oral cholecystoscopy was carried out 6 weeks later by inserting a standard gastroscope through the LAMS (► Video 1). The gallstone was detected obstructing the gallbladder neck. Mechanical lithotripsy using a basket was performed for stone fragmentation and retrieval (► Fig. 3). Once the gallbladder and the cystic duct insertion were clear from any residuals, the LAMS was removed with a rat-tooth forceps (► Fig. 4, ► Fig. 5). No complications related to the procedure were encountered. The patient resumed oral intake 1 day later and was discharged with no symptoms.



► **Fig. 1** Endosonographic image showing deployment of the distal flange of the lumen-apposing metal stent (LAMS) within the gallbladder lumen.



► **Fig. 2** Both endoscopic and endosonographic view of the LAMS proximal flange released in the gastric body.



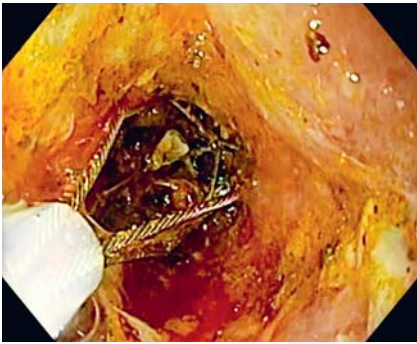
► **Video 1** Endoscopic ultrasound-guided cholecystogastrostomy and subsequent trans-gastric gallbladder stone toilette.

Advanced gallbladder endoscopic intervention is a promising option for relieving acute cholecystitis and removing gallstones in selected patients not suited for cholecystectomy or when a bridge to surgery is needed, with good technical and clinical success rates [1, 2].

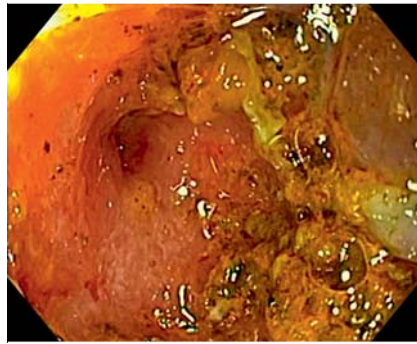
Endoscopy_UCTN_Code_TTT_1AS_2AD

Competing interests

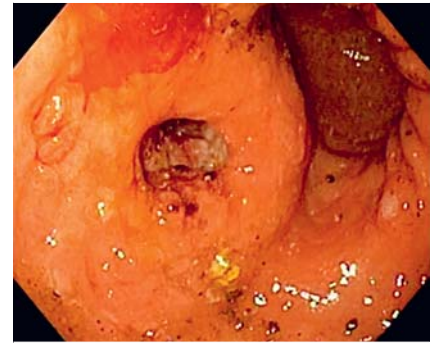
B. Mangiavillano is consultant for Taewoong.



► **Fig. 3** Mechanical lithotripsy performed using a Dormia basket through the LAMS.




► **Fig. 4** Gallbladder fundus and cystic duct insertion cleared after complete extraction of stones.



► **Fig. 5** Cholecystogastric fistula after LAMS removal at the end of the procedure.

The authors

Benedetto Mangiavillano¹  **Federica Calabrese**¹, **Francesco Auriemma**¹, **Danilo Paduano**¹, **Alessandro De Marco**², **Alessandro Repici**^{2,3}

- 1 Gastrointestinal Endoscopy Unit, Humanitas Mater Domini, Castellanza VA, Italy
- 2 Endoscopy Unit, Humanitas Clinical and Research Center – IRCCS, Rozzano MI, Italy
- 3 Humanitas University, Department of Biomedical Sciences, Pieve Emanuele, Milan, Italy

Corresponding author

Benedetto Mangiavillano, MD
Gastrointestinal Endoscopy Unit, Humanitas Mater Domini, Via Gerenzano 2, 21053 Castellanza VA, Italy
bennymangiavillano@gmail.com

References

- [1] Mangiavillano B, Auriemma F, Lamonaca L et al. A novel lumen-apposing metal stent with an electrocautery tip for different indications: initial experience in a referral center. *Dig Dis* 2022; 40: 526–529
- [2] Mangiavillano B, Moon JH, Crinò SF et al. Safety and efficacy of a novel electrocautery-enhanced lumen-apposing metal stent in interventional EUS procedures (with video). *Gastrointest Endosc* 2022; 95: 115–122

Bibliography

Endoscopy 2023; 55: E284–E285

DOI 10.1055/a-1974-8765

ISSN 0013-726X

published online 2.12.2022

© 2022. The Author(s).

This is an open access article published by Thieme under the terms of the Creative Commons Attribution-NonDerivative-NonCommercial License, permitting copying and reproduction so long as the original work is given appropriate credit. Contents may not be used for commercial purposes, or adapted, remixed, transformed or built upon. (<https://creativecommons.org/licenses/by-nc-nd/4.0/>)

Georg Thieme Verlag KG, Rüdigerstraße 14, 70469 Stuttgart, Germany



ENDOSCOPY E-VIDEOS

<https://eref.thieme.de/e-videos>



Endoscopy E-Videos is an open access online section, reporting on interesting cases and new techniques in gastroenterological endoscopy. All papers include a high quality video and all contributions are freely accessible online. Processing charges apply (currently EUR 375), discounts and waivers acc. to HINARI are available.

This section has its own submission website at <https://mc.manuscriptcentral.com/e-videos>