

Genitourinary Cancer

Tumor Marker Decline in Predicting Treatment Outcome among Poor-Risk Testicular Germ Cell Tumors—A Tertiary Cancer Center Data

Lakshmi Haridas K.¹ Francis V. James² Aswin Kumar² John Joseph² Jagathnath Krishna K.M.³¹Department of Medical Oncology, Regional Cancer Centre, Trivandrum, Kerala, India²Department of Radiation Oncology, Regional Cancer Centre, Trivandrum, Kerala, India³Department of Cancer Epidemiology and Biostatistics, Regional Cancer Centre, Trivandrum, Kerala, India

Address for correspondence Lakshmi Haridas K., DNB, DM, Department of Medical Oncology, Regional Cancer Centre, Trivandrum, Kerala, 695011, India (e-mail: lakshmiharidasrcc@gmail.com).

South Asian J Cancer 2022;11(3):218–222.

Abstract



Lakshmi Haridas K.

Introduction Testicular germ cell tumors are rare in India. Despite the advances in chemotherapy, poor-risk testicular nonseminomatous germ cell tumors (NSGCT) remain as a clinical challenge. Various prognostic factors have been described in this rare disease. The Indian data in this regard is scarce. Our study is the first attempt to assess the tumor marker decline with respect to treatment outcome in poor-risk NSGCT in Indian patients.

Materials and Methods This retrospective study was done among newly diagnosed poor-risk NSGCT, treated at genitourinary clinic, at our tertiary cancer center during the period 2017 to 2019. The prognostic significance of tumor marker decline in them was correlated with 2-year progression-free survival (PFS) and 2-year overall survival (OS). **Statistical Methods** The association between two variables were assessed using chi-squared/Fischer's exact test. The PFS and OS were estimated using Kaplan–Meier method and the significance difference between survival curves was tested using log rank test. The risk for survival was estimated using cox regression analysis. A *p*-value of <0.05 was considered as significant.

Results Out of 11 eligible patients, four (36%) had favorable tumor marker decline and seven (64%) had unfavorable decline. The 2-year PFS among favorable and unfavorable decline group were 66.7 and 42.9%, respectively (*p*-0.358), and the 2-year OS was 66.7 and 71.4%, respectively (*p*-0.974). Teratoma was not found to be a significant factor in our study. Tumors with only beta human chorionic gonadotropin (β HCG) elevation were observed to have good outcome. Postchemotherapy unresectable residual disease showed a significant trend toward inferior survival, the 2-year PFS was 38 versus 100% (*p*-0.188) and the 2-year OS was 62.5 versus 100% (*p*-0.334) in patients with and without unresectable residual disease, respectively.

Keywords

- ▶ poor risk NSGCT
- ▶ tumor marker decline
- ▶ postchemotherapy residual disease
- ▶ chemointensification
- ▶ nonseminomatous germ cell tumors

DOI <https://doi.org/10.1055/s-0042-1743423> ISSN 2278-330X

How to cite this article: Lakshmi Haridas K., James FV, Kumar A, et al. Tumor Marker Decline in Predicting Treatment Outcome among Poor-Risk Testicular Germ Cell Tumors—A Tertiary Cancer Center Data. South Asian J Cancer 2022;11(3):218–222.

© 2022. MedIntel Services Pvt Ltd. All rights reserved.

This is an open access article published by Thieme under the terms of the Creative Commons Attribution-NonDerivative-NonCommercial-License, permitting copying and reproduction so long as the original work is given appropriate credit. Contents may not be used for commercial purposes, or adapted, remixed, transformed or built upon. (<https://creativecommons.org/licenses/by-nc-nd/4.0/>)

Thieme Medical and Scientific Publishers Pvt. Ltd., A-12, 2nd Floor, Sector 2, Noida-201301 UP, India

Conclusion Majority of our poor-risk NSGCT patients had unfavorable tumor marker decline and progressive events. However, the survival difference was not significant, given the small sample size. Tumors with only β HCG elevation were observed to have good outcome. Postchemotherapy unresectable residual disease showed a significant trend toward inferior survival.

Introduction

Tumor marker decline (TMD)/normalization is crucial in nonseminomatous germ cell tumors (NSGCT) treatment.^{1,2} The currently available data are on western population and Indian data in this aspect is missing. This study is interested in correlating TMD with treatment outcome in poor-risk NSGCT among Indian patients.

Materials and Methods

This retrospective study was done among newly diagnosed poor-risk NSGCT, treated at genitourinary clinic, at our tertiary cancer center during the period 2017 to 2019. Present study aimed to study the prognostic significance of TMD in predicting treatment outcome in poor-risk testicular NSGCT and its correlation with 2-year progression-free survival (PFS) and 2-year overall survival (OS). The medical records of the study population were analyzed in detail for demographic characteristics, tumor markers (beta human chorionic gonadotropin [β HCG], alpha-fetoprotein [AFP], lactate dehydrogenase), staging workup, risk stratification, pathology details, treatment details, recurrence, and follow-up. The tumor markers, β HCG, and AFP measured at baseline and at day 21 of standard chemotherapy were entered in the European Society for Medical Oncology (ESMO) recommended online calculator (Gustave Roussy TMD calculator in poor-risk GCT) to assess the response, that is, either favorable decline or unfavorable decline.³ The treatment outcome and survival data in both these groups were recorded from the case records. PFS was calculated from the date of diagnosis to the documented date of first progression. OS was calculated from the date of diagnosis to the date of last follow-up or death. This analysis was performed when the most recent patient has completed 2 years of follow-up. The study was approved by the institutional review board.

Statistical Methods

The categorical variables were expressed in frequency and proportion. The continuous variables were summarized using mean and standard deviation. The association between two variables were assessed using chi-squared/Fischer's exact test. The PFS and OS were estimated using Kaplan–Meier method and the significance difference between survival curves was tested using log rank test. The risk for

survival was estimated using cox regression analysis. A *p*-value of <0.05 was considered as significant.

Results

Salient features are summarized in [Table 1](#).

A total of 11 patients with newly diagnosed poor risk testicular NSGCT were available for analysis. The median age was 25 years (range: 17–48 years). Eight patients presented with local swelling, four with breathlessness, and one each with abdominal pain, chest pain, lower limb weakness, and loss of weight, either alone or in combination. The median duration of symptoms was 2 months (range: 3 weeks–8 months). Six patients had right testicular involvement and five had left sided testicular involvement. The distant metastases were nonregional lymph nodes in one, pulmonary in nine, and nonpulmonary visceral metastases in seven (liver–4, bone–3, spleen–1, brain–1) patients, either alone or in combination. One patient had deranged renal function at baseline (creatinine clearance <50 ml/min). Six and five patients were treated with bleomycin, etoposide, cisplatin (BEP) and etoposide, ifosfamide, cisplatin (VIP), respectively. Four patients who had lung compromise at presentation underwent high inguinal orchidectomy after completion of planned chemotherapy.

Among 11 patients, four (36%) patients had favorable TMD and seven (64%) had unfavorable TMD.

Outcome of Favorable TMD Group ($n=4$)

All four (100%) patients in the favorable decline group had normalized tumor markers at the completion of four cycles of chemotherapy. Two (50%) patients had no residual disease at treatment end and are alive with no evidence of disease progression at 2 years of follow-up. One patient had unresectable bone and lung metastases after chemotherapy completion. He progressed at 1 year; however, contracted coronavirus disease 2019 (COVID-19) infection at 17th month and subsequently expired due to COVID-19 lung insult. The fourth patient had residual bone metastases at chemotherapy completion, but was lost to follow-up after 5 months.

Outcome of Unfavorable TMD Group ($n=7$)

In this group, all seven (100%) patients had unresectable residual disease and six (86%) had normal tumor markers after completion of chemotherapy. Progression was seen in four (57%) patients, all within 1 year (5 months, 7 months, 10 months, 11 months), among which, two expired at 14th

Table 1 Summary of patient profile and outcome

Sl. no.	Age	TMD	Site of metastases	AFP (0–11.3ng/mL)	BHCG (0.5–6.5 mIU/mL)	LDH (120–246 u/L)	Teratoma	URD	Probability of brain metastases score/ (%)	Recurrence status	Survival status
Pt 1	25 years	F	Nonregional lymph nodes	33,716	1,261	565	Y	N	0/0.6	Nil/46months	46 months/alive NED
Pt 2	44 years	F	NPVM (liver)	271	30	1,455	N	N	1/1	Nil/46months	46 months/alive NED
Pt 3	25 years	F	NPVM (bone), PM	4,802	0.1	242	N	Y	3/8	Progressed at 12th month	17 months/expired (*unrelated cause)
Pt 4	26 years	F	NPVM (bone), PM	126	0.1	1067	N	Y	3/8	Nil/5 month	5 months/lost to follow-up
Pt 5	48 years	U	PM	33,230	0.1	491	N	Y	3/8	Progressed at 5th month	14 months/expired (progressive ds)
Pt 6	22 years	U	NPVM (liver), PM	862	1,81,681	10193	Y	Y	4/18	Progressed at 7th month	14 months/expired (progressive ds)
Pt 7	18 years	U	PM	31,367	2,28,559	1662	N	Y	3/8	Progressed at 10th month	24 months/alive
Pt 8	29 years	U	NPVM (liver), PM	39	3,751	4847	N	Y	2/3.5	Nil/24month	24 months/alive
Pt 9	17 years	U	NPVM (bone, liver), PM	15,665	3.6	622	Y	Y	4/18	Progressed at 11th month	30 months/alive
Pt 10	35 years	U	PM	31,581	3,501	1,532	Y	Y	3/8	Nil/34months	34 months/alive
Pt 11	22 years	U	NPVM (spleen, brain), PM	0.5	6,37,496	969	N	Y	6/58	Nil/39months	39 months/alive

Abbreviations: AFP, alpha fetoprotein; BHCG, beta human chorionic gonadotropin; LDH, lactate dehydrogenase; NED, no evidence of disease; NPVM, nonpulmonary visceral metastases; PM, pulmonary metastases; TMD, tumor marker decline; URD, unresectable residual disease. Baseline characteristics and primary treatment were received.

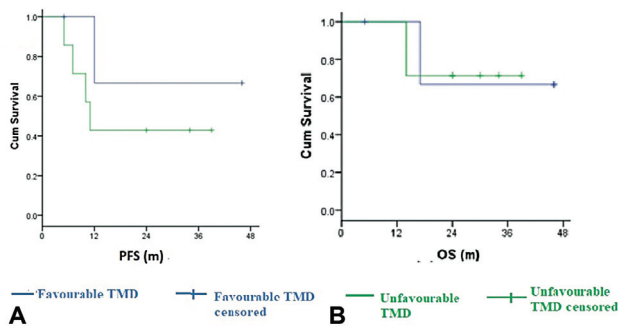


Fig. 1 (A, B) Kaplan–Meier curve showing progression-free survival (PFS) and overall survival (OS) in favorable and unfavorable tumor marker decline (TMD) group.

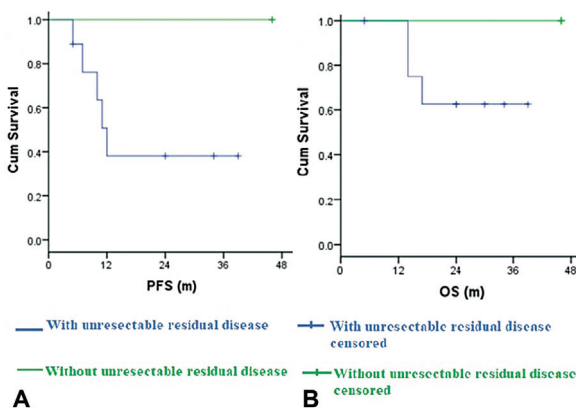


Fig. 2 (A, B) Kaplan–Meier curve showing progression-free survival (PFS) and overall survival (OS) in those with and without unresectable residual disease.

month due to organ failure (liver, renal) and disease progression. At 2 years of follow-up, three patients are progression free and five are alive.

Outcome Analysis

The 2-year PFS among favorable and unfavorable decline group were 66.7 and 42.9%, respectively ($p=0.358$), and the 2-year OS was 66.7 and 71.4%, respectively ($p=0.974$) (→ Fig. 1A and B). Teratoma was not found to be a significant factor in this study. Unresectable residual disease showed a trend toward inferior survival, both in terms of PFS and OS. The 2-year PFS among patients with and without unresectable residual disease was 38 versus 100% ($p=0.188$) and the 2-year OS was 62.5 versus 100% ($p=0.344$) (→ Fig. 2A and B).

The predicted risk for brain metastases was high in only one patient, with a score of 6 corresponding to 58% risk.⁴ This patient had brain metastases and was treated initially with whole brain radiotherapy with concurrent chemotherapy. The remaining patients had a score of <20% and none had brain metastases. It was also observed that patients with only β HCG elevation had not progressed till the time of last follow-up, when compared with those with elevated yolk sac component.

Discussion

Testicular NSGCT is one among the few curable malignancies, but poor-risk group is still a challenge of the era.⁵ Available Indian data in this field is sparse.^{6,7} Recently, Groupe d'Etude des Tumeurs Genito-Urinaires (GETUG)-13 investigators demonstrated PFS benefit by chemointensification among unfavorable TMD subgroup.⁸ Ours is the first Indian study to analyze the treatment outcome of patients with poor-risk NSGCT based on the TMD.

In our series, 11 patients were eligible for analysis. Commonest metastatic sites were pulmonary, followed/combined by liver, bone, spleen, brain, and nonregional lymph nodes. Six patients received BEP. Five patients with low diffusion capacity for carbon monoxide/low creatinine clearance received VIP chemotherapy.

Among 11 patients, four (36%) had favorable TMD and seven (64%) had unfavorable TMD. All favorable TMD patients achieved marker normalization after four cycles of chemotherapy. All patients with unfavorable TMD had unresectable residual disease, among which four patients progressed within a year. Two expired within a year due to organ failure (liver, renal) and disease progression. They were unfit for high-dose chemotherapy and stem cell rescue and were not considered for the same. The differences in PFS and OS between the two groups, however, were not statistically significant in our study, probably due to the small patient population.

Patients with β HCG only elevation ($n=2$) have not progressed and are alive at the time of analysis. In the remaining patients ($n=9$), where AFP was also elevated, five progressed within a year. Data on prognostic significance of differential response to tumor markers is not available at present. Teratoma was not found to significant in our study.

Another significant observation in this study was that patients with unresectable residual disease showed a trend toward inferior survival, both in terms of PFS and OS. The 2-year PFS among those with and without unresectable residual disease was 38 versus 100% ($p=0.188$) and the 2-year OS was 62.5 versus 100% ($p=0.334$). This shows that surgical resectability is an equally important factor influencing treatment outcomes of poor-risk NSGCT patients and on every possible occasion, postchemotherapy residual disease >1 cm needs to be excised.^{9,10}

The major limitation of our study is the small patient sample. However, in a low incident country like ours, this data adds to the present Indian literature.

Conclusion

Among poor-risk NSGCT patients, the survival difference between favorable and unfavorable TMD patients was not statistically significant, given the small sample size. Tumors with only β HCG elevation were observed to have good outcome. Postchemotherapy residual disease substantially influenced their treatment outcome.

Authors' Contribution

Lakshmi Haridas K. was involved in concepts, design, definition of intellectual content, literature search, and manuscript editing.

Francis V. James was involved in data acquisition and manuscript preparation.

Aswin Kumar and John Joseph were involved in manuscript preparation.

Jagathnath Krishna K.M. was involved in statistical analysis and manuscript preparation.

Institutional Review Board approval

Obtained

Funding

None.

Conflict of interest

None declared.

Acknowledgment

Nil.

References

- 1 Toner GC, Geller NL, Tan C, Nisselbaum J, Bosl GJ. Serum tumor marker half-life during chemotherapy allows early prediction of complete response and survival in nonseminomatous germ cell tumors. *Cancer Res* 1990;50(18):5904–5910
- 2 Fizazi K, Culine S, Kramar A, et al. Early predicted time to normalization of tumor markers predicts outcome in poor-prognosis nonseminomatous germ cell tumors. *J Clin Oncol* 2004;22(19):3868–3876
- 3 <http://www.gustaveroussy.fr/calculation-tumor/NSGCT.html>
- 4 Tewari A. Prediction Model for Brain Metastasis in Patients with Metastatic Germ-Cell Tumors Accounting for Size of Pulmonary Metastases. 2021. American Society of Clinical Oncology Genitourinary Cancers Symposium
- 5 Honecker F, Aparicio J, Berney D, et al. ESMO Consensus Conference on testicular germ cell cancer: diagnosis, treatment and follow-up. *Ann Oncol* 2018;29(08):1658–1686
- 6 Nair LM, Krishna KMJ, Kumar A, Mathews S, Joseph J, James FV. Prognostic factors and outcomes of nonseminomatous germ cell tumours of testis-experience from a tertiary cancer centre in India. *Ecancermedicalscience* 2020;14:1145. Doi: 10.3332/ecancer.2020.1145
- 7 Saju SV, Radhakrishnan V, Ganesan TS, et al. Factors that impact the outcomes in testicular germ cell tumors in low-middle-income countries. *Med Oncol* 2019;36(03):28. Doi: 10.1007/s12032-019-1252-6
- 8 Fizazi K, Flechon A, Le Teuff G, et al. Mature results of the GETUG 13 phase III trial in poor-prognosis germ-cell tumors. *J Clin Oncol* 2016;34(15, suppl):4504–4504
- 9 Ghodoussipour S, Daneshmand S. Postchemotherapy resection of residual mass in nonseminomatous germ cell tumor. *Urol Clin North Am* 2019;46(03):389–398
- 10 King J, Adra N, Einhorn LH. Management of residual disease after chemotherapy in germ cell tumors. *Curr Opin Oncol* 2020;32(03):250–255