

- tromagnetics 2003;24:165-173.
6. Szabo I, Rojavin MA, Rogers TJ, Ziskin MC. Reactions of keratinocytes to in vitro millimeter wave exposure. *Bioelectromagnetics* 2001;22:358-364.
  7. Chen Q, Zeng QL, Lu DQ, Chiang H. Millimeter wave exposure reverses TPA suppression of gap junction intercellular communication in HaCaT human keratinocytes. *Bioelectromagnetics* 2004;25:1-4.
  8. Park J, Kim C, Lee J, Yim C, Kim CH, Lee J, et al. Generation, transport, and detection of linear accelerator based femtosecond-terahertz pulses. *Rev Sci Instrum* 2011; 82:013305.
  9. Feng NH, Lee HH, Shiang JC, Ma MC. Transient receptor potential vanilloid type 1 channels act as mechanoreceptors and cause substance P release and sensory activation in rat kidneys. *Am J Physiol Renal Physiol* 2008;294:F316-F325.

<http://dx.doi.org/10.5021/ad.2014.26.1.132>

## Leukotrichia in Stable Segmental Vitiligo: Implication of an Alternate Treatment Option

Hyun Joong Jee, Jeong Eun Do<sup>1</sup>, Seongmin Noh, Sang Hoon Park<sup>2</sup>, Sang Ho Oh

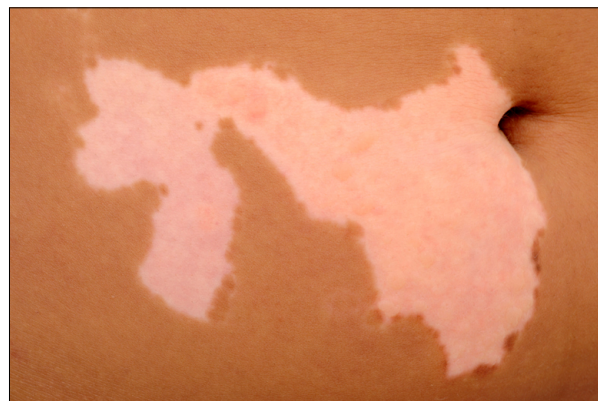*Department of Dermatology, Severance Hospital, Cutaneous Biology Research Institute, Yonsei University College of Medicine, <sup>1</sup>Yeouido Oracle Skin Clinic, <sup>2</sup>JNA Dermatology Clinic, Seoul, Korea*

Dear Editor:

Vitiligo is traditionally divided into two distinct clinical forms, nonsegmental vitiligo (NSV) and segmental vitiligo (SV). SV usually accompanies leukotrichia, which indicates that the condition is resistant to medical treatment and requires epidermal grafting<sup>1</sup>. In this case, perifollicular repigmentation was induced in a patient with SV and concurrent leukotrichia that was previously unresponsive to narrow-band ultraviolet B (NBUVB) phototherapy after the patient suffered an accidental burn on the denuded but uncovered area during phototherapy following an epidermal graft.

A 12-year-old girl presented to our clinic with white

patches that had initially developed on the right side of her trunk 2 years prior. Physical examination showed well-defined depigmented patches containing white hairs along the right T6~T12 dermatomes (Fig. 1). White accentuation with obvious fluorescence was detected using Wood's lamp. She had received NBUVB phototherapy for 5 months without remarkable improvement. Upon consent, a suction blister epidermal graft was performed. Due to the sizeable lesion, several sessions of epidermal

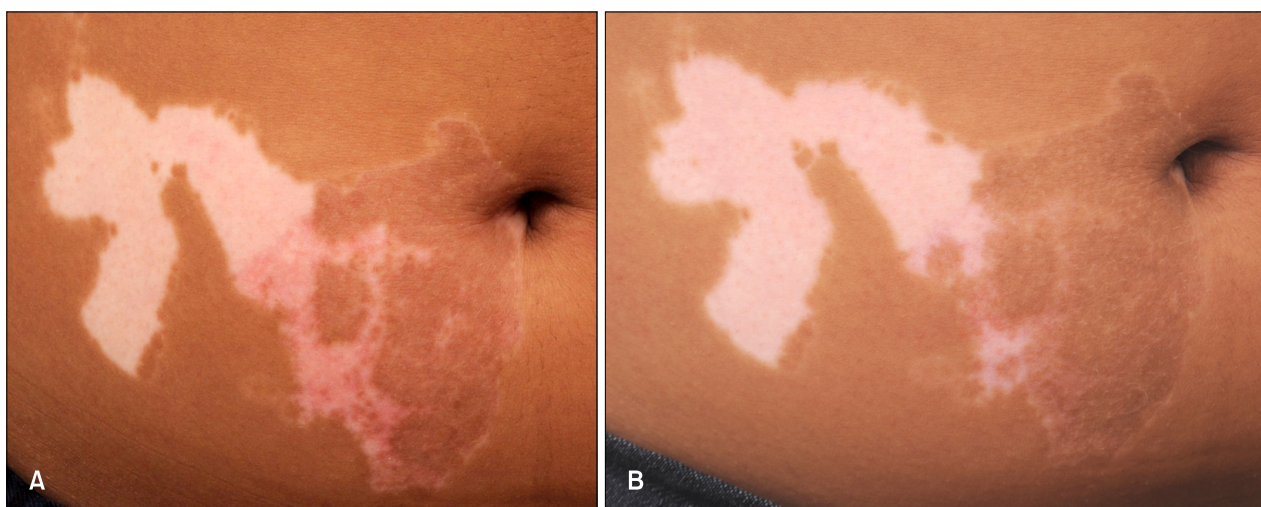


**Fig. 1.** Well-defined depigmented patches along the right T6~T12 dermatomes.

Received December 14, 2012, Revised March 4, 2013, Accepted for publication March 22, 2013

**Corresponding author:** Sang Ho Oh, Department of Dermatology, Severance Hospital, Cutaneous Biology Research Institute, Yonsei University College of Medicine, 50 Yonsei-ro, Seodaemun-gu, Seoul 120-749, Korea. Tel: 82-2-2228-2080, Fax: 82-2-393-9157, E-mail: oddung93@yuhs.ac

This is an Open Access article distributed under the terms of the Creative Commons Attribution Non-Commercial License (<http://creativecommons.org/licenses/by-nc/3.0>) which permits unrestricted non-commercial use, distribution, and reproduction in any medium, provided the original work is properly cited.



**Fig. 2.** (A) Diffuse and perifollicular repigmentation both on the covered and uncovered recipient site after 2 weeks. (B) Near complete repigmentation on the recipient site after 12 weeks.

grafting were required.

One week later, after we grossly concluded that the previously uncovered areas were fully recovered, phototherapy was initiated. After 3 days, the patient returned to the clinic only to display a burn on the formerly denuded but uncovered area. Further treatment was delayed until the area was completely healed, and 10 days later, treatment was re-engaged starting with  $700 \text{ mJ/cm}^2$ , with an incremental 15% increase in dose during every subsequent course. Interestingly, after 2 weeks, spontaneous repigmentation at the denuded but uncovered site was observed along with that in the covered site (Fig. 2A). On the patient's subsequent visit 2 months later, the recipient area, again including the uncovered area, was almost completely pigmented (Fig. 2B).

Surgical treatment can be considered when vitiligo does not respond to traditional treatments. The procedure is particularly suitable in cases that show complete loss of melanocytes or in cases that have a low possibility of repigmentation that is clinically indicated by the presence of leukotrichia<sup>2</sup>. It has been suggested that visualization of leukotrichia in the vitiliginous lesions of patients with SV using portable digital microscopy indicates no hope of repigmentation and, therefore, that a surgical approach is recommended<sup>1</sup>. A recent preliminary study, however, reported that although tyrosinase-positive melanocytes are only observed in black hair follicles, melanocytes still exist in the white hair follicles, although they are fewer in number than those in black hair follicles<sup>2</sup>. These findings suggest that the melanocyte reservoir is not completely depleted in vitiligo lesions showing leukotrichia.

According to an earlier study that revealed the promising

result of combination treatment with an erbium:YAG laser and 5-fluorouracil ointment followed by NBUVB for the treatment of vitiligo, 78.1% of enrolled patients showed moderate to marked repigmentation<sup>3</sup>. In addition, microdermabrasion combined with pimecrolimus 1% cream has been reported to be effective without causing significant side effects including koebnerization in children with NSV<sup>4</sup>. The findings of these two studies suggest that epidermal damage caused by the erbium:YAG laser and microdermabrasion could induce the secretion of chemical mediators that are beneficial for melanocyte activation and enhance the NBUVB penetration and drug absorption into inactive melanocytes existing at the outer root sheath of the hair follicles.

Similarly, we believe that in our case, the sunburn of the lesion uncovered by a graft after phototherapy might have induced the formation of various chemical mediators and growth factors which could stimulate epidermal melanocytes and induce the proliferation and migration of inactive melanocytes in the outer root sheaths of hair follicles in the depigmented lesions<sup>5</sup> despite the presence of leukotrichia. The burn itself would also increase the transmittance and accessibility of NBUVB into inactive melanocytes in the outer root sheath, further inducing perifollicular repigmentation.

In patients with SV, the coexistence of leukotrichia, has been considered a poor prognostic marker of disease that is often refractory to traditional treatment and eventually forces both the patient and the doctor into a surgical solution. Our case, however, shows that the few melanocytes that still remained in the hair follicles with leukotrichia could serve as a source of perifollicular repig-

mentation and points to an optimistic future involving treatment without the need for invasive epidermal grafting.

## REFERENCES

1. Lee DY, Park JH, Lee JH, Yang JM, Lee ES. Is segmental vitiligo always associated with leukotrichia? Examination with a digital portable microscope. *Int J Dermatol* 2009;48:1262.
2. Taieb A, Picardo M; VETF Members. The definition and assessment of vitiligo: a consensus report of the Vitiligo European Task Force. *Pigment Cell Res* 2007;20:27-35.
3. Anbar TS, Westerhof W, Abdel-Rahman AT, Ewis AA, El-Khayyat MA. Effect of one session of ER:YAG laser ablation plus topical 5Fluorouracil on the outcome of short-term NB-UVB phototherapy in the treatment of non-segmental vitiligo: a left-right comparative study. *Photodermatol Photoimmunol Photomed* 2008;24:322-329.
4. Farajzadeh S, Daraei Z, Esfandiarpour I, Hosseini SH. The efficacy of pimecrolimus 1% cream combined with microdermabrasion in the treatment of nonsegmental childhood vitiligo: a randomized placebo-controlled study. *Pediatr Dermatol* 2009;26:286-291.
5. Horikawa T, Norris DA, Yohn JJ, Zekman T, Travers JB, Morelli JG. Melanocyte mitogens induce both melanocyte chemokinesis and chemotaxis. *J Invest Dermatol* 1995;104:256-259.

<http://dx.doi.org/10.5021/ad.2014.26.1.134>

# The Expression of Involucrin, Loricrin, and Filaggrin in Cultured Sebocytes

Weon Ju Lee, Kyung Hea Park, Hyun Wuk Cha, Mi Yeung Sohn, Kyung Duck Park, Seok-Jong Lee, Do Won Kim

*Department of Dermatology, Kyungpook National University School of Medicine, Daegu, Korea*

Dear Editor:

It is well established that a complex interplay of corneocytes and intercellular lipids in the stratum corneum of the skin is responsible for the skin barrier against environmental factors. A cornified cell envelope, which is composed of involucrin, loricrin, filaggrin, and other proteins, is a component of fully differentiated epidermal keratinocytes and corneocytes, and it is important in the skin barrier<sup>1</sup>. Although sebaceous gland sebocytes are considered to originate from the same stem cells as epidermal keratinocyte, it is not clear whether the keratinocyte differentiation markers are expressed in the sebocytes or not<sup>2</sup>. Because

the transfollicular route has been known as a major route for drug delivery, more information is required to investigate the expression of the markers in the sebaceous gland sebocytes.

A primary culture of human scalp sebocytes was performed with Dulbecco's modified Eagle's medium (DMEM; Gibco BRL, Grand Island, NY, USA) and Epilife (MEPI500CA; Gibco BRL) according to a method described previously<sup>3</sup>. Sebocytes were cultured at various concentrations of calcium (0.25, 0.5, 1, and 1.2 mM), or treated with vitamin D ( $10^{-10}$ ,  $10^{-9}$ ,  $10^{-8}$ ,  $10^{-7}$ , and  $10^{-6}$  M). Reverse transcription polymerase chain reaction (RT-PCR) for invo-

Received November 29, 2012, Revised March 6, 2013, Accepted for publication March 25, 2013

**Corresponding author:** Weon Ju Lee, Department of Dermatology, Kyungpook National University School of Medicine, 200 Dongduk-ro, Jung-gu, Daegu 700-721, Korea. Tel: 82-53-420-5838, Fax: 82-53-426-0770, E-mail: weonju@knu.ac.kr

This is an Open Access article distributed under the terms of the Creative Commons Attribution Non-Commercial License (<http://creativecommons.org/licenses/by-nc/3.0>) which permits unrestricted non-commercial use, distribution, and reproduction in any medium, provided the original work is properly cited.