

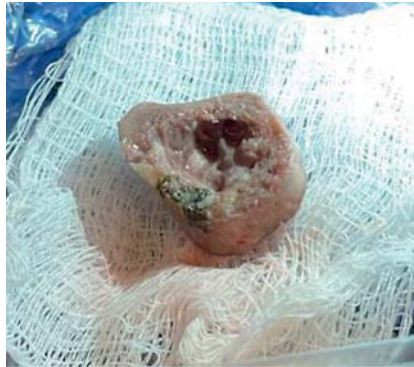
Modified endoscopic vacuum therapy for hypopharyngeal acute leakage after foreign body perforation



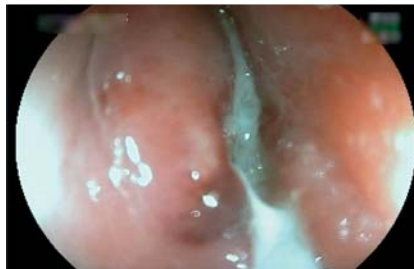Conventional endoscopic vacuum therapy is currently used worldwide to treat esophageal leaks, with a healing rate of 67%–100% [1,2]. The vacuum effect works through its effect on important mechanisms such as micro and macro deformation, tissue reperfusion, exudate control, and bacterial clearance [3]. Modified endoscopic vacuum therapy (MEVT) has some benefits when compared with the conventional technique, such as lower costs, less adherence, the requirement for fewer exchanges, and a shorter procedural duration [2]. In addition, it can be easily performed [4]. Although there were no reported cases of the use of hypopharyngeal vacuum therapy, we report a hypopharyngeal leak that was successfully treated with MEVT, leading to a new possibility when faced with hypopharyngeal defects.

A 42-year-old man came to the emergency room with progressive dysphagia 24 hours after eating food that included a piece of bone. A computed tomography (CT) scan detected a foreign body measuring 3.2×1.1 cm at the hypopharynx. Orotracheal intubation by bronchoscopy was indicated. Subsequently, the patient underwent endoscopic foreign body removal (► Fig. 1); on reviewing the mucosa, we noted signs of perforation (► Fig. 2). Therefore, MEVT was performed (► Fig. 3; ► Video 1). The patient remained intubated for 5 days, during which time he received MEVT, antibiotics, and corticosteroids. After this period, a new bronchoscopy was performed, which demonstrated improvement of the edema of the hypopharynx, and the patient was extubated.

The patient progressively improved in terms of his clinical and laboratory parameters. He was evaluated by the otorhinolaryngology team after 8 days and a swallowing video-endoscopy was performed. This evaluation visualized



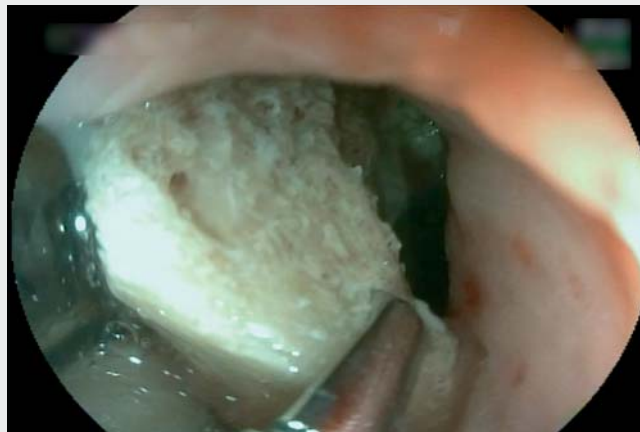► Fig. 1 Photograph of the foreign body, which was a piece of pork bone.



► Fig. 2 Endoscopic view showing a hypopharyngeal perforation.

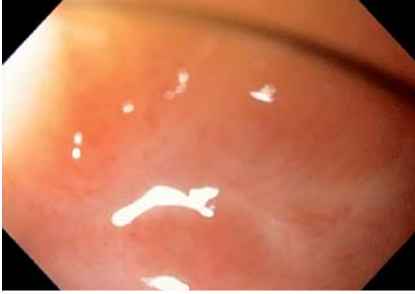

► Fig. 3 Photograph of the modified endoscopic vacuum therapy device that was used.



► Video 1 Endoscopy vacuum therapy is performed in the management of a hypopharyngeal leak caused by a perforation that was identified after endoscopic removal of a foreign body.





► **Fig. 4** Endoscopic view showing a white scar after the leak had been successfully treated.






complete velopharyngeal closure, the presence of salivary stasis, and preserved mobility, so his diet was upgraded to an oral homogeneous intake with a paste-like consistency. Endoscopic re-evaluation after 1 month demonstrated a white scar, with no signs of stenosis or other complications (► **Fig. 4**). Outpatient follow-up demonstrated good tolerance of a regular diet, and the patient did not report any complaints.

Endoscopy_UCTN_Code_TTT_1AQ_2AG

Competing interests

The authors declare that they have no conflict of interest.

The authors

João Guilherme Ribeiro Jordão Sasso , Erika Yuki Yvamoto, Rodrigo Silva de Paula Rocha, Igor Braga Ribeiro , Mateus Bond Boghossian , Diogo Turiani Hourneaux de Moura , Eduardo Guimarães Hourneaux de Moura 

Gastrointestinal Endoscopy Service, University of São Paulo Faculty of Medicine Clinics Hospital (HCFMUSP), Sao Paulo, Brazil

Corresponding author

Igor Braga Ribeiro, MD, PhD

Av. Dr. Enéas de Carvalho Aguiar, 255, Instituto Central – Prédio dos Ambulatórios, Cerqueira César, São Paulo, SP, 05403-000, Brazil
igorbraga1@gmail.com

References

- [1] Virgilio E, Ceci D, Cavallini M. Surgical endoscopic vacuum-assisted closure therapy (EVAC) in treating anastomotic leakages after major resective surgery of esophageal and gastric cancer. *Anticancer Res* 2018; 38: 5581–5587
- [2] do Monte Junior ES, de Moura DTH, Ribeiro IB et al. Endoscopic vacuum therapy versus endoscopic stenting for upper gastrointestinal transmural defects: Systematic review and meta-analysis. *Dig Endosc* 2021; 33: 892–902
- [3] de Moura DTH, de Moura BFBH, Manfredi MA et al. Role of endoscopic vacuum therapy in the management of gastrointestinal transmural defects. *World J Gastrointest Endosc* 2019; 11: 329–344
- [4] de Moura DTH, Hirsch BS, do Monte Junior ES et al. Cost-effective modified endoscopic vacuum therapy for the treatment of gastrointestinal transmural defects: step-by-step process of manufacturing and its advantages. *VideoGIE* 2021; 6: 523–528

Bibliography

Endoscopy 2022; 54: E1022–E1023

DOI 10.1055/a-1901-0829

ISSN 0013-726X

published online 24.8.2022

© 2022. The Author(s).

This is an open access article published by Thieme under the terms of the Creative Commons Attribution-NonDerivative-NonCommercial License, permitting copying and reproduction so long as the original work is given appropriate credit. Contents may not be used for commercial purposes, or adapted, remixed, transformed or built upon. (<https://creativecommons.org/licenses/by-nc-nd/4.0/>)

Georg Thieme Verlag KG, Rüdigerstraße 14, 70469 Stuttgart, Germany



ENDOSCOPY E-VIDEOS

<https://eref.thieme.de/e-videos>



Endoscopy E-Videos is an open access online section, reporting on interesting cases and new techniques in gastroenterological endoscopy. All papers include a high quality video and all contributions are freely accessible online. Processing charges apply (currently EUR 375), discounts and waivers acc. to HINARI are available.

This section has its own submission website at <https://mc.manuscriptcentral.com/e-videos>