

# Testicular microlithiasis and preliminary experience of acoustic radiation force impulse imaging

Malene Roland Pedersen<sup>1,2,3</sup>, Palle Jørn Sloth Oster<sup>2,3</sup>  
and Søren Rafael Rafaelsen<sup>1,3</sup>

Acta Radiologica Open  
5(7) 1–4  
© The Foundation Acta Radiologica  
2016  
Reprints and permissions:  
sagepub.co.uk/journalsPermissions.nav  
DOI: 10.1177/2058460116658686  
arr.sagepub.com



## Abstract

**Background:** Elastography of the testis can be used as a part of multiparametric examination of the scrotum.

**Purpose:** To determine the testicular stiffness using acoustic radiation force impulse imaging (ARFI) technique in men with testicular microlithiasis (TML).

**Material and Methods:** In 2013, 12 patients with diagnosed testicular microlithiasis in 2008 (mean age, 51 years; age range, 25–76 years) underwent a 5-year follow-up B-mode ultrasonography with three ARFI elastography measurements of each testis. We used a Siemens Acuson S3000 machine.

**Results:** No malignancy was found at the 5-year follow-up B-mode and elastography in 2013. However, we found an increase in TML; in the previous ultrasonography in 2008, eight men had bilateral TML, whereas in 2013, 10 men were diagnosed with bilateral TML. The mean elasticity of testicles with TML was 0.82 m/s (interquartile range [IQR], 0.72–0.88 m/s; range, 65–1.08 m/s).

**Conclusion:** Elastography velocity of testis with TML seems to be in the same velocity range as in men with normal testis tissue.

## Keywords

Elastography, testicular microlithiasis, acoustic radiation force impulse imaging (ARFI), ultrasonography

Date received: 14 March 2016; accepted: 16 June 2016

## Introduction

Soft tissue is elastic and elasticity is now measurable using ultrasonographic (US) elastography. Some studies have shown how the normal range of elasticity varies in different types of tissue in regards to various organs, such as e.g. liver (1), breast (2), rectum (3), lymph nodes (4), prostate (5), and testicle (6,7).

Shear-wave elastography is a quantitative method used to evaluate tissue stiffness (8,9). The basic principles of acoustic radiation force impulse imaging (ARFI) elastography is the compression of the tissue of interest and the application of an ultrasound probe that automatically produces an acoustic push pulse that generates shear-waves. The speed of the ultrasound waves is either measured in meters/second (m/s) or kilopascal (kPa), and within seconds the result is displayed on the ultrasound-screen. ARFI elastography is safe, fast, easy to use, and operator-independent.

Testicular microlithiasis (TML) was first described using US by Doherty et al. (10) as innumerable tiny bright echoes diffusely and uniformly scattered throughout their substance. TML is of unknown origin, and the size of TML typically has a range of 1–3 mm. The diagnosis of TML has shown reliable results concerning inter-observer variability (11). ARFI is a new technique to measure elasticity in the

<sup>1</sup>Department of Radiology, Vejle Hospital, Part of Lillebaelt Hospital, Denmark

<sup>2</sup>Urological Research Centre, Fredericia Hospital, Part of Lillebaelt Hospital, Denmark

<sup>3</sup>Institute of Regional Health Research, University of Southern Denmark, Odense, Denmark

### Corresponding author:

Malene Roland Pedersen, Department of Radiology, Vejle Hospital, Part of Lillebaelt Hospital, Kabbeltøft 25, DK-7100 Vejle, Denmark.  
Email: malene.roland.vils.pedersen@rsyd.dk



testicles. To our knowledge, no study has previously investigated testicles with TML using ARFI.

The primary aim of this study was to evaluate the tissue stiffness in testicles with diagnosed TML.

## Material and Methods

The Danish Data Protection Agency and The Regional Scientific Ethical Committees for Southern Denmark (ID: S-20120144) approved the study.

Twenty-seven men with known TML diagnosed in 2008 received an invitation to participate in the study in October 2013. All patients were contacted by post and written informed consent was obtained from each patient prior to the US examination. Fifteen men agreed to participate; however, two men failed the appointment. One patient was excluded due to a previously orchietomy of the left testicle diagnosed with a Leydig cell tumor.

All procedures were carried out with the patient in the supine position. All patients underwent a B-mode US including ARFI elastography of both testicles. We used a Siemens S3000 ultrasound machine (Acuson Corporation, Siemens, Mountain View, CA, USA) with virtual touch™ tissue quantification software. All the examinations were performed using a linear-array 9L4 frequency transducer.

All the ARFI measurements were performed by one of the authors (MRP) and a senior consultant monitored the examinations, thereby eliminating inter-observer variability.

Three ARFI shear-wave velocity measurements were performed in each testicle. The ARFI measurements were carefully performed away from the vas deferens. If the ARFI velocity result showed XX m/s elastography was not able to obtain a measurement and another measurement was performed. Impax PACS (Picture Archive Communication System (PACS), Easyviz Impax Workstation, Medical Insight, Valby, Denmark) stored all the US imaging. Lastly, we studied all previously US reports to evaluate if there had been a change in TML status.

Descriptive statistics were used including Mann–Whitney U test.

## Results

A velocity value was obtained in all 72 ARFI measurements. Table 1 shows ARFI velocity in m/s. We found no significant difference in the ARFI measurements between the right and left testicle using the Mann–Whitney U test. Four of the testicles showed no sign of TML with a mean velocity of 0.80 m/s (interquartile range [IQR], 0.78–0.84 m/s; range, 0.75–0.92 m/s).

**Table 1.** Testicular stiffness in 12 men with microlithiasis.

Testis	Mean (m/s)	SD	IQR (m/s)	Range (m/s)
Total	0.82	0.127	0.72–0.88	0.65–1.08
Right	0.82	0.135	0.73–0.89	0.65–1.08
Left	0.83	0.125	0.71–0.86	0.71–1.08

IQR, interquartile range; SD, standard deviation.

Figs. 1 and 2 show elastography measurements in m/s in two men with classic TML.

The mean age of the participants was 51 years (age range, 25–76 years).

Of the 12 men with TML, none was diagnosed with testicular cancer in 2008 or at the follow-up US in 2013. Over time we observed an increase in the amount of TML in six of the men, while the amount of TML in the remaining six men remained unchanged.

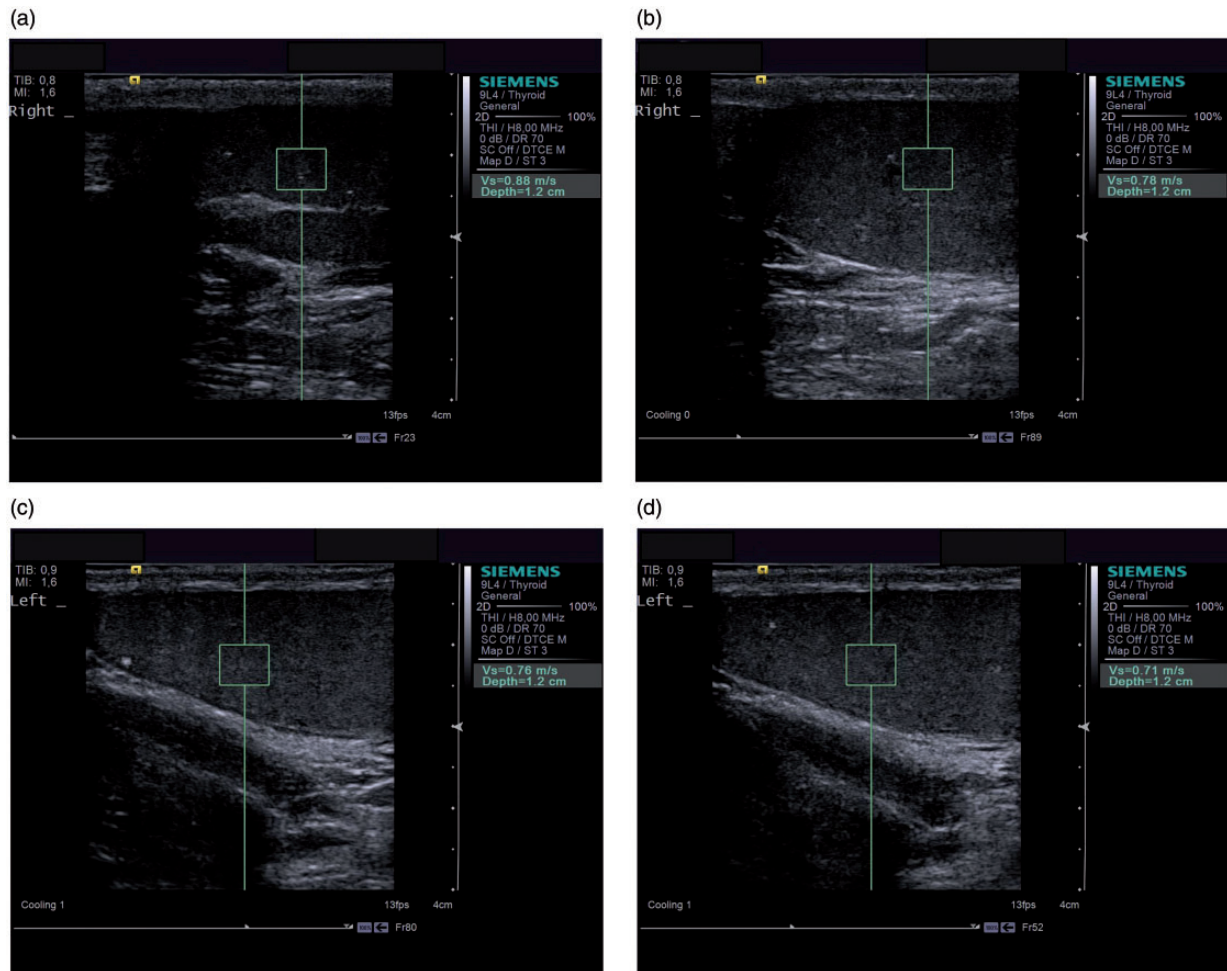
Generally, there was a slight increase in number of testicles with TML over time, since eight men were diagnosed with bilateral TML in 2008 and 10 in 2013.

Seven patients had additional diagnoses: two men with unilateral varicocele; one with bilateral varicocele; two with spermatocele; two with a minor calcification outside the testicle; one ductal ectasia; one had sequelae after a dog bite; and one had sequelae after mumps in early childhood. One of the men had previously undergone biopsy showing no malignancy. Four of the men had undergone vasectomy.

## Discussion

The mean velocities were 0.82 m/s in the right and 0.83 m/s in the left TML testicles. So far no published data exist on ARFI elastography of testicles with testicular microlithiasis. Trottmann et al. (12) showed a mean of 1.17 m/s in a normal testicle, and D’Anastasi et al. showed a range of 0.62–1.01 m/s in healthy volunteers (6). Since a testicle with TML includes various degrees of microcalcifications, an increased stiffness could be expected affecting the velocity in the testicle. We found a mean stiffness similar to the findings of D’Anastasi et al., suggesting that testicles with TML do not differ substantially in stiffness from normal testicles.

Some authors believe TML to be associated with testicular cancer (13–15), while others disagree (16,17). Thus, the association between TML and testicular cancer is still controversial and risk factors needs more attention. Since the ARFI measurements in TML testicles were within the range of a normal testicle, this supports the view that TML alone probably is not an independent risk factor for testicular cancer, which was additionally confirmed by the fact



**Fig. 1.** (a) Ultrasonography ARFI elastography of the right testicles measured in m/s in a 41-year-old man diagnosed with bilateral TML. Note the elastography box measures  $1 \times 1$  cm and cannot be altered. (b) Ultrasonography ARFI elastography of the right testicles measured in m/s in a 41-year-old man diagnosed with bilateral TML. Notice the elastography box measures  $1 \times 1$  cm and cannot be altered. (c) Ultrasonography ARFI elastography of the left testicles measured in m/s in a 41-year-old man diagnosed with bilateral TML. Note the elastography box measures  $1 \times 1$  cm and cannot be altered. (d) Ultrasonography ARFI elastography of the left measured in m/s in a 41-year-old man diagnosed with bilateral TML. Note the elastography box measures  $1 \times 1$  cm and cannot be altered.

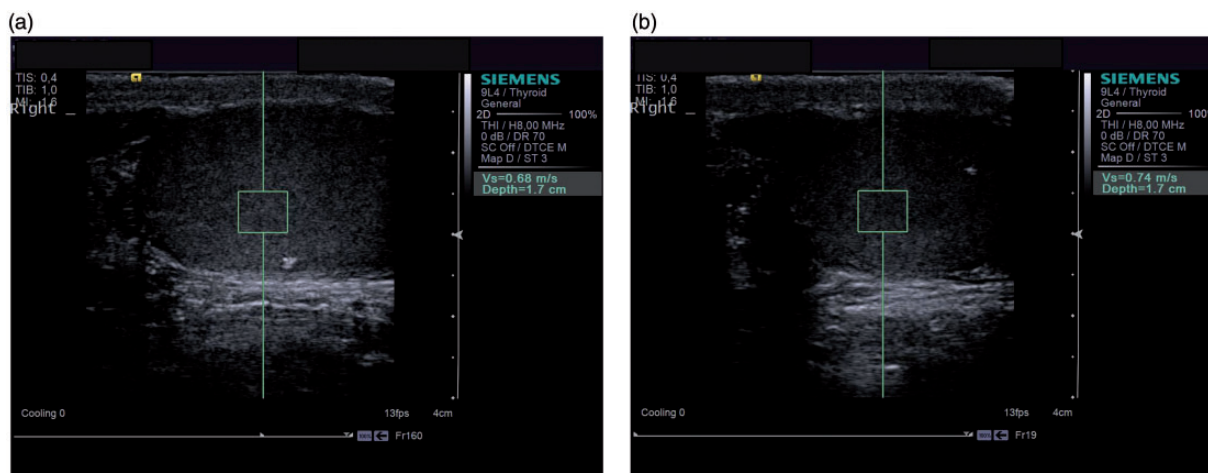
that none of the individuals in our series developed testicular cancer within a 5-year observation period.

As of today, elastography may be used to diagnose liver cirrhosis as an alternative to biopsy and follow-up. Whether elastography may have the same potential in testicular cancer is still unknown. Malignant lesions tend to have a harder stiffness compared to normal tissue. The European Society of Urogenital Radiology (ESUR) recommends yearly US follow-up in men with TML and an additional risk factor such as personal/family history of testicular cancer, maldescent, orchidopexy, and testicular atrophy (18). When US follow-up includes elastography, it is possible to evaluate the testicular stiffness yearly. Whether this will add

to early diagnosis of testicular cancer still needs evaluation.

The strengths of this study included a long observation period and that the ARFI measurements were without inter-individual variation. On the other hand, to introduce this method as a routine clinical tool, inter-observer data are needed. The limitations of the study include the relatively small number of patients and that only three measurements of each testicle were performed. Above-mentioned data from healthy testicles included a higher number of measurements (6).

In conclusion, we found mean velocity of testicle with TML to be 0.82 m/s. (IQR, 0.72–0.88 m/s), which is comparable to normal testicle tissue.



**Fig. 2.** (a) Ultrasonography ARFI elastography measured in the right testicle in a 54-year-old man diagnosed with bilateral classic TML. (b) Ultrasonography ARFI elastography measured in the right testicle in a 54-year-old man diagnosed with bilateral classic TML.

### Acknowledgements

The authors would like to thank Anna and Robert Mihare for their language polishing and sonographer Karl Erik Stovgaard for his technical support.

### Declaration of conflicting interests

The authors declared no potential conflicts of interest with respect to the research, authorship, and/or publication of this article.

### Funding

The region of Southern Denmark and the Union of Radiographers in Denmark supported this study.

### References

- Hanquinet S, Rougemont AL, Courvoisier D, et al. Acoustic radiation force impulse (ARFI) elastography for the noninvasive diagnosis of liver fibrosis in children. *Pediatr Radiol* 2013;43:545–551.
- Athanasίου A, Tardivon A, Tanter M, et al. Breast lesions: Quantitative elastography with supersonic shear imaging—preliminary results. *Radiology* 2010;256:297–303.
- Rafaelsen SR, Vagn-Hansen C, Sørensen T, et al. Ultrasound elastography in patients with rectal cancer treated with chemoradiation. *Eur J Radiol* 2013;82:913–917.
- Meng W, Xing P, Chen Q, et al. Initial experience of acoustic radiation force impulse ultrasound imaging of cervical lymph nodes. *Eur J Radiol* 2013;82:1788–1792.
- Zhai L, Polascik TJ, Foo WC, et al. Acoustic radiation force impulse imaging of human prostates: initial in vivo demonstration. *Ultrasound Med Biol* 2012;38:50–61.
- D’Anastasi M, Schneevoigt BS, Trottmann M, et al. Acoustic radiation force impulse imaging of the testes: A preliminary experience. *Clin Hemorheol Microcirc* 2011; 49:105–114.
- Patel KV, Huang DY, Sidhu PS. Metachronous bilateral segmental testicular infarction: multi-parametric ultrasound imaging with grey-scale ultrasound, Doppler ultrasound, contrast-enhanced ultrasound (CEUS) and real-time tissue elastography (RTE). *J Ultrasound* 2014; 17:233–238.
- Palmeri ML, Nightingale KR. Acoustic radiation force-based elasticity imaging methods. *Interface Focus* 2011;1: 553–564.
- Nightingale KR, Soo MS, Nightingale R, et al. Acoustic radiation force impulse imaging: in vivo demonstration of clinical feasibility. *Ultrasound Med Biol* 2002;28:227–235.
- Doherty FJ, Mullins TL, Sant GR, et al. Testicular microlithiasis. A unique sonographic appearance. *J Ultrasound Med* 1987;6:389–392.
- Pedersen MR, Graumann O, Horlyck A, et al. Inter- and intraobserver agreement in detection of testicular microlithiasis with ultrasonography. *Acta Radiol* 2016;57: 767–772.
- Trottmann M, Marcon J, D’Anastasi M, et al. The role of VTIQ as a new tissue strain analytics measurement technique in testicular lesions. *Clin Hemorheol Microcirc* 2014;58:195–209.
- Derogee M, Bevers RFM, Prins HJ, et al. Testicular microlithiasis, a premalignant condition: prevalence, histopathologic findings, and relation to testicular tumor. *Urology* 2001;57:1133–1137.
- Sakamoto H, Shichizyou T, Saito K, et al. Testicular microlithiasis identified ultrasonographically in Japanese adult patients: prevalence and associated conditions. *Urology* 2006;68:636–641.
- Thomas D, Vlachopapadopoulou E, Papadakis V, et al. Testicular microlithiasis in siblings: clinical implications. *Pediatr Radiol* 2008;38:688–690.
- Costabile RA. How worrisome is testicular microlithiasis? *Curr Opin Urol* 2007;17:419–423.
- Goede J, Hack WWM, van der Voort-Doedens LM, et al. Prevalence of testicular microlithiasis in asymptomatic males 0 to 19 years old. *J Urol* 2009;182:1516–1520.
- Richenberg J, Belfield J, Ramchandani P, et al. Testicular microlithiasis imaging and follow-up: guidelines of the ESUR scrotal subcommittee. *Eur Radiol* 2015;25:323–330.