

# MULTIPLE SEGMENTAL OSTEOTOMIES TO THE KYPHOSIS CORRECTION

Carlos Fernando Pereira da Silva Herrero<sup>1</sup>, Maximiliano Aguiar Porto<sup>1</sup>, Marcello Henrique Nogueira Barbosa<sup>2</sup>, Helton Luiz Aparecido Defino<sup>3</sup>

## ABSTRACT

**Objective:** To evaluate the results of the surgical treatment of the spinal Kyphosis using the Ponte's technique (multiple posterior osteotomies). **Methods:** Ten patients (8 with Scheuermann's kyphosis and 2 with kyphosis after laminectomy) submitted to surgical correction of kyphotic deformity greater than 70° were retrospectively assessed. The age at the surgical time ranged from 12 to 20 years old (mean age 16.8 years ± 2.89). The radiographic parameters evaluated were the kyphosis, the lordosis and the scoliosis – whenever present. The presence of proximal and distal junctional kyphosis, loss of correction, and complications as implants loosening and breakage were also

assessed. The radiographic parameters were evaluated at the preoperative, early postoperative and late postoperative time. **Results:** The patients were followed through a period that ranged from 24 to 144 months (65.8 ± 39.92). The mean value of the kyphosis was 78.8° ± 7.59° (Cobb) before surgery and 47.5° ± 12.54° at late follow up, with mean correction of 33.9° ± 9.53° and lost correction of 2.2°. **Conclusion:** The surgical treatment of the thoracic kyphosis using multiples posterior osteotomies presented a good correction of the deformity and minimal lost of correction during follow up.

**Keywords** – *Kyphosis; Spine; Scheuermann disease; Spinal fusion; Osteotomy*

## INTRODUCTION

The increase of physiological kyphosis or the reduction of lordosis is called hyperkyphosis, can occur throughout the spine, and is most common at the thoracic spine<sup>(1-3)</sup>. The etiology of hyperkyphosis includes several diseases; Scheuermann's disease, and iatrogenic and post-traumatic diseases are especially common<sup>(4-6)</sup>.

The physiological values of thoracic kyphosis vary widely in individuals; normal is considered between 20 and 40 degrees<sup>(7-9)</sup>. In the thoraco-lumbar transition,

kyphosis above 20 degrees is considered pathological. Identification of increased kyphosis may be more difficult due to the compensation mechanism of the proximal or distal segments<sup>(9,10)</sup>.

The conservative treatment of dorsal hyperkyphosis is indicated in patients that are still growing and Scheuermann's disease with angles below 70 degrees<sup>(1,11,12)</sup>. The indication of surgical treatment is independent of etiology. It is indicated in patients with kyphosis above 70 degrees<sup>(10-13)</sup>, accompanied by pain, sagittal imbalance,

1 – Post-graduate Student, Department of Biomechanics, Medicine and Rehabilitation of the Locomotor Apparatus, Hospital das Clínicas, School of Medicine, Ribeirão Preto-USP, Ribeirão Preto, SP, Brazil.

2 – Professor, Radiology Division, Department of Clinical Medicine, School of Medicine, Ribeirão Preto-USP, Ribeirão Preto, SP, Brazil.

3 – Full Professor, Department of Biomechanics, Medicine and Rehabilitation of the Locomotor Apparatus, Hospital das Clínicas, School of Medicine, Ribeirão Preto-USP, Ribeirão Preto, SP, Brazil.

Study conducted at the Hospital das Clínicas, School of Medicine, Ribeirão Preto, Universidade de São Paulo, Department of Biomechanics, Medicine and Rehabilitation of the Locomotor Apparatus, Ribeirão Preto, SP, Brazil.

Correspondence: Helton LA Defino. Av. Bandeirantes, 3.900, 11° and. – 14048-900 – Ribeirão Preto (SP), Brasil. E-mail: hldefin@fmrp.usp.br

We declare no conflict of interest in this article.

cosmetic complaints, or functional disability<sup>(13, 14)</sup>.

Conventional surgical treatment is performed through anterior and posterior approaches, in order to meet the biomechanical requirements to restore the sagittal alignment of the dorsal spine<sup>(15)</sup>. The anterior approach aims to release the structures and perform interbody fusion, while the posterior approach stabilizes and corrects the deformity by shortening its convex surface<sup>(16-19)</sup>. Ponte and Siccardi<sup>(19)</sup>, to avoid the anterior approach and to reduce the morbidity of the surgical procedure, developed the technique of using the posterior approach alone.

The purpose of this paper is to present the clinical and radiological results of using the posterior approach alone for performing multiple-segment osteotomies of the spine for the treatment of dorsal hyperkyphosis.

## METHODS

We evaluated the medical records of 10 patients (seven male and three female) aged between 12 and 20 years (mean 16.8 years  $\pm$  2.89). Eight patients had sequelae of Scheuermann's disease and two had sequelae of dorsal laminectomy for the removal of an intraspinal tumor (pilocytic astrocytoma). The patients' general data are shown in Table 1.

The indication for surgical treatment focused on the degree of deformity and the dissatisfaction with cosmetic appearance. All patients had a dorsal kyphosis angle with a value above 70 degrees. In the preoperative period, patients underwent MRI of the dorsal spinal column to assess the integrity of the spinal canal. The identification of a reduced diameter of the spinal canal due to disc protrusion is a contraindication to performing a posterior correction of dorsal hyperkyphosis<sup>(20)</sup>.

Patients underwent surgical treatment according to the technique for the correction of hyperkyphosis described by Ponte and Siccardi<sup>(19)</sup>. This technique consists of performing multiple osteotomies through bilateral partial resection of the vertebral lamina and joint facet (Figures 1 and 2). The correction and fixation of the affected vertebral segment were made through the use of pedicular fixation systems. We used the USIS-Ulrich system in four patients, composed of 4mm threaded rods, and the USS-Synthes system consisting of a 6mm rigid rod in six patients.

Spinal arthrodesis was performed with an autologous iliac bone graft in four patients, and grafts removed from the surgical site and the spinous processes in six

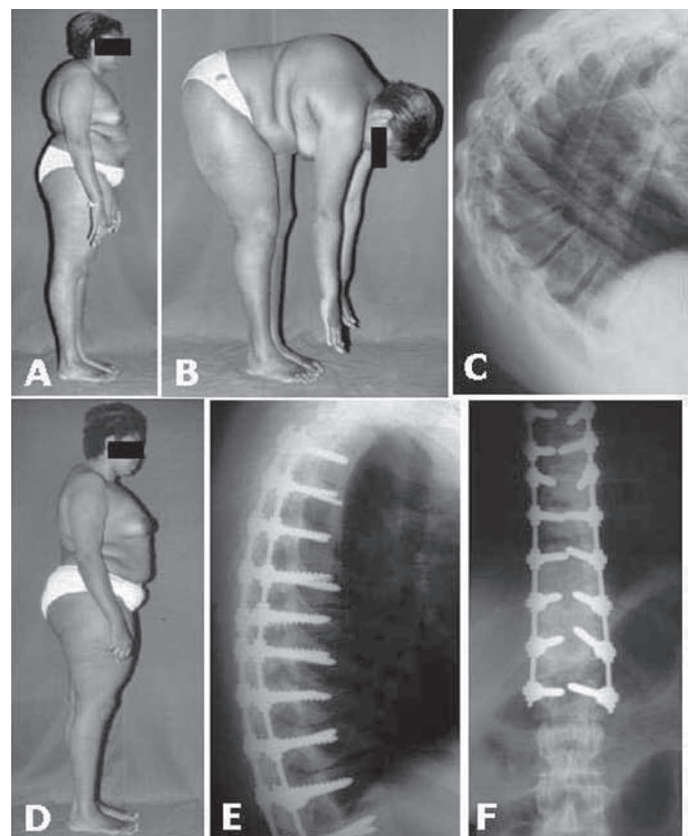
patients. The levels of arthrodesis and vertebral fixation were selected considering the first lordotic vertebra on the distal end and the terminal vertebra in the proximal part.

In the postoperative period, patients did not use a cast or immobilizing splint, and ambulation and resumption of the activities were permitted according to the degree of pain relief.

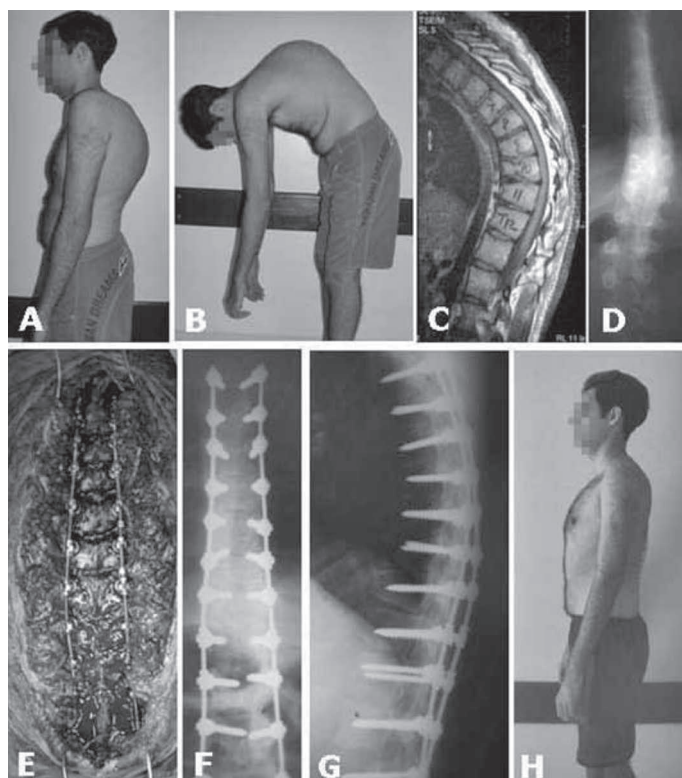
The following were the radiological parameters used in the evaluation of patients: measurement of the kyphosis, lordosis, and when present, scoliosis by the Cobb method; proximal and distal junctional kyphosis, and complications related to the loosening or breakage of the implants. The parameters were evaluated in the preoperative period, immediate postoperative period, and late evaluation. All patients were followed for a minimum period of two years (Table 1).

## RESULTS

The patients were monitored for a period ranging from 24 to 144 months (16.8  $\pm$  39.92 months).



**Figure 1** – Patient No. 7 in Table 1. A and B) Preoperative photographs evidence increased kyphosis. C) Profile radiograph evidences thoracic hyperkyphosis. D) Image showing postoperative correction of kyphosis. E and F) Profile and AP radiographs showing the correction of kyphosis.



**Figure 2** – Patient No. 2 in Table 1. Preoperative clinical (A and B) and radioscopic (C and D) appearance. Intraoperative photograph (E) illustrating the osteotomies. Radiological (F and G) and clinical (H) appearance demonstrating the correction.

Kyphosis ranged from 72° to 96° ( $78.8^\circ \pm 7.59^\circ$ ) preoperatively, 28° to 70° ( $44.9^\circ \pm 12.1^\circ$ ) in the immediate postoperative period and 34° to 72° ( $47.5^\circ \pm 12.54^\circ$ ) in the late evaluation (Figure 3). The correction of kyphosis ranged from 50° to 21° ( $33.9^\circ \pm 9.53^\circ$ ) in the immediate postoperative period and little loss of correction was observed in the late evaluation, with an average of 2.2°. The late percentage of kyphosis correction ranged from 61.1% to 27% ( $43.25\% \pm 12.56\%$ ).

Scoliosis was observed in three patients, ranging from 33° to 22° in the preoperative period, and a 13.3° correction was observed (Figure 4 and 5). The preoperative lordosis ranged from 37° to 104° ( $61.6^\circ \pm 18.46^\circ$ ) and in the late evaluation period, 26° to 74° ( $43.3^\circ \pm 13.88^\circ$ ).

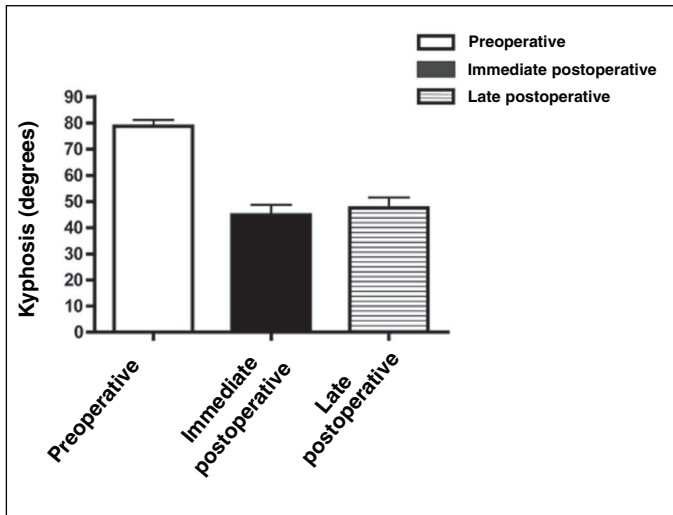
A 35° proximal junctional kyphosis was observed in one patient (No. 1), which had no clinical repercussions. The sequelae of laminectomy presented by the patient was used for resection of pilocytic astrocytoma. Distal junctional kyphosis was not observed in any patient in this study.

Late deep infection of the wound was observed two years after surgery in one patient (No. 5 of Table 1) and was successfully treated by surgical cleaning without

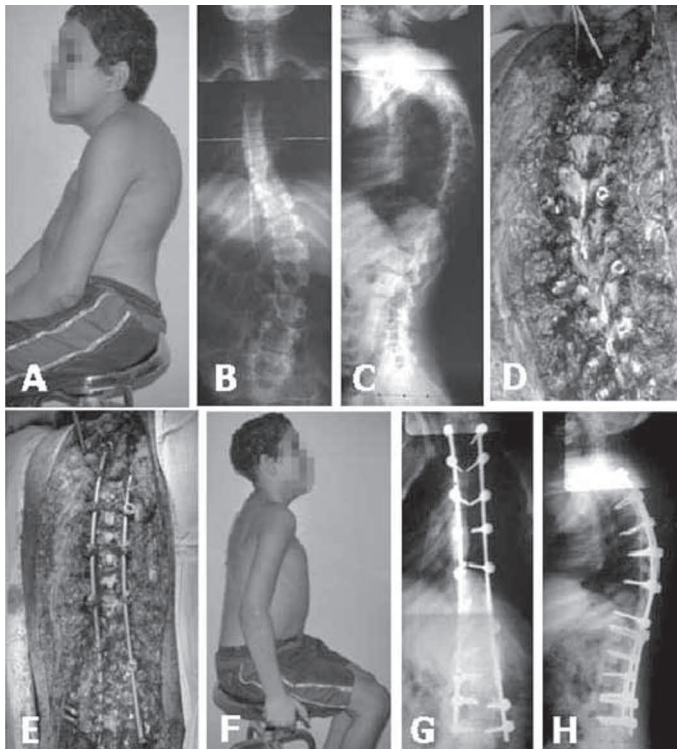
**Table 1** – General patient data.

Patient	Sex	Age	Etiology	Kyphosis			Scoliosis			Lordosis			Kyphosis	Instrumentation	Junctional kyphosis	Material	Cor	Cor %	Follow-up (months)	Complications
				Pre	Ipo	Lpo	Pre	Ipo	Lpo	Pre	Ipo	Lpo								
1	M	14	Sequelae of laminectomy	80°	50°	50°	30°	10°	10°	104°	70°	74°	T4-T11	T4-L3	Yes	USS	30°	37.5	36	No
2	M	18	Scheuermann's disease	72°	28°	34°	-	-	-	37°	30°	30°	T4-T12	T4-L2	No	USIS	44°	61.1	84	No
3	M	12	Sequelae of laminectomy	74°	52°	55°	15°	0	0	64°	40°	42°	T2-T12	T1-L4	No	USS	22°	29.7	36	No
4	F	20	Scheuermann's disease	73°	52°	54°	-	-	-	72°	54°	54°	T5-T12	T3-L3	No	USS	21°	28.7	64	Broken rod
5	M	16	Scheuermann's disease	82°	32°	34°	-	-	-	42°	32°	32°	T3-T12	T3-L2	No	USIS	50°	60.9	144	Infection
6	M	17	Scheuermann's disease	74°	42°	42°	33°	16°	20°	68°	45°	50°	T5-T11	T4-L3	No	USS	32°	43.2	24	No
7	F	19	Scheuermann's disease	73°	35°	37°	-	-	-	58°	35°	38°	T3-T12	T3-L1	No	USIS	38°	52	101	No
8	M	16	Scheuermann's disease	96°	70°	72°	-	-	-	52°	26°	26°	T3-T12	T3-L2	No	USS	26°	27	24	No
9	M	20	Scheuermann's disease	86°	45°	57°	-	-	-	62°	45°	44°	T4-T12	T3-L2	No	USIS	41°	47.6	98	No
10	F	18	Scheuermann's disease	78°	42°	45°	22°	15°	5°	57°	40°	43°	T4-T12	T3-L2	No	USS	35°	44.8	47	No

Legend: M: male, F: female, Pre: preoperative period, Ipo: Immediate postoperative period, Lpo: Late postoperative period, Cor: correction in degrees, Cor %: correction percentage

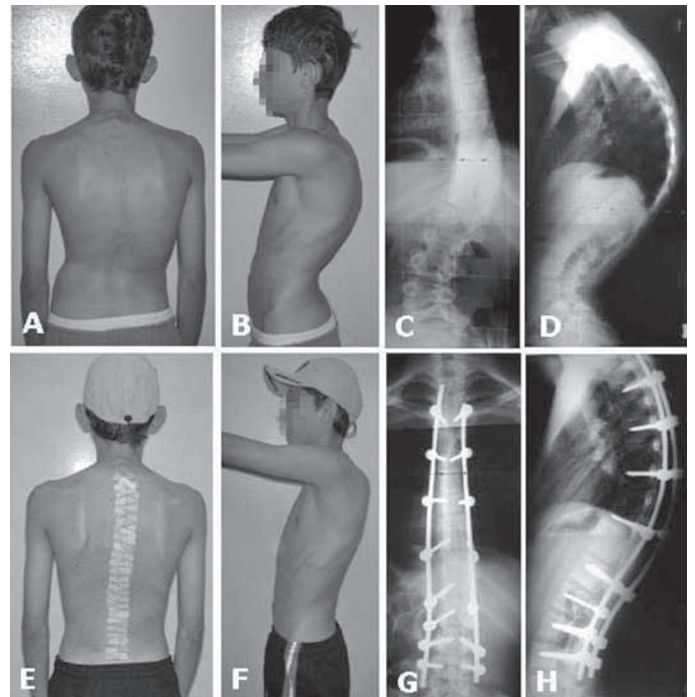


**Figure 3** – Chart showing the mean angular kyphosis values in the preoperative, immediate postoperative, and late postoperative periods.



**Figure 4** – Patient No. 1 in Table 1. Photograph (A) and radiographs (B and C) showing preoperative kyphosis and associated scoliosis. Intraoperative photograph (D and E) illustrating multiple osteotomies and final correction. Clinical (F) and radiographic (G and H) appearance demonstrating the correction of kyphosis.

removing the implants. One patient (No. 4 of Table 1) showed implant breakage and underwent reoperation to exchange the fixation material and complement with bone graft and two foci of pseudoarthrosis were observed intraoperatively.



**Figure 5** – Patient No. 3 in Table 1. Photographs (A and B) and radiographs (C and D) showing increased preoperative kyphosis and the presence of scoliosis. Clinical (E and F) and radiographic (G and H) appearance postoperatively showing the correction of deformities.

## DISCUSSION

The indications for surgical correction of dorsal hyperkyphosis have been designed to correct deformities over 70 degrees, progressive deformities, pain resistant to conservative treatment, or unacceptable cosmetic deformity<sup>(9,10,21)</sup>. These parameters alone or combined guide surgical treatment. There is little controversy regarding surgical indication. The assessment of treatment outcome is complex because pain and cosmetic changes are subjective parameters and are difficult to quantify.

The first surgical reports of this deformity referred to the posterior approach<sup>(22)</sup> with use of the Harrington compression system, which had a high percentage of loss of correction during follow-up<sup>(15,22)</sup>. The dual-access approach, with the anterior associated with the posterior, was recommended to reduce the loss of correction. Due to the improvement of the results, it is still widely used<sup>(16)</sup>.

Ponte and Siccardi<sup>(19)</sup> described the posterior correction technique in isolation with posterior resection of the vertebral elements and shortening of the convexity of the deformity using the compression technique applied to the fixation system. The technique described by Ponte and Siccardi is a modification of the Smith-

Petersen osteotomy, with contact of the the posterior bone surfaces<sup>(19)</sup>.

Since the beginning of the use of the Ponte technique, we have used pedicle fixation at all levels of the spine. In the first cases we used 4-mm threaded rod, and then 6-mm unthreaded rod. However, it should be noted that the Ponte technique used hooks<sup>(19)</sup>. The correction obtained in our series of patients was satisfactory, and is consistent with other reports<sup>(10-29)</sup>. Care should be taken to avoid overcorrection when using this technique.

The comparison between the anterior and posterior correction and the posterior correction alone has been reported in the literature<sup>(10-29)</sup>. Despite the satisfactory correction of the dorsal hyperkyphosis through an isolated posterior approach using the Ponte technique, it is not yet clear whether this technique has the same capacity for the correction of curves when compared with the combined approach<sup>(18,27)</sup>. However, the goal of the correction of deformity in hyperkyphosis is not the absolute correction of the deformity, but to obtain values within the normal range associated with balance in the sagittal plane.

The retention of the correction in late follow-up has been mentioned as another parameter of comparison between the techniques. In the study group, this parameter was satisfactory (mean 33.9°). Several reports have shown a tendency for less loss of correction by using the combined approach<sup>(18,19,27,30)</sup>. This difference, although statistically significant, is represented by small values: 3° and 4° (combined) and 6° (posterior), and must be interpreted with caution. The literature reports a loss of 15° after implant removal<sup>(30)</sup>. The type of posterior instrumentation (pedicle screws, hooks, or hybrid systems) should also be considered in assessing the late loss of correction. In theory, the performance of the combined approach would promote faster consolidation at the apex of the deformity, thereby preserving the correction obtained<sup>(14,31)</sup>.

In this group of patients, lumbar lordosis decreased compared to preoperative values, which is consistent with the literature<sup>(10)</sup>, that has correlated lordosis with the degree of correction of kyphosis<sup>(10,19,32)</sup>, with an increase of its value in the late follow-up<sup>(10,32)</sup>. Postoperative lordosis is affected by the kyphosis obtained after the correction, and thus the compensation mechanism in the sagittal plane could be related to the intrinsic morphology of the pelvis (pelvic incidence),

and also with changes in the alignment and flexibility of the spine imposed by arthrodesis. Preoperative kyphosis has shown no correlation with the pelvic incidence<sup>(10)</sup>.

The percentage of complications has been lower in patients undergoing the posterior approach because thoracotomy is not performed in those cases<sup>(18,27)</sup>. In our series of patients, the complications were in material breakage in one case (No. 4 of Table 1) and wound infection in another (No. 5 of Table 1); both were resolved with surgical treatment.

Junctional kyphosis with clinical repercussion (proximal or distal) did not occur in our group of patients. Only one patient (No. 1 of Table 1) showed an apparent radiographic deformity of 35° in the proximal segment to the instrumentation, but without any complaint of clinical deformity; it was not necessary to perform additional treatment.

The occurrence of junctional kyphosis has been more relevant from a radiological rather than clinical point of view, although some patients have been reoperated in order to solve this problem. The incidence of proximal junctional kyphosis has been correlated with more than 50% correction and short proximal instrumentation, distal to the superior end vertebra<sup>(10)</sup>. In the series study by Lonner et al.<sup>(9)</sup>, the occurrence of proximal junctional kyphosis was related to the magnitude of preoperative deformity and the degree of correction. However, it was not possible to conclude whether this fact indicates the difficulty patients with large curves have with achieving normal sagittal balance without upsetting the segments adjacent to the area of arthrodesis, or whether there was something related to the transitional segmental structures of the arthrodesis area and the instrumentation.

This junctional kyphosis has been associated with the inferior vertebra of the arthrodesis (LIV). The use of stable sagittal vertebra has been recommended as a parameter of the LIV relationship. In our series, the LIV was distal to the stable sagittal vertebra in all cases, preventing the development of distal junctional kyphosis in our patients.

## CONCLUSION

Surgical treatment of dorsal hyperkyphosis using the posterior approach alone with multiple osteotomies and fixation with pedicle screws showed itself to be a good treatment option, reaching values within the physiological parameters and presenting minimal loss of the initial correction during follow-up.

## REFERENCES

1. Hefti F. Morbus Scheuermann - Scheuermanns juvenile kyphosis. *Ther Umsch.* 1987;44(10):764-70.
2. Macagno AE, O'Brien MF. Thoracic and thoracolumbar kyphosis in adults. *Spine. Spine (Phila Pa 1976).* 2006;31(19 Suppl):S161-70.
3. Scheuermann H. Kyfosis dorsalis juvenilis. *Ugeskr Laeger.* 1920;82:385-93.
4. Aufdermaur M, Spycher M. Pathogenesis of osteochondrosis juvenilis Scheuermann. *J Orthop Res.* 1986;4(4):452-7.
5. Blazek O, Streda A, Cermak V, Skalova O. The incidence of morbus Scheuermann in sportsmen. *J Sports Med Phys Fitness.* 1986;26(1):55-9.
6. Griffet J, Bastiani F. Fracture of lomber spine in child simulating Scheuermann disease. *Chir Pediatr.* 1987;28(4-5):259-61.
7. King JC, King JC. Scheuermann's disease: the lumbar variant. *Am J Phys Med Rehabil.* 2004;83(6):467.
8. Lowe TG. Current concepts review - Scheuermann disease. *J Bone Joint Surg Am.* 1990;72(6):940-5.
9. Lonner BS, Newton P, Betz R, Scharf C, O'Brien M, Sponseller P, et al. Operative management of Scheuermann's kyphosis in 78 patients: radiographic outcomes, complications, and technique. *Spine.* 2007;32(24):2644-52.
10. Bradford DS, Moe JH, Montalvo F, Winter RB. Scheuermanns juvenile kyphosis. Experience in 200 patients. *J Bone Joint Surg Am.* 1973;55(6):1323.
11. Bradford DS, Moe JH, Montalvo FJ, Winter RB. Scheuermanns kyphosis and roundback deformity. Results of Milwaukee brace treatment. *J Bone Joint Surg Am.* 1974;56(4):740-58.
12. Krismer M, Behensky H, Frischhut B, Wimmer C, Ogon M. Operative treatment of idiopathic scoliosis and juvenile kyphosis. *Orthopade.* 2002;31(1):26-33.
13. Winter R. The Treatment of spinal kyphosis. *Int Orthop.* 1991;15(3):265-71.
14. Arlet V, Schlenzka D. Scheuermann's kyphosis: surgical management. *Eur Spine J.* 2005;14(9):817-27.
15. Arlet V. Anterior thoracoscopic spine release in deformity surgery: a meta-analysis and review. *Eur Spine J.* 2000;9(Suppl 1):S17-23.
16. Berven SH, Deviren V, Smith JA, Hu SH, Bradford DS. Management of fixed sagittal plane deformity: outcome of combined anterior and posterior surgery. *Spine (Phila Pa 1976).* 2003;28(15):1710-5.
17. Lee SS, Lenke LG, Kuklo TR, Valente L, Bridwell KH, Sides B, et al. Comparison of Scheuermann kyphosis correction by posterior-only thoracic pedicle screw fixation versus combined anterior/posterior fusion. *Spine (Phila Pa 1976).* 2006;31(20):2316-21.
18. Macedo RD, Fim M, Fontes BPC. Parafusos pediculares no tratamento da cifose de Scheuermann: resultados e complicações. *Rev Bras Ortop.* 2008;43(1/2):23-30.
19. Ponte A, Siccardi GL, Ligure P. Posterior shortening procedure by segmental closing wedge resections [Abstract]. *J Pediatr Orthop.* 1995;15:404
20. Webb JK. Comment to "Clinical outcome and radiographic results after operative treatment of Scheuermann's disease", by R. W. Poolman et al. *Eur Spine J.* 2002;11(6):570.
21. Bradford DS, Moe JH, Montalvo FJ, Winter RB. Scheuermanns kyphosis. Results of surgical treatment by posterior spine arthrodesis in 22 patients. *J Bone Joint Surg Am.* 1975;57(4):439-48.
22. Gaines RW. Reconstrução curta para tratamento da escoliose idiopática do adolescente e doença de Scheuermann baseada na discectomia total. *Coluna/Columna.* 2005;4(3):113-68.
23. Herndon WA, Emans JB, Micheli LJ, Hall JE. Combined anterior and posterior fusion for Scheuermann kyphosis. *Spine (Phila Pa 1976).* 1981;6(2):125-30.
24. de Jonge T, Illes T, Belyei A. Surgical correction of Scheuermann's kyphosis. *Int Orthop.* 2001;25(2):70-3.
25. Gertzbein SD, Harris MB. Wedge osteotomy for the correction of posttraumatic kyphosis. A new technique and a report of 3 cases. *Spine (Phila Pa 1976).* 1992;17(3):374-9.
26. Johnston CE, Elerson E, Dagher G. Correction of adolescent hyperkyphosis with posterior-only threaded rod compression instrumentation: Is anterior spinal fusion still necessary? *Spine (Phila Pa 1976).* 2005;30(13):1528-34.
27. Lehmer SM, Keppler L, Biscup RS, Enker P, Miller SD, Steffee AD. Posterior transvertebral osteotomy for adult thoracolumbar kyphosis. *Spine (Phila Pa 1976).* 1994;19(18):2060-7.
28. Saraph VJ, Bach CM, Krismer M, Wimmer C. Evaluation of spinal fusion using autologous anterior strut grafts and posterior instrumentation for thoracic/thoracolumbar kyphosis. *Spine (Phila Pa 1976).* 2005;30(14):1594-601.
29. Poolman RW, Been HD, Ubags LH. Clinical outcome and radiographic results after operative treatment of Scheuermann's disease. *Eur Spine J.* 2002;11(6):561-9.
30. Hosman AJF. Letter to the Editor regarding "Scheuermann's kyphosis: surgical management" (V. Arlet, D. Schlenzka). *Eur Spine J.* 2006;15(9):1411-2.
31. Papagelopoulos PJ, Klassen RA, Peterson HA, Dekutoski MB. Surgical treatment of Scheuermann's disease with segmental compression instrumentation. *Clin Orthop Relat Res.* 2001;(386):139-49.
32. Lim M, Green DW, Billingham JE, Huang RC, Rawlins BA, Widmann RF, et al. Scheuermann kyphosis: safe and effective surgical treatment using multisegmental instrumentation. *Spine (Phila Pa 1976).* 2004;29(16):1789-94.