

A novel bio envelope and suture orientation for stabilization of the subcutaneous implantable cardioverter-defibrillator generator to the chest wall



Kun Xiang, MD, PhD, Joshua D. Levine, MD, S. Claude Elayi, MD, FHRS,
Jialin Su, MD, PhD, Steve Hsu, MD, FHRS, Robert Kim, MD, John N. Catanzaro, MD, FHRS

From the University of Florida Health Science Center, Jacksonville, Florida.

Introduction

An implantable cardioverter-defibrillator (ICD) is the first-line treatment and prophylactic therapy for patients at risk for life-threatening ventricular arrhythmias. The traditional transvenous implantable cardiac defibrillator (TV-ICD) is associated with potential for several uncommon but serious complications.¹ The subcutaneous implantable cardiac defibrillator (SICD) was developed in the early 2000s to overcome disadvantages of the TV-ICD system while also providing comparable efficacy in detection and treatment of malignant ventricular tachyarrhythmias.² Given that SICDs are implanted extravascularly outside of the thoracic cage, electing to implant a SICD in lieu of a traditional TV-ICD can obviate the risk of bloodstream infection, venous stenosis, and pneumothorax.^{2–5} However, an SICD also has its inherent limitations, particularly high defibrillation threshold (DFT) and inability to deliver antitachycardia pacing. The SICD DFT is influenced by variables related to patient anatomy, plane and orientation of the generator, and coil position.⁶ Failure to defibrillate may be remedied with generator repositioning combined with a novel bio envelope and anchoring strategy.

We report a clinical case of a migrated SICD generator in a morbidly obese patient. The SICD was reanchored with a novel extracellular matrix (ECM), CanGaroo Bio Envelope (Aziyo Biologics, Silver Spring, MD), and subsequently we were able to achieve an acceptable DFT. Our case highlighted a new generator anchoring strategy

to improve the SICD implantation and DFT success in a patient with challenging body habitus.

Case report

A 44-year-old woman with morbid obesity (body mass index [BMI] 41 kg/m²) underwent SICD implantation at an outside hospital after a resuscitated sudden cardiac death due to polymorphic ventricular tachycardia. At the implantation she had a successful DFT with a reported high impedance of 130 ohms at 65 J. The patient was subsequently discharged, and in the interim she developed severe pain at the SICD generator site. Upon evaluation at our hospital, the SICD generator was found to have migrated from its initial position along the left ribcage, having tilted anteriorly away from the ribs ([Figure 1](#)). After shared decision making and planning, we decided to attempt a novel approach for the pocket revision to stabilize the pulse generator.

In the electrophysiology lab, the lateral thoracic incision was reopened. The device was found to be angled oblique to the ribcage and could not be positioned back into a stable position. A dense fibro-capsule that had already begun to form was debrided. Additional anchoring sutures were placed through the 2 anterior pulse generator suture holes, which did not help maintain a stable generator position. The device was then inserted into an ECM CanGaroo envelope ([Figure 2](#)). Sutures were placed through the 2 suture holes, the envelope, and the fascia anterior and posterior to the SICD to wrap around the device ([Figure 3](#)). Fluoroscopy suggested a large amount of submuscular adipose tissue—the device remained 40 mm away from the ribs—but the device was now able to rest parallel to the ribcage. DFT was subsequently successful within the recommended device operating parameters: 65 J, with an impedance of 90 ohms. In follow-up, the patient experienced much less discomfort at the generator site and had not experienced ICD shocks. After repositioning, primary sensing QRST vector was primary configuration as opposed to secondary. Postrevision follow-up chest radiograph confirmed parallel position of the SICD generator to the ribcage ([Supplemental Figure 1](#)).

KEYWORDS Bio Envelope; Extracellular matrix; Generator; Implantable cardioverter-defibrillator; Novel; Subcutaneous implantable cardioverter-defibrillator; Suture orientation
(Heart Rhythm Case Reports 2019;5:430–432)

Dr Catanzaro is a consultant for and has received honoraria from Aziyo Biologics. All other authors have no conflicts of interest. **Address reprint requests and correspondence:** Dr John N. Catanzaro, Department of Cardiology, Division of Electrophysiology, University of Florida Health Science Center ACC Building, 5th Flr, Jacksonville, FL 32204. E-mail address: jncatanzaro@yahoo.com.

KEY TEACHING POINTS

- The defibrillation threshold in the subcutaneous implantable cardioverter-defibrillator (SICD) is influenced by variables related to patient anatomy, plane, orientation of the generator, and coil position.
- Failure to attain stabilization of the SICD generator to the chest wall can result in an elevated shock impedance, a change in defibrillation threshold, and change in QRST sensing vector.
- A novel biodegradable bio envelope and suture orientation can be used to effectively stabilize the SICD generator to the chest wall and promote tissue regeneration.

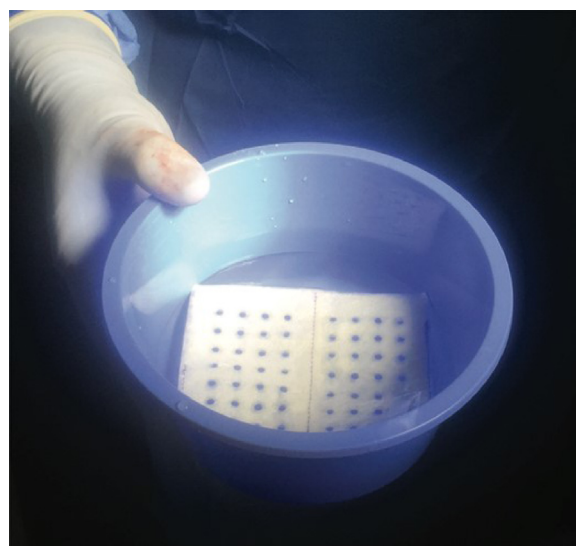


Figure 2 Made from porcine-derived extracellular matrix, the CanGaroo envelope (Aziyo Biologics, Silver Spring, MD) is a naturally occurring bio-scaffold designed to reduce device migration and enhance patient comfort.

Discussion

Implantation of an SICD can overcome the disadvantages of TV-ICD by avoiding the necessity for intravascular access and has clear advantage in select patient groups.^{2,3} The use of SICD in morbidly obese patients is limited by technical challenges of the implant, which could affect DFT. Clinical studies have shown that morbid obesity (BMI ≥ 35 kg/m²), higher body surface area, and increased myocardial septal and posterior wall thickness predict higher DFT.⁷ In our case, the migrated SICD generator led to an unusual vector with elevated impedance, consistent with substantial fat tissue and fibrous capsule between the generator and parasternal lead. Sta-

bilizing the generator against the ribcage yielded adequate DFT, illustrating the importance of defibrillation vector.

An optimal ICD system should be able to successfully defibrillate a patient with the least amount of energy over a short interval (~ 10 ms) to preserve battery life and device longevity. Variables that govern this relationship are the capacitance of the generator and the resistance over the path of electrical current. This resistance is the tissue impedance between anode and cathode of the ICD, measured in ohms.⁸ Anatomic variables that influence impedance through the thoracic cage include adiposity, the distance between the anode and cathode, the character and types of tissues between the generator and coil, and the vector through which the electrical wave propagates.¹ This is the reason for concern of elevated DFT in severely obese patients. Given that the SICD shocking coil is implanted superficial to the sternum, there is more distance between the coil and the left ventricular myocardium compared to TV-ICD coils. As such, SICD systems require much higher energy compared to TV-ICDs.^{2,5,6} With our new anchoring strategy, we repositioned and sutured the generator using the Bio Envelope onto the latissimus muscle in the formation where the generator tilted posteriorly and not anteriorly. This bolsters the envelope against the muscle, essentially preventing an anterior migration of the device, which helps to preserve DFT vector over time.⁶ This is particularly beneficial for patients with high BMI because even a few millimeters of substernal fat can exponentially increase the shock impedance and the energy required for successful defibrillation.

An additional benefit of the CanGaroo envelope is a possible reduction in the incidence of infection.⁹ There have been reports of slightly increased infection risk with implantation of SICD (4%) compared with a TV-ICD (2.2%) in the EFFORTLESS trial,¹⁰ even though the risk of progression to systemic infection and

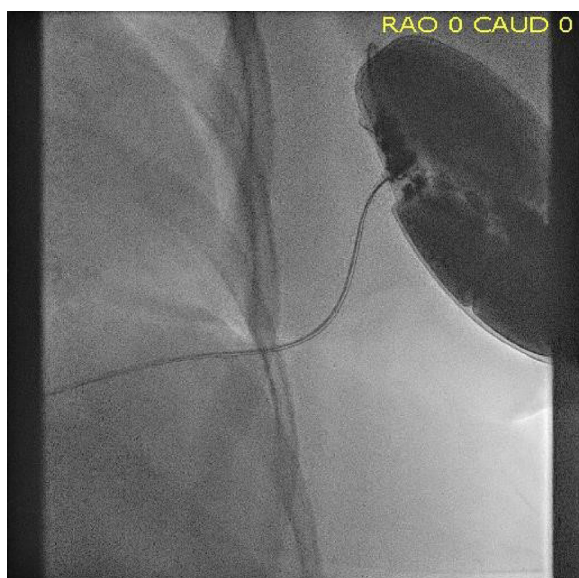


Figure 1 Preincision supine fluoroscopy showed the device tilted away from the ribs at left chest wall, leading to changed defibrillation vector and high shock impedance.

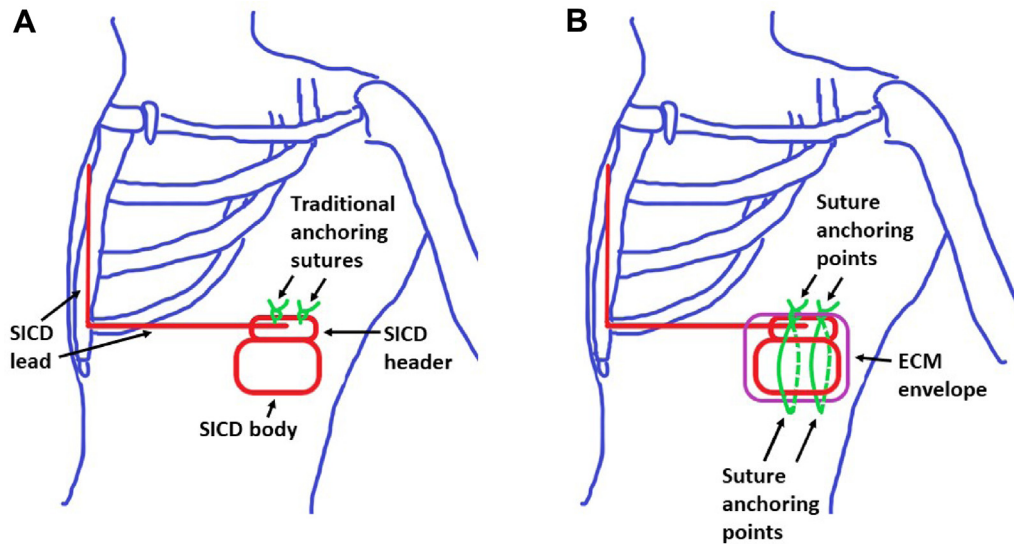


Figure 3 Nonresorbable sutures were placed into the muscular layer through the subcutaneous implantable cardioverter-defibrillator (SICD) header and the extracellular matrix (ECM) envelope. Sutures were then wrapped around the outside of the envelope and were anchored again inferior to the device, pinning the inferior part of the envelope to the muscle layer. Compared to the traditional method (A) that anchored the device at 2 points at the upper part of the pocket, the new approach (B) anchored the device at 4 points, both at the upper and lower part of the pocket, with the suture line wrapped around the device to increase stability against the ribcage.

endocarditis is much less for SICDs compared to TV-ICDs.⁵ The CanGaroo ECM Envelope is derived from the decellularized submucosa of pig intestine. Once the ECM is implanted into the tissue, the inflammatory cascade is prevented from activation. The body recognizes scaffold as its own and undergoes a type II macrophage response. Tissue can grow in and around the ECM, reducing the amount of calcium and thick fibrous tissue in the defibrillator capsule. The difference in tissue quality would result in a chronically more conductive medium around the generator with vascularity secondary to promotion of angiogenesis around the capsule.¹¹ The approximate time of biodegradation of the ECM is 2–4 weeks based on BMI. The absorbable synthetic antibacterial envelope has been used for device implantation in patients with high infection risks.¹¹ Based on our knowledge, this is the first report of the use of an ECM in an SICD to stabilize the generator optimizing DFTs at implant utilizing a particular suture orientation. This may have future research implications, specifically in patients at time of generator change and/or increase in DFTs secondary to obesity or antiarrhythmic pharmacotherapy (amiodarone). In addition, properties of the ECM may also reduce the risk of pocket infection through promotion of natural angiogenesis and resistance to calcification.

Conclusion

Large SICD pockets may allow the generator to shift within the soft tissue, resulting in an unfavorable DFT vector. This can be corrected by anchoring the device within a bio envelope to the fascia with multiple sutures.

Appendix Supplementary data

Supplementary data associated with this article can be found in the online version at <https://doi.org/10.1016/j.hrcr.2019.05.003>.

References

- Ezzat VA, Lee V, Ahsan S, et al. A systematic review of ICD complications in randomized controlled trials versus registries: is our 'real-world' data an understatement? *Open Heart* 2015;2:e000198.
- Bardy GH, Smith WM, Hood MA, et al. An entirely subcutaneous implantable cardioverter-defibrillator. *N Engl J Med* 2010;363:36–44.
- Cuoco FA, Gold MR. Subcutaneous and epicardial defibrillators. In: Ellenbogen KA, Wilkoff BL, Kay GN, Lau C-P, Auricchio A, eds. *Clinical Cardiac Pacing, Defibrillation and Resynchronization Therapy*, 5th ed. Atlanta, GA: Elsevier; 2017:482–489.
- Grace A, Bardy GH. Subcutaneous implantable cardioverter defibrillators. In: Zipes DP, Jalife J, Stevenson WG, eds. *Cardiac Electrophysiology: From Cell to Bedside*, 7th ed. Atlanta, GA: Elsevier; 2018:1130–1138.
- Lewis GF, Gold MR. Safety and efficacy of the subcutaneous implantable defibrillator. *J Am Coll Cardiol* 2016;67:445–454.
- Heist EK, Belalcazar A, Stahl W, Brouwer TF, Knops RE. Determinants of subcutaneous implantable cardioverter-defibrillator efficacy: a computer modeling study. *JACC Clin Electrophysiol* 2017;3:405–414.
- Do K, Chang P, Konecny T, et al. Predictors of elevated defibrillation threshold with the subcutaneous implantable cardioverter-defibrillator. *J Innov Card Rhythm Manag* 2017;8:2920–2929.
- Untereker DF, Schmidt CI, Jain G, Tamirisa PA, Hossick-Schott J, Viste M. Power sources and capacitors for pacemakers and implantable cardioverter-defibrillators A2 - Ellenbogen, Kenneth A. In: Wilkoff BL, Kay GN, Lau C-P, Auricchio A, eds. *Clinical Cardiac Pacing, Defibrillation and Resynchronization Therapy*, 5th ed. Atlanta, GA: Elsevier; 2017:251–269.
- Deering TF, Chang C, Snyder C, Natarajan SK, Matheny R. Enhanced antimicrobial effects of decellularized extracellular matrix (CorMatrix) with added vancomycin and gentamicin for device implant protection. *Pacing Clin Electrophysiol* 2017;40:615–623.
- Lambiase PD, Barr C, Theuns DA, et al. Worldwide experience with a totally subcutaneous implantable defibrillator: early results from the EFFORTLESS S-ICD Registry. *Eur Heart J* 2014;35:1657–1665.
- Kondo Y, Ueda M, Kobayashi Y, Schwab JO. New horizon for infection prevention technology and implantable device. *J Arrhythm* 2016;32:297–302.