

Successful Treatment of Dystrophic Nails Caused by Onychotillomania Using Pulsed Dye Laser 595 nm: A Case Report

Anon Paichitrojjana 

School of Anti-Aging and Regenerative Medicine, Mae Fah Luang University, Bangkok, Thailand

Correspondence: Anon Paichitrojjana, School of Anti-Aging and Regenerative Medicine, Mae Fah Luang University 36/87-88 PS Tower 25FI, Asoke Road, Sukhumvit 21, Klong Toey Nua, Wattana, Bangkok, 10110, Thailand, Tel +66-81-9343050, Email anonpaic@gmail.com

Abstract: Onychotillomania is characterized by an irresistible urge to pick or pull at one's nails, resulting in significant damage to the nail and surrounding tissue. In severe cases, it can cause onychodystrophy, which leads to abnormal changes in nail shape, color, texture, and growth. Managing onychotillomania can be challenging due to the lack of standard treatment and concurrent behavioral disorders. Pharmacotherapy and behavioral therapy have shown some positive outcomes from reported cases. The treatment for onychodystrophy varies depending on the underlying cause and may entail the application of topical, systemic, or laser therapies. Nevertheless, there is currently no consensus on the most effective treatment approach. This report presents a case of onychodystrophy caused by onychotillomania successfully treated using a pulsed dye laser 595 nm. The treatment was administered four times, with a two-week interval between sessions. Significant improvement was seen within four weeks of starting the treatment, and by the end of the eight-week program, the dystrophic thumbnails had almost completely resolved. After a thorough ten-month follow-up, it has been determined that the dystrophic nails have not reappeared. Moreover, there has been a significant decrease in the patient's tendency to pull her nails.

Plain Language Summary: Current treatment modalities of onychodystrophy will vary depending on the underlying cause of this condition, including topical, systemic, and laser treatment. Unfortunately, no universally accepted treatment has proven the most effective. This report presents a successful treatment for dystrophic nails caused by onychotillomania using the pulsed dye laser with a wavelength of 595 nm. The patient's dystrophic nails did not return, and the nail-pulling habit decreased at ten months of follow-up.

Keywords: onychodystrophy, nail dystrophy, onychotillomania, pulsed dye laser, laser treatment

Introduction

Onychotillomania is a condition in which patients have a compulsive or irresistible urge to pick or pull at their nail unit constantly. This term derives from the Greek words onycho (nail), tillo (to pull), and mania (madness). The habit of nail picking typically develops at around 10.2 years of age, with a range of 6 to 18 years old. It is more common in females, and patients typically use their fingers to pick at their nails, sometimes using tools like scissors or toothpicks.¹ It should not be confused with onychophagia, which involves biting or chewing nails. Other related nail behavioral disorders include onychotemnomania, where individuals cut their nails excessively short, and onychoteiromania, where individuals rub their nails excessively until they become very thin.^{2,3} Onychotillomania can be seen in psychologically normal children and may be linked to anxiety. In more severe cases, it could indicate the presence of obsessive-compulsive disorders. According to the ICD-10 classification, onychotillomania is an obsessive-compulsive and related disorder like trichotillomania.⁴ Onychotillomania has an estimated prevalence rate of 0.9%. However, many cases of this condition are believed to go unreported.^{5,6}

Diagnosing onychotillomania can be a challenge. The clinical presentation includes various nonspecific findings, such as bizarre nail plate shape, discoloration, and damage on the nail bed and periungual skin. The histopathological changes are also nonspecific, but they can be compared to the conditions of lichen simplex chronicus. These can make it difficult to differentiate from other inflammatory conditions like chronic periungual dermatitis, acrodermatitis of Hallopeau, and lichen planus.³ Obtaining a clinical history is crucial for arriving at this diagnosis.⁷

Dealing with onychotillomania can be difficult due to the absence of standardized methods, and concurrent behavioral disorders further complicate the situation. According to case reports, pharmacotherapy and behavior therapy have shown some positive results. In severe cases of onychotillomania, onychodystrophy may occur, resulting in abnormal changes in the shape, color, texture, and growth of nails. Furthermore, there is a risk of onychoa trophy due to permanent scarring of the nail matrix.³ The treatment for onychodystrophy differs based on its underlying cause and can involve various methods such as topical, systemic, or laser therapies. There is yet to be a consensus regarding the most effective treatment approach. This is the first case report successfully treating onychodystrophy resulting from onychotillomania using pulsed dye laser (PDL) 595 nm.

Case Report

A 14-year-old girl and her mother visited the dermatology clinic to express concern about her damaged and unsightly thumbnails. She has been suffering from these problems for more than one year, which has caused her insecurity and social issues. The patient's mother reported that her daughter frequently picked up and pulled at her nails. The patient admitted that she habitually picks and pulls at her nails while studying or reading a book despite not experiencing itching or other symptoms. She is aware of this behavior and made several attempts to stop this habit. No notable findings were discovered after reviewing her past medical history. The patient and her family had no history of obsessive-compulsive disorder, depression, or other psychotic illnesses. During the dermatologic examination, it was observed that both thumbnails showed signs of nail dystrophy, including discoloration, loss of cuticles, abnormal shape, depressions in the middle of the nail plate, and thick, flaky scales on the surface. (Figure 1).

There are no other visible signs or clinical symptoms of psycho-dermatoses, such as compulsive skin picking or trichotillomania. The KOH examination of thumbnails and the surrounding skin yielded negative results for fungi. A comprehensive review of history and physical assessment concluded that the patient had dystrophic nails caused by onychotillomania and periungual dermatitis. Despite knowing the causes of this issue, the patient and her mother refused to take the prescribed medication orally or consult with a psychiatrist. The dermatologist prescribed topical triamcinolone 0.1% to treat periungual dermatitis and advised the patient to temporarily cover their thumbnails with tape. This will protect the nails from getting pulled and aid in the healing process.

After three months of trying to alter the behavior, the patient's mother noted some improvement in her daughter's nail-pulling habits. However, the dystrophic thumbnails persist without any noticeable improvement. The patient was looking for an alternative treatment that would be more effective. This time the patient underwent treatment for her

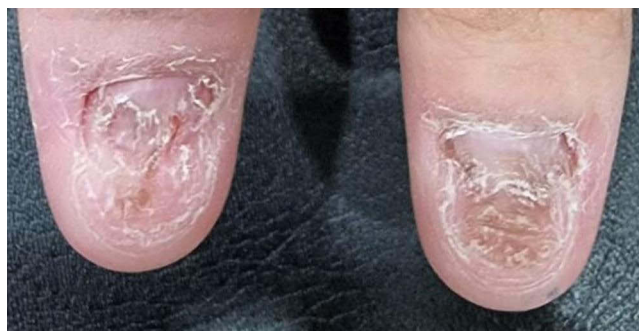

Figure 1 Both thumbnails showed signs of nail dystrophy, including discoloration, loss of cuticles, abnormal shape, depressions in the middle of the nail plate, and thick, flaky scales on the surface.

dystrophic thumbnails with the pulsed dye laser (PDL) 595 nm (Candela Corp., V beam Perfecta[®]). Four PDL treatments were administered at a two-week interval between each session. The laser was set to emit a pulse with 10 ms pulse duration, 7 mm beam diameter, and 7–8.0 J/cm² energy. The laser irradiation covered the entire nail unit, including the proximal nail fold, lunula area, nail plate, lateral nail fold, and hyponychium, with a 50% overlap for optimal results. The laser procedure was tolerable for the patient, causing only mild pain without any other adverse reactions. Throughout the treatment process, the patient and her mother were highly satisfied with the clinical progress achieved through laser treatment (Figures 2 and 3).

After undergoing three PDL treatments, the previously dystrophic thumbnails showed significant improvement. However, it has been noticed that there are some signs of onychotillomania, which include the presence of tiny erosions and bloody crusts on the proximal nail folds. This could suggest that the patient still occasionally pulls at her nails (Figure 4). In order to prevent further damage, the patient was advised to temporarily apply bandages to her thumbnails and keep her nails short.

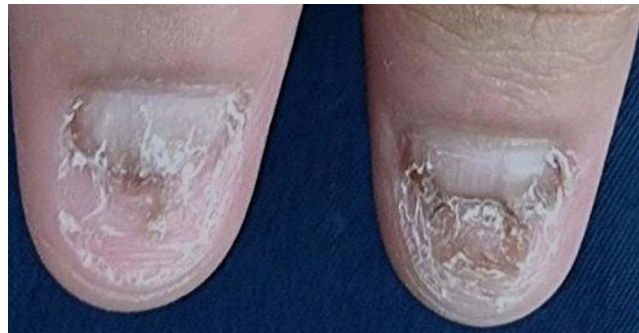

Figure 2 After receiving one PDL treatment, remarkable improvements in the appearance of the nail plate, nail bed, and surrounding skin can be noticed.

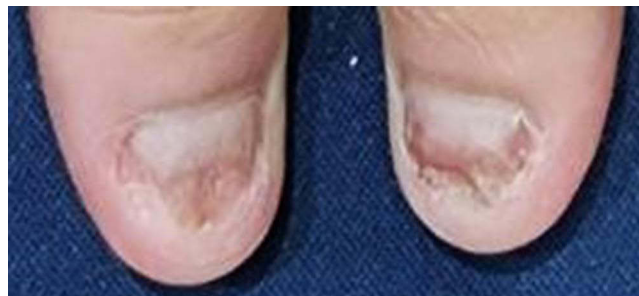

Figure 3 Following two PDL treatments, a significant and sustained improvement has been observed in both thumbnails and periungual skin.

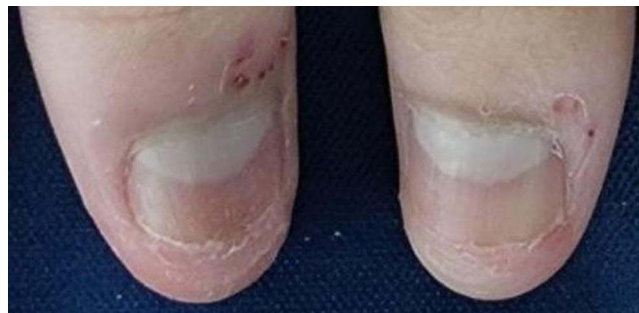

Figure 4 After undergoing three PDL treatments, the previously dystrophic thumbnails have tremendously improved. However, signs of onychotillomania were noticed, including small erosions with bloody crusts on the proximal nail folds.

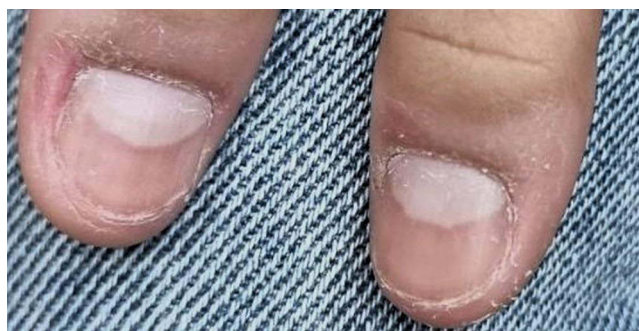


Figure 5 At the ten-month follow-up after completing four PDL treatments, the previously dystrophic thumbnails had been entirely resolved and did not reappear.

After ten months of follow-up, it was noticed that the dystrophic nails did not reappear. Additionally, the patient's habit of pulling her nails has significantly reduced. Although there are still some small scaly patches on the proximal nail fold and periungual skin, the indicators of onychotillomania are less noticeable than they were previously. (Figure 5).

Discussion

Determining the exact occurrence of onychotillomania is difficult due to its likelihood of being unreported and under-diagnosed. Onychotillomania is often discovered as an incidental finding during routine nail examinations and usually does not pose the primary concern for patients. Like the patient in this report, she came to our dermatology clinic primarily because of her nail deformity. Based on this patient's clinical history and specific nail changes examined, the diagnosis of dystrophic nails caused by onychotillomania was made.

Coping with onychotillomania is challenging since it often reoccurs even with the help of pharmacological and psychological interventions. Limited research exists on effective medication due to the absence of large randomized controlled studies. Certain psychotropic medications have effectively treated nail picking in patients with co-occurring psychiatric conditions like depression, OCD, or psychosis. These include SSRIs, TCAs, sertraline, Amitriptyline, thioridazine, and pimozide.^{8–10} Combining monthly intramatrix injections of triamcinolone acetonide with daily topical application of calcipotriol/betamethasone can effectively enhance the appearance of nails within eight months.¹¹ Nonpharmacological treatment has been reported in one patient with a significant decrease in nail-picking frequency after stimulus control and habit reversal training treatment.¹²

Onychodystrophy is distinguished by irregular alterations in the shape, color, texture, and growth of nails. The appropriate treatment for onychodystrophy will vary depending on the underlying cause, such as congenital nail disorders, skin diseases, infection, tumors, idiopathic, and drug reactions.^{13,14} There are several treatments available for this condition, which include using topical steroids, topical tacrolimus, injecting triamcinolone acetonide matrix, taking oral alitretinoin or cyclosporin, and undergoing psoralen combined with ultraviolet A (PUVA) therapy. Specific laser therapies, such as the fractionated carbon dioxide laser, 1064 nm quasi-long pulsed Nd: YAG laser, and 1064 nm picosecond Nd: YAG laser, have been reported successful in treating onychodystrophy that does not respond to conventional treatment methods.^{15–19} The complete understanding of the mechanism behind these laser treatments remains to be discovered. According to previous reports, lasers may function through photothermal effects that rejuvenate collagen, decrease inflammatory cytokines, and cause microscopic damage that enhances blood flow.¹⁵ Nevertheless, no therapy for onychodystrophy has been consistently effective enough to become the standard of excellence.

This patient's primary concern during her visit to the doctor is her nail deformity. To address this issue, the strategy involves treating significant nail dystrophy using a similar approach for inflammatory nail disorders such as nail lichen planus and psoriasis. PDL was selected as an appropriate treatment option in this case because it has been documented as a practical solution for dystrophic nails associated with psoriasis.^{20,21} Possible PDL action mechanism in psoriatic nails, including selectively eliminating abnormal vasculature and reducing inflammation by decreasing the T-lymphocyte count on the skin.²¹

In this case, PDL with a pulse duration of 10 ms and energy of 7–8.0 J/cm² is utilized for treating dystrophic nails. This pulse duration is longer than the pulse durations used in previous studies for treating psoriatic nails, which were either 6 ms or 0.45 ms.²² The patient tolerated this parameter well and did not require local anesthesia. No adverse reactions, such as petechiae or hyperpigmentation, were observed throughout the treatment. Surprisingly, the dystrophic nails have almost fully regained their normal appearance within two months, even though the nail plate typically takes six months to develop from the matrix to the hyponychium.²³ There are several possible explanations for the rapid growth of the patient's nails. For instance, younger people usually have a quicker nail growth rate. Repeated nail injuries can also lead to an accelerated growth rate by improving the circulation in the nail bed.²⁴ Additionally, PDL treatment may play an important role in stimulating nail growth.

Although the exact mechanism of PDL is not yet fully understood, it is hypothesized that the reduction of inflammation resulting from onychotillomania and the stimulation of collagen synthesis within the nail apparatus plays a significant impact. Moreover, the dramatic response from laser therapy can yield a remarkable improvement in a patient's confidence, making her more aware of the importance of self-control in avoiding nail-pulling. This scenario was demonstrated in this patient.

After ten months of monitoring, it has been confirmed that the dystrophic nails have not reappeared. Furthermore, the patient's urge to pull her nails has significantly reduced.

Conclusion

In summary, this report exhibited a case of onychodystrophy caused by onychotillomania that could be effectively treated with PDL 595 nm, resulting in almost complete resolution within two months. This laser treatment was well tolerated and had potential as a new therapeutic option. It is crucial to note that while this case report highlights a successful new treatment, it is based on a single patient only. Therefore, conducting further research into the action mechanism of PDL and performing case-controlled studies are necessary to establish its effectiveness conclusively.

Data Sharing Statement

All data generated or analyzed during this study are included in this article. Further inquiries can be directed to the corresponding author.

Statement of Ethics

The author states that the patient and her mother gave written informed consent for the treatment and the case to be published (including publication of images). This research complies with all Ethical Guidelines for human studies in accordance with the World Medical Association Declaration of Helsinki. This paper is exempt from The Mae Fah Luang Ethics Committee on Human Research approval with a reference number; COE 139/2023. Since it is a case report with at most 3 cases, the report is derived from a review of medical records and can only be linked to an individual if the patient's written consent is obtained.

Funding

This study did not receive any funding.

Disclosure

The author declares no conflicts of interest in this work.

References

1. Grzesiak M, Pacan P, Reich A, et al. Onychotillomania in the course of depression: a case report. *Acta Derm Venereol*. 2014;94(6):745–746. doi:10.2340/00015555-1805
2. Halteh P, Scher RK, Lipner SR. Onychotillomania: diagnosis and Management. *Am J Clin Dermatol*. 2017;18(6):763–770. doi:10.1007/s40257-017-0289-6
3. Singal A, Daulatabad D. Nail tic disorders: manifestations, pathogenesis and management. *Indian J Dermatol Venereol Leprol*. 2017;83(1):19–26. doi:10.4103/0378-6323.184202

4. Sidiropoulou P, Sgouros D, Theodoropoulos K, et al. Onychotillomania: a chameleon-like disorder: case report and review of literature. *Skin Appendage Disord*. 2019;5(2):104–107. doi:10.1159/000489941
5. Hardwaj A, Agarwal S, Koolwal A, et al. Onychotillomania as manifestation for underlying depressive disorder. *Indian J Psychiatry*. 2016;58(1):98–99. doi:10.4103/0019-5545.174398
6. Pacan P, Grzesiak M, Reich A, et al. Onychophagia and onychotillomania: prevalence, clinical picture and comorbidities. *Acta Derm Venereol*. 2014;94(1):67–71. doi:10.2340/00015555-1616
7. Rieder EA, Tosti A. Onychotillomania: an underrecognized disorder. *J Am Acad Dermatol*. 2016;75(6):1245–1250. doi:10.1016/j.jaad.2016.05.036
8. Lee DK, Lipner SR. Update on diagnosis and management of onychophagia and onychotillomania. *Int J Environ Res Public Health*. 2022;19(6):3392. doi:10.3390/ijerph19063392
9. Ameen Sait M, Reddy BS, Garg BR. Onychotillomania. 2 case reports. *Dermatologica*. 1985;171(3):200–202.
10. Hamann K. Onychotillomania treated with pimozide (Orap). *Acta Derm Venereol*. 1982;62(4):364–366. PMID: 6183881. doi:10.2340/0001555562364366
11. Abdo HM. Marvelous response of severe onychotillomania to treatment with local steroid injection plus topical calcipotriol/betamethasone dipropionate combination. *Skin Appendage Disord*. 2020;6(3):158–161. PMID: 32656235; PMCID: PMC7325202. doi:10.1159/000506139
12. Snorrason I, Woods DW. Nail picking disorder (onychotillomania): a case report. *J Anxiety Disord*. 2014;28(2):211–214. PMID: 24291396. doi:10.1016/j.janxdis.2013.10.004
13. Rubin AI, Baran R. Physical signs. In: Baran R, de Berker DAR, Holzberg M, Thomas L, editors. *Baran & Dawber's Diseases of the Nails and Their Management*. 4th ed. Oxford: Wiley-Blackwell; 2012:51–99.
14. Oppel T, Korting HC. Onychodystrophy and its management. *Ger Med Sci*. 2003;1:Doc02.
15. Lee YH, Lee HJ, Kim WS, et al. Treatment of idiopathic onychodystrophy with a 1064 nm picosecond neodymium-doped:yttrium aluminum garnet laser: a retrospective study. *J Cosmet Dermatol*. 2021;20(2):497–505. doi:10.1111/jocd.13580
16. Choi JY, Seo HM, Kim WS. Median canaliform nail dystrophy treated with a 1064-nm quasi-long pulsed Nd:YAG laser. *J Cosmet Laser Ther*. 2017;19(4):225–226. doi:10.1080/14764172.2017.1279330
17. Ho D, Mamalis A, Jagdeo J. Successful treatment of traumatic onychodystrophy and associated pterygium unguis with fractionated carbon dioxide laser: case report and review of the literature. *J Drugs Dermatol*. 2016;15(11):1461–1464.
18. Ibrahim O, Doumit J, Zhang A. Successful treatment of idiopathic onychodystrophy with 300 microsecond 1064 nm Nd:YAG laser. *J Drugs Dermatol*. 2015;14(7):750–752.
19. Lim EH, Seo YJ, Lee JH, et al. Onychodystrophy treated using fractional carbon dioxide laser therapy and topical steroids: new treatment options for nail dystrophy. *Dermatol Surg*. 2013;39(12):1931–1933. doi:10.1111/dsu.12365
20. Peruzzo J, Garbin GC, Maldonado G, et al. Nail psoriasis treated with pulsed dye laser. *An Bras Dermatol*. 2017;92(6):885–887. doi:10.1590/abd1806-4841.20175918
21. Yin N, Choudhary S, Nouri K. Pulsed dye laser for the treatment of nail psoriasis. *Cutis*. 2013;92(3):129–135.
22. Treewittayapoom C, Singvahanont P, Chanprapaph K, et al. The effect of different pulse durations in the treatment of nail psoriasis with 595-nm pulsed dye laser: a randomized, double-blind, inpatient left-to-right study. *J Am Acad Dermatol*. 2012;66(5):807–812. doi:10.1016/j.jaad.2011.12.015
23. Sonthalia S, Arora R, Sarkar R. Pulsed dye laser for nail psoriasis: not the first time and apparently not that efficacious! *Indian J Dermatol*. 2014;59(2):204. doi:10.4103/0019-5154.127699
24. Yaemsiri S, Hou N, Slining MM, et al. Growth rate of human fingernails and toenails in healthy American young adults. *J Eur Acad Dermatol Venereol*. 2010;24(4):420–423. doi:10.1111/j.1468-3083.2009.03426.x

Clinical, Cosmetic and Investigational Dermatology

Dovepress

Publish your work in this journal

Clinical, Cosmetic and Investigational Dermatology is an international, peer-reviewed, open access, online journal that focuses on the latest clinical and experimental research in all aspects of skin disease and cosmetic interventions. This journal is indexed on CAS. The manuscript management system is completely online and includes a very quick and fair peer-review system, which is all easy to use. Visit <http://www.dovepress.com/testimonials.php> to read real quotes from published authors.

Submit your manuscript here: <https://www.dovepress.com/clinical-cosmetic-and-investigational-dermatology-journal>