

# Temporary Cerebral Revascularization Using a Radial Artery in the Hand-Eyeshade Posture: Technical Note

Jun HIRAMOTO<sup>1</sup> and Yuichiro TANAKA<sup>1</sup>

<sup>1</sup>*Department of Neurosurgery, St. Marianna University School of Medicine,  
Kawasaki, Kanagawa*

## Abstract

Kamiyama introduced a unique method of temporary cerebral revascularization using a radial artery graft (RAG) in his technical review. We tried original method with Sugita frame, and pointed out some disadvantages that include to avoid taking instruments or hands in and out, stability of hands, and unrestricted usage of brain retractors during temporary bypass between radial artery and M2 portion of middle cerebral artery (RA-M2 bypass). To solve those disadvantages, especially for Sugita head frame users, we here present a modified Kamiyama's method of temporary cerebral revascularization with the forearm elevated over the face like as hand-eyeshade posture.

Key words: Sugita head frame, high flow bypass, radial artery, cerebral aneurysm, revascularization

## Introduction

Some reports for cerebral revascularization with radial artery graft (RAG) have been reported in the recent years.<sup>1–6)</sup> Above all, Kamiyama's report included intra-operative unique application in Japanese literature,<sup>5)</sup> where a method by elevating the patient's forearm during temporary bypass was introduced with a schematic drawing. He also advocated that patient's forearm was elevated and sewn together tightly between rostral side scalp of craniotomy and the forearm skin for prevention against forearm dropping (Fig. 1a). Because of hazards we encountered during that method, such as interference with instrumentation by the forearm located between the patient's head and the surgeon, and restricted maneuverability of brain retractors, we have introduced a new position of the patient's forearm during temporary bypass.

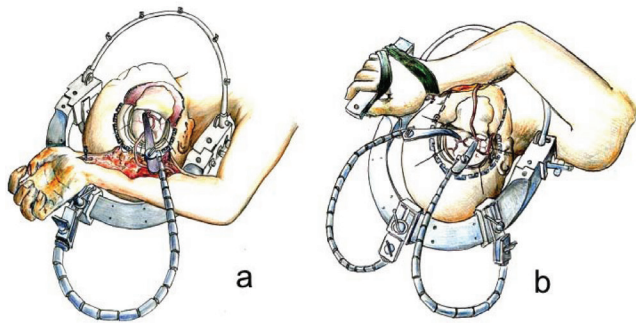
## Method

This method is recommended for the surgical treatment of large intracranial aneurysms that are not tolerated to the prolonged intra-operative proximal temporary occlusion of the parent artery. Under general anesthesia, the patient is placed in the supine position and the ipsi-lateral arm is held

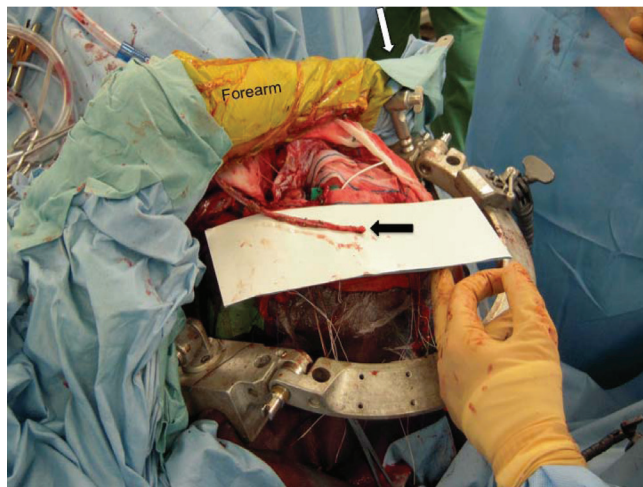perpendicular to the body. The patient's head is fixed in the Sugita head holder with the head rotated to the contra-lateral side. The surgeons are divided into two groups for craniotomy and RAG harvest, respectively. The artery is first identified at the wrist by palpation and Doppler probe analysis, and the skin incision is made just on the radial artery and extended toward the cubital fossa. The donor graft artery is cut down only at the wrist and separated from the connective tissue between the brachioradialis muscle and the flexor carpi ulnaris muscle in the middle forearm. After exposure of recipient artery, the forearm is moved to the site of craniotomy for temporary bypass between distal end of the harvested radial artery and M2 portion of the middle cerebral artery. The forearm is overridden the forehead like a person who shades one's eyes from the sun (hand-eyeshade posture) (Fig. 1b). The palm and wrist are bound tightly at the L-shaped hand rest on the contra-lateral side of the Sugita head frame system (Figs. 1b, 2). Surgeons are able to put their hands on the basal frame as usual.<sup>7)</sup> The RAG is cut down in the distal end of the radial artery and separated from middle cerebral artery after achieving neck clipping of the aneurysm and final scene of the grafted portion of middle cerebral artery is described in Fig. 3.

## Case presentation

A 47-year-old woman suffered from subarachnoid

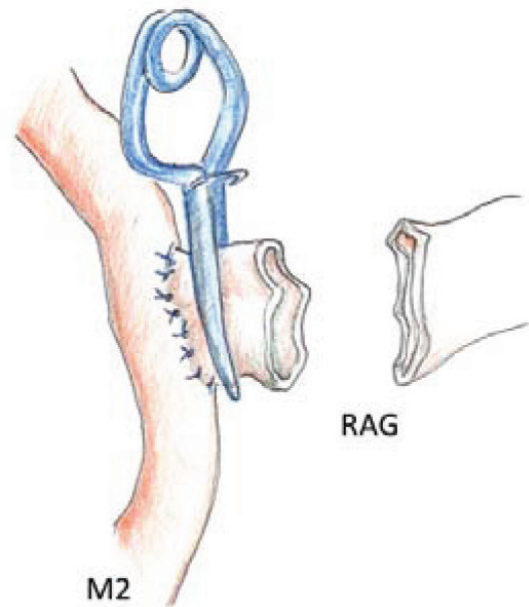


**Fig. 1** Head and forearm position with full Sugita head frame system in Kamiyama's original procedure (a) and in our modified position (b) during temporary RA-M2 bypass. RA-M2 bypass: bypass between radial artery and M2 portion of middle cerebral artery.

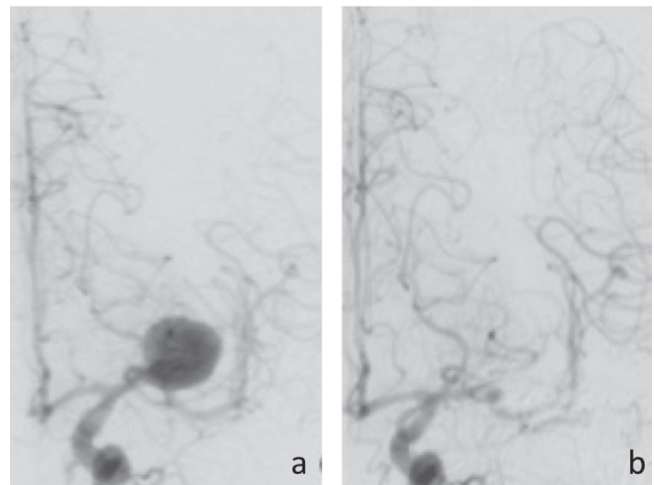


**Fig. 2** Actual operative picture proves the radial artery graft (arrow) harvested from the forearm and the forearm is overridden the forehead like a person who shades one's eyes from the sun (hand-eyeshade posture). The palm and wrist are bound tightly at the L-shaped hand rest (white arrow) on the contra-lateral side of the Sugita head frame system.

hemorrhage. Her angiography shows 23 mm aneurysm on left early bifurcation of middle cerebral artery (Fig. 4a). It was obvious that proximal occlusion made ischemia in the territory of distal middle cerebral artery. She underwent a direct surgery for large aneurysm in preparation of trapping procedure with high flow bypass using RAG including a trial for aneurysm neck clipping under temporary RAG bypass on eleventh day of disease. This aneurysm was treated by neck clipping with the method of the "hand-eyeshade posture." The duration of temporary proximal occlusion that



**Fig. 3** The temporary radial artery graft (RAG) is cut down and removed after safe neck clipping of aneurysm with clipping at the distal end of the RAG.



**Fig. 4** The preoperative angiography (a) shows 22 mm aneurysm on left early bifurcation of middle cerebral artery. The postoperative angiography demonstrates aneurysmal lesion is no longer disappeared without distal occlusion of middle cerebral artery (b).

performed on M1 portion was 22 minutes in this surgical procedure. After operation, she had incomplete right hemiparesis because of lacunar infarction that was thought to be made by occlusion of the lenticulostriate artery at the time of proximal temporary occlusion. She did not have aphasia

and other cortical disturbance owed to temporary RA-M2 bypass.

## Discussion

The method of temporary cerebral revascularization using a RAG that was originally developed by Kamiyama has many advantages. Temporary RA-M2 bypass enables neck clipping of complex intracranial aneurysm that has minimal tolerance to ischemia. If neck clipping proves to be impossible under proximal occlusion with temporary cerebral revascularization, the RAG is used for permanent high flow ECA-RA-M2 bypass with the parent artery trapping.<sup>5)</sup> We achieved to solve problems for Sugita head frame users by shifting the forearm from vertex of the head to the forehead. In our experience with one case, we never had apprehensions of dropping forearm and had performed operation with satisfied instrumentation, hands stability, and unrestricted usage of brain retractors during temporary RA-M2 bypass and no incidence of cerebral low perfusion could be pointed out by intra-operative sensory evoked potential (SEP) and motor evoked potential (MEP) monitors. Hongo et al. also introduced similar technique as double insurance bypass.<sup>2)</sup> Our method also solve the firm shoulder that Ishikawa et al. pointed out as one of the pitfalls in double insurance bypass,<sup>4)</sup> because patient's arm is not necessary to be elevated so higher than the previous fashioned method (Fig. 3). We can indicate a pitfall that accidental hemorrhage from donor side wound is likely to overlook, because the skin incision of the forearm is hidden.

## References

- 1) Baaj AA, Agazzi S, van Loveren H: Graft selection in cerebral revascularization. *Neurosurg Focus* 26: E18, 2009
- 2) Hongo K, Horiuchi T, Nitta J, Tanaka Y, Tada T, Kobayashi S: Double-insurance bypass for internal carotid artery aneurysm surgery. *Neurosurgery* 52: 597–602; discussion 600–602, 2003
- 3) Houkin K, Kamiyama H, Kuroda S, Ishikawa T, Takahashi A, Abe H: Long-term patency of radial artery graft bypass for reconstruction of the internal carotid artery. Technical note. *J Neurosurg* 90: 786–790, 1999
- 4) Ishikawa T, Kamiyama H, Kobayashi N, Tanikawa R, Takizawa K, Kazumata K: Experience from “double-insurance bypass.” Surgical results and additional techniques to achieve complex aneurysm surgery in a safer manner. *Surg Neurol* 63: 485–490; discussion 490, 2005
- 5) Kamiyama H: [Bypass with radial artery graft]. *No Shinkei Geka* 22: 911–924, 1994 (Japanese)
- 6) Sekhar LN, Duff JM, Kalavakonda C, Olding M: Cerebral revascularization using radial artery grafts for the treatment of complex intracranial aneurysms: techniques and outcomes for 17 patients. *Neurosurgery* 49: 646–658; discussion 658–659, 2001
- 7) Sugita K, Hirota T, Mizutani T, Mutsuga N, Shibuya M, Tsugane R: A newly designed multipurpose microneurosurgical head frame. Technical note. *J Neurosurg* 48: 656–657, 1978

---

Address reprint requests to: Jun Hiramoto, MD, Department of Neurosurgery, St. Marianna University School of Medicine, 2-16-1 Sugao, Miyamae-ku, Kawasaki, Kanagawa 216-8511, Japan.  
e-mail: jphira@marianna-u.ac.jp