

Received:
03 January 2021

Revised:
09 April 2021

Accepted:
19 May 2021

© 2021 The Authors. Published by the British Institute of Radiology under the terms of the Creative Commons Attribution-NonCommercial 4.0 Unported License <http://creativecommons.org/licenses/by-nc/4.0/>, which permits unrestricted non-commercial reuse, provided the original author and source are credited.

Cite this article as:

Caredda G, Bassareo PP, Cherchi MV, Pontone G, Suri JS, Saba L. Anderson-fabry disease: role of traditional and new cardiac MRI techniques. *Br J Radiol* 2021; **94**: 20210020.

REVIEW ARTICLE

Anderson-fabry disease: role of traditional and new cardiac MRI techniques

¹GLORIA CAREDDA, ²PIER PAOLO BASSAREO, ¹MARIA VALERIA CHERCHI, ³GIANLUCA PONTONE, ⁴JASJIT S SURI and ¹LUCA SABA, MD

¹Department of Radiology, Azienda Ospedaliero Universitaria (A.O.U.), Cagliari, Italy

²Mater Misericordiae University Hospital and Our Lady's Children's Hospital, University College of Dublin, Dublin, Ireland

³Department of Cardiology, Ospedale Monzino, Milano, Italy

⁴Stroke Diagnosis and Monitoring Division, AtheroPoint™, Roseville, California, USA

Address correspondence to: Dr Luca Saba

E-mail: lucasaba@tiscali.it

ABSTRACT

Anderson-Fabry (FD) disease is a rare X-linked disorder caused by different mutations in the Galactosidase α (GLA) gene, which leads to α -galactosidase A enzyme deficiency and the storage of glycosphingolipids in different kinds of organs, included the heart. This results in myocardial inflammation and left ventricular hypertrophy (LVH) and fibrosis. Echocardiography and cardiac magnetic resonance (C-MRI), in particular with new techniques, such as mapping analysis, late gadolinium enhancement (LGE) assessment and strain imaging, are important tools that allow a correct diagnosis, discriminating FD from other hypertrophic heart conditions. C-MRI is able to detect tissue alterations in the early stages of the disease, when an appropriate treatment could be more effective, and it has a fundamental role in monitoring therapy.

BACKGROUND

Anderson-Fabry disease (FD) belongs to a group of more than 50 lysosomal storage disorders¹ caused by different mutations in the Galactosidase α (GLA) gene located on X chromosome (Xq22.1), which lead to α -galactosidase A enzyme deficiency.² A value of 30–35% of the usual α -galactosidase A activity is diagnostic for FD.³ Currently, 961 different GLA mutations are described in literature.⁴ The deficiency causes glycosphingolipids progressive accumulation, globotriaosylceramide the most, in many different kinds of cells, in particular those present in the kidneys, heart, and nervous system.² It may, in turn, induce a multisystem disease.³

The estimated prevalence of FD is from 1:40 000 to 1:117 000,^{3,5} although a few recent screening surveys on neonates showed that FD prevalence is higher in certain regions, such as Italy (1:3100) and Taiwan (1:1250).^{3,4} Despite the X-linked transmission, females also may be symptomatic, although with less severe manifestations than males.²

Two main forms of FD can be described. The first is the classic form, more commonly seen in males, which

is characterized by a very low residual enzyme activity, leading to a severe phenotype, with peculiar symptoms including neuropathic pain with acroparesthesia, cornea verticillate, and angiokeratoma. In the long term, the heart can be involved as well, with the appearance of hypertrophic cardiomyopathy, rhythm and conduction disturbances, and heart failure. Other non-cardiac symptoms include stroke and steady renal insufficiency with proteinuria. The second or non-classic FD subtype, instead, represents a late-onset or atypical form of the disease, with reduced but still present enzyme activity. Its clinical manifestations are less severe, slowly progressive, and often limited to a single organ, usually the heart.^{2,3}

Symptoms of the classic form can occur during childhood as well. They include diffuse pain attacks, lasting from few minutes to days. They are usually triggered by excessively elevated bodily temperature as a consequence of physical exercise, fever, or warm environment. Other symptoms in children are sweating anomalies, such as anhydrosis or hypohydrosis, as well as hearing loss. Usually, the patients survive into adulthood.⁴ The main signs and symptoms according to FD

Table 1. FD peculiar signs and symptoms

Childhood	Adolescence	Adulthood
Chronic pain	Gastrointestinal distress	Renal insufficiency
Acroparesthesias	Angiokeratoma	Cardiac dysfunction/ arrhythmias
Cornea verticillata	Lymphadenopathy	Cerebrovascular stroke
Sweating anomalies	Cardiac manifestations	Bone demineralization
Hearing loss	High albuminuria	Deafness (acute or chronic onset)
Increased albuminuria		
Non-specific bowel disturbances		
Lethargy and fatigue		

patient's age are reported in Table 1, Table 2 and Table 3.

In patients affected by FD, brain vascular deterioration has been well documented, with the involvement of the vertebrobasilar system and carotid circulation. As a result, many neurological deficits may occur, such as hemiparesis, vertigo/dizziness, diplopia, dysarthria, nystagmus, nausea/vomiting, headaches,

Table 2. Typical clinical manifestations in male and female patients with FD⁶

Clinical signs and symptoms	Percentage in males (%)	Percentage in females (%)
Neurological: • Neuropathic pain (the most prevalent)	84 76	79 64
Dermatological: • Angiokeratomas	78	50
Renal: • Proteinuria • End-stage renal failure	50 44 17	50 33 1
Cardiac: • A n g i n a , a r r h y t h m i a s , dyspnea • LV hypertrophy	69 46	65 28
Cerebrovascular: • Stroke, TIA, p r o l o n g e d reversible ischemic neurological deficit	12	27
Vascular	45	35
Auditory: • Tinnitus, hearing loss	57	47
Ocular	62	53
Gastro-intestinal: • Abdominal pain, diarrhea	55	50
Fatigue	24	28

LV, Left ventricle; TIA, Transient ischemic attack.

hemiataxia and dysmetria, cerebellar gait ataxia and, very rarely, cerebral hemorrhage.⁸

FD treatment is based on two main different strategies: enzyme replacement therapy and chaperone therapy. Concerning the first, two different preparations are currently commercially available: agalsidase-alfa (*Replagal*[®]), produced by overexpression in human fibroblasts, and agalsidase-beta (*Fabrazyme*[®]), produced by overexpression in Chinese hamster ovary cells. The issues about enzyme replacement therapy are represented by the facts that it is expensive, its infusion is time-consuming and may cause

Table 3. Prevalence of clinical signs and symptoms in male patients with FD⁷

Clinical manifestation	Prevalence in patients (%)
LV hypertrophy	88
Proteinuria	84
Abnormal audiogram	78
Neuropathic pain	77
Angiokeratoma	71
Gastro-intestinal symptoms	69
Fatigue	62
Hypohydrosis	56
Chest pain/palpitation	56
Dysmorphic face	56
Abnormal renal function	47
Ankle swelling	45
Self-reported hearing loss	41
Tinnitus	38
End-stage renal failure	30,8
Heart valve abnormalities	29
TIA or CVA	24
Lymphedema	14

CVA, Cerebro vascular accidents; LV, Left ventricle; TIA, Transient ischemic attack.

reactions, not to mention the fact that therapy may be ineffective in some patients (for instance, in those with antibodies against the recombinant enzyme or with end-stage organ disease).

The rationale behind the use of chaperone molecules is that in some patients, although the enzyme has a residual activity, it may be destroyed by endoplasmic reticulum-associated protein degradation, so that enzyme stabilization by using these molecules (*Migalastat*[®]) may be effective.

Other potential therapeutic strategies consist in administering second-generation enzyme or substrate reduction therapies, while in the next foreseeable future genetic, stem cells, and m-RNA-based therapies are likely to become available.

In addition to FD-specific treatment, adjuvant medications may be required to treat FD symptoms, including ACE-inhibitors, angiotensin receptor blockers, blood thinners, and analgesics.^{2,4,9}

Pathogenesis and myocardial involvement

Besides their basic function of destroying many kinds of biomolecules, lysosomes are also involved in regulating the immune system. So, an anomaly in their function may have an impact on the immune system as well. In case of lysosomal storage disorder, indeed, the accumulation of waste products in the lysosomes activates an inflammatory cascade, which may evolve in chronic inflammation overtime. This is the reason why, in some patients, common therapies are not effective.

The trigger of inflammation is the secretion of damage-associated molecular patterns (DAMPs) by the injured cells. This steady production leads to chronic inflammation and involves normal cells as time goes by, with the development of an auto-inflammatory disorder. In particular, in FD α galactosidase A deficiency leads to the accumulation of Gb3 or lyso-Gb3, which can act as DAMPs or cause DAMPs production. The binding of Gb3 or lyso-Gb3 to toll-like receptor 4 (TLR-4) may activate the Notch1 signaling and consequently the nuclear factor κ B (NF- κ B) pathway, leading to release of pro-inflammatory cytokines and induction of a systemic inflammatory response.

Moreover, FD may cause leukocytes extravasation from blood into peripheral tissues, because of the increased expression of adhesion molecules (especially CD31) by CD3⁺ lymphocytes, monocytes, granulocytes, and endothelial cells. This inflammatory state induces the production of reactive oxygen species. Furthermore, other pathological elements are involved in FD, such as abnormal glutathione metabolism, high lipid peroxidation levels, and high nitric oxide equivalents levels.

Taken together, the previously mentioned mechanisms produce chronic and irreversible tissue injury, with fibrosis and organ failure, thus reducing life expectancy in FD patients if the heart, kidneys, or central nervous system are involved.¹

This review aims at examining cardiac involvement in FD from an imaging standpoint. The role of cardiac magnetic resonance (CMR) in this setting is stressed.

Cardiac involvement in FD

In FD, globotriaosylsphingosine (lyso-GL-3) accumulates in cardiomyocytes, valvular fibroblasts, cells of the conduction system, and endothelial cells, thus determining an inflammatory state with macrophages and T-lymphocyte interstitial infiltrate.¹ This in turn leads to left ventricle hypertrophy, cellular apoptosis/necrosis, left ventricular ischemia and myocardial fibrosis, systolic and diastolic dysfunction, ECG abnormalities (such as short PR interval, arrhythmias).^{1,10} These alterations develop way before symptoms onset and ideally the specific FD therapy should be given at this stage to be highly effective.

In some patients, sphingolipids accumulate only in the heart, and just cardiac signs and symptoms are present, thus configuring a "cardiac variant" of FD.

The FD most common cardiac manifestations are heart failure, angina on exertion due to microvascular anomalies, sinus node dysfunction/arrhythmias (with atrio-ventricular blocks, atrial fibrillation, non-sustained ventricular tachycardia), hypertension, and valve regurgitation.¹⁰

Cardiac involvement is predominant in males and generally becomes manifested in the third-fourth decade of life. However, heterozygous females also may show variable cardiac symptoms of FD, ranging from asymptomatic to as severe as a male with classic FD. A cardiac involvement in children and adolescent with FD, with left ventricular hypertrophy and high blood pressure, is not rare and may be evident even at young age.¹¹

DIAGNOSTIC APPROACH AND IMAGING

Diagnostic strategies

Since FD is a multisystemic disease, it should be suspected on the basis of clinical symptoms involving together the brain, skin, eyes, kidneys, and heart. However, the rarity of FD easily causes many clinicians to make misdiagnoses. As for cardiac the manifestations, in particular, when unexplained left ventricular hypertrophy is present, especially if it is concentric and non-obstructive, FD diagnosis should be suspected, in particular when it is associated with extra cardiac abnormalities, and/or strong family history.

Once FD is suspected, biochemical and genetic examinations are necessary for confirming diagnosis (8). In males, diagnosis is established when α -galactosidase A activity in peripheral leukocytes is 30–35% than normal or below. Conversely, in females, GLA gene sequencing is strictly needed, because α -galactosidase A activity is within the normal range in up to 60% of the female patients, due to random X-inactivation in heterozygous patients.^{10,12} In this gender, clinical presentation ranges from patients who are asymptomatic to others suffering from a disease which is as severe as in males. Moreover, Echevarria and Colleagues showed that, in females with random X-chromosome inactivation, the disease worsens progressively with age, with the onset of left ventricular hypertrophy and renal dysfunction. The same authors reported the association between the expression of a wild-type GLA allele and a mild FD phenotype with little disease progression overtime as well as the relation between a

Table 4. Electrocardiographic and echocardiographic main findings

Electrocardiography	Echocardiography
Left ventricle hypertrophy	Left ventricle hypertrophy with concentric thickening and normal LVEF, without ventricular obstruction
Short PR interval	Decreased longitudinal strain within the basal inferolateral LV wall, without localized hypertrophy
Sinus bradycardia with chronotropic incompetence	Thinning (infrequent) and/or hyperechoic basal LV inferolateral wall
Atrioventricular arrhythmias, enlarged QRS, bundle branch block	RV hypertrophy with preserved systolic function, LA function anomalies
	Moderate aortic dilatation
	LV hypertrabeculation, non-compaction
	Prominent papillary muscle, LV endocardial border with a binary aspect (uncertain)

LA, Left atrium; LV, Left ventricle; LVEF, Left ventricle ejection fraction; RV, Right ventricle.

mutant GLA allele and early-onset FD, characterized by rapid evolution and poor prognosis.¹³

However, it is important to notice that patients with the same GLA mutation may show different phenotypes.¹²

Considering the X-linked transmissibility of FD, three generations around an identified case should be checked for FD.¹²

According to Schiffman and Colleagues, FD clinical manifestations are mostly due to the substrate accumulation, rather than the enzyme deficiency. So, detecting glycosphingolipid accumulation in a certain organ is the key point to make FD diagnosis or quantify the risk of its complications. In this setting, tissue biopsy is often needed.³

Concerning the cardiovascular system, other examinations are required, namely, electrocardiography, echocardiography, and cardiac magnetic resonance (CMR). The main electrocardiographic (and echocardiographic) features in FD are described in Table 4.

As for blood markers, high-sensitivity troponin T (hs-TNT) correlates with replacement fibrosis as detected by CMR late gadolinium enhancement. Therefore, hs-TNT is an important tool for predicting the progression of FD-related cardiomyopathy.^{8,14}

ROLE OF ULTRASOUNDS

Echocardiography is the first-line non-invasive imaging tool to identify cardiac involvement in FD.

Ultrasounds allows to identify increased left ventricular wall thickness, which in FD is usually progressive, concentric, and non-obstructive. However, sometimes in the most advanced form of the disease, hypertrophy is asymmetrical with septal thickening and posterior wall fibrotic thinning. Right ventricular hypertrophy may develop later on and may progress to right ventricular dilatation.¹⁵

A papillary muscle hypertrophy which develops along with concentric left ventricular hypertrophy was proposed as an echocardiographic marker for the detection of FD,¹⁶ since this feature

was not seen in patients with hypertrophy due to other aetiologies (e.g., hypertension, amyloidosis, Friedreich ataxia).

A more precise and comprehensive characterization of FD cardiomyopathy using novel echocardiographic tools may lead to earlier diagnosis, timely treatment, and more accurate prognostic stratification. Since FD is an infiltrative disease, steady diastolic (first, and then) systolic dysfunctions develop overtime. By using modern ultrasounds techniques, these abnormalities can be detected early, even before the appearance of cardiac hypertrophy. In this respect, at Tissue Doppler Imaging (TDI), a decrease in longitudinal contractility was identified in mutation-positive FD patients without any signs of left ventricular hypertrophy.¹⁷ Using late gadolinium enhancement (LGE) at CMR as the gold standard for fibrosis localization in FD cardiomyopathy, Weidemann et al demonstrated that all LGE positive segments displayed a characteristic pattern made up of a first peak in early systole followed by a rapid drop in strain rate close to zero and a second peak during isovolumetric relaxation. The authors named this pathognomonic pattern as the “double peak sign”.¹⁸

Again, at 2-D speckle tracking imaging, left ventricle global longitudinal strain was reduced mainly in FD males with cardiac fibrosis at CMR. Since fibrosis in FD is mostly at basal posterior and lateral walls, the reduced deformation at strain is localized at the same sites.¹⁹

Usually, no significant valvular changes were described in FD subjects. While mild left ventricular valve regurgitations are frequent in FD, only a minority of patients with advanced disease develop symptomatic aortic or mitral valve regurgitation.²⁰

Finally, TDI and speckle tracking strain may have a role in detecting the disease at a subclinical stage, that is, before LVH development.²⁰ By using TDI, abnormalities may be observed before wall thickening and diastolic dysfunction occurring, for example.¹⁶ The main echocardiographic findings are reported in Table 4.

Role of cardiac magnetic resonance

Among the cardiac manifestations of FD, the main one is represented by left ventricular hypertrophy. In this scenario, CMR

is the gold standard for estimating left ventricle and papillary muscles hypertrophy, providing accurate and reproducible measurements. In addition, it is able to recognize the presence of myocardial anomalies in about 50% of patients with a genotype positivity, even when left ventricular hypertrophy is not severe and fibrosis is not present yet. This is useful to start treatment at an early stage of the disease, when it could be more effective. CMR provides information about response to therapy as well.^{21–23}

Moreover, CMR is a non-invasive tool and capable of assessing myocardium in terms of detecting sphingolipids infiltration and edema (T1 mapping, T2 mapping and T2*) as well as fibrosis (late gadolinium enhancement, LGE). In addition, through perfusion mapping sequences, CMR is able to detect impaired myocardial perfusion, before left ventricular hypertrophy occurs.

Finally, since FD is an infiltrative cardiac disease which may reverse if adequately treated, CMR is fundamental in differentiating it from other forms of left ventricle wall thickening.

CMR technical approach

CMR sequences are acquired before and after a gadolinium-based contrast agent administration. The related protocol is based on cine imaging, T2 sequences, native and post-contrast T1 mapping, T2 mapping, stress and rest perfusion, and LGE images.^{22,24}

Cine images for left ventricle volumes, mass and ejection fraction quantification, consist of balanced steady-state free precession acquisitions, performed in two chambers, four chambers, and short axis planes (basal, mid and apical) during breath holds.^{24,25}

Native T1 mapping is performed in basal, mid (and in some studies apical) short axis planes and in horizontal and vertical long axis planes. Fifteen minutes after gadolinium administration, post-contrast T1 mapping images are acquired, in order to calculate the extracellular volume (ECV) fraction.^{25,26}

It is important considering that the reported T1 values should always be referred to the specific T1 technique used for the acquisition, because their direct comparison is feasible only when obtained with the same acquisition scheme and the same field strength and when analyzed through the same post-processing methods. Indeed, the field strength which is used influences the native T1 values, which are higher at 3 T and lower at 1.5 T.²⁷ Moreover, they vary according to the sequences used, the diastolic or systolic acquisition and the segment of measurement. Therefore, T1 values should be evaluated on the basis of the local standard and revised when the acquisition method is modified²⁸.

Myocardial edema is investigated through black blood T2-weighted short tau inversion recovery (T2w-STIR) sequences, performed in short-axis planes, during breath holds, examining the left ventricle from the base to the apex. After STIR images acquisition, according to the Lake Louise Criteria, left ventricle

myocardial signal is compared to that of the skeletal muscle included in the same slice.²⁴

For T2 mapping assessment, T2 prepared gradient-echo pulse sequences are performed in basal, mid, and apical short axis before contrast administration.²⁵ The normal ranges for T1 and T2 values vary according to the scanner used.²²

As for perfusion images, they are acquired in a rest state and in a stress condition, after adenosine infusion.²²

Finally, the sequences for LGE detection are performed 15 min after contrast injection, using segmented phase-sensitive inversion recovery gradient echo pulse sequences. A pre-requisite for optimal acquisition is the setting of the inversion time in order to null the signal of normal myocardium (normally between 250 and 300 ms).²⁴

It is noteworthy mentioning that the heart has a specific microstructure, characterized by reinforced layers, which is crucial to guarantee an efficient function. In case his microstructure is altered, such as in several cardiac diseases, heart function decreases. In this setting, advanced CMR imaging, in particular the DWI, represents a fundamental non-invasive tool able to provide information about the fiber microstructure disarray.²⁹ Moreover, reflecting the random motion of water protons, DWI is able to characterize pericardial fluid, possibly present, and the ADC values allow to distinguish its nature, since they vary according to the fluid's nature (exudate, transudate, blood).³⁰

In particular, DWI images acquired in at least six different directions provide with the representation of the diffusion by a three-dimensional (3D) diffusor tensor (DT), from which specific measures of the magnitude of the diffusion, such as the apparent diffusion coefficient (ADC) or the mean diffusivity (MD), and the fractional anisotropy (FA) can be derived. Indeed, DT imaging is able to differentiate patients with hypertrophic cardiac myopathy from healthy subjects, while FA and mean ADC are able to quantify the amount of fiber disarray.^{29,31}

Afterwards, images are analyzed using a specific software, manually contouring the myocardial endo- and epicardial layers in both the systolic and diastolic phases and identifying the right ventricle insertion points. Myocardium is examined according to the American Heart Association 16 segments model. Left ventricle and mapping analysis are thus performed.²²

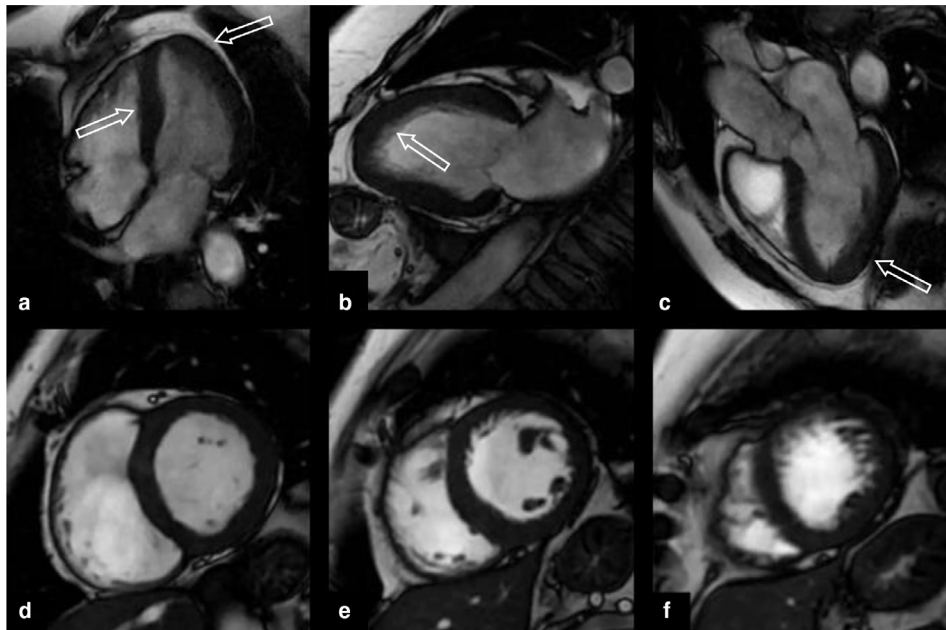
CMR findings

In FD, the most common CMR finding is concentric left ventricular hypertrophy (LVH) (Figure 1), characterized by a contribution of papillary muscles to the total left ventricle mass more important than that in healthy patients.^{21,32} The main CMR features in FD are described in Table 5.

T1 mapping and extra-cellular volume

Low native T1 mapping is an important indicator of intramyocardial sphingolipid accumulation (Figure 2). It is reported in over 90% of FD patients with LVH, but also in 40% of

Figure 1. a, b and c: apical and mid-ventricular hypertrophy (arrows) in cine images in 4-chamber (a), 2-chamber (b) and 3-chamber (c) view. d, e and f: basal (d), mid (e) and apical (f) short axis view.



those without LVH.¹⁰ Camporeale and Colleagues observed that low T1 values in the stages preceding the appearance of LVH are associated with morphological and electrocardiographic abnormalities.²⁵ Moreover, T1 relaxation times change with the disease progression and sphingolipid accumulation. Indeed, after the fibrosis occurs, CMR may show a pseudo-normalization of T1 times, due to the presence of sphingolipid deposition as well as fibrosis in the same areas.²¹ However, it is important to specify that, even in case of pseudo normalization, a certain inhomogeneity throughout the myocardial muscle is still present and septal T1 values mostly remain low, while the lateral segments show high T1 values. Furthermore, Nordin and Colleagues demonstrated that, although within the normal range, T1 values become progressively lower with age. In particular, the decrease is faster in males, especially after development of LVH, and less rapid in females, with a value stabilization after LVH development.^{21,33,34}

Moreover, Hagège and Colleagues observed that T1 mapping is an important tool for identifying early cardiac involvement, although LVH has not occurred yet.¹⁰

In addition, in FD disease, the extracellular volume (ECV), calculated through T1 mapping sequences acquired after contrast administration, is normal, similar to healthy patients.

T2-weighted and T2 mapping images

With regard to T2W images and T2 mapping sequences, they are important tools for global myocardial inflammation assessment, especially in the early stages of the disease (Figure 2).

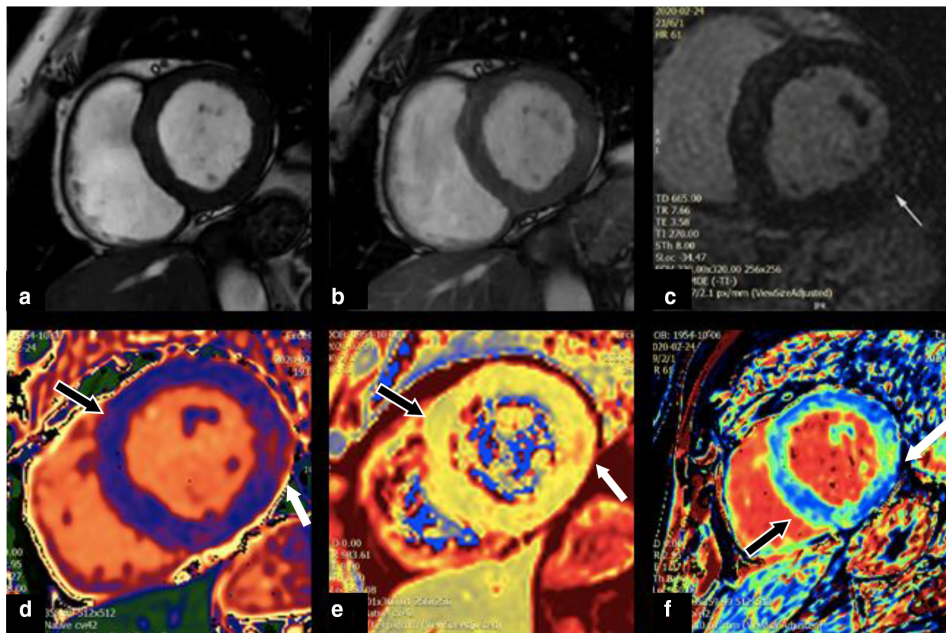
In the study by Frustaci and Colleagues, FD myocardial edema was detected in the basal antero septal wall (70%) and in some cases in the antero lateral wall as well, with a patchy mid-wall distribution. In addition, the same authors showed that,

Table 5. Main CMR findings

CMR acquisition	Main findings
Cine images	Left ventricular hypertrophy, thickened papillary muscles, right ventricular hypertrophy, and (eventually) systolic dysfunction
T ₂ -weighted images and T2 mapping	Increased values in the basal segment of inferior-lateral wall, with patchy distribution
T1 mapping	Low values (in the myocardial wall and in the papillary muscles), pseudo normalization in fibrotic areas
Perfusion mapping	Impairment in the subendocardial layers, with the lowest values in segments with LVH, low T1 values, high ECV and LGE
Late gadolinium enhancement	Altered signal in the basal and mid segments of the inferior-lateral wall of left ventricle, with a mid-wall or subepicardial pattern

ECV, Extra cellular volume; LGE, Late gadolinium enhancement; LVH, Left ventricular hypertrophy.

Figure 2. a, b: myocardial hypertrophy at the basal segments. c: LGE localized in the inferior-lateral segment (arrow). d: native T1 mapping: 1012 ms (black arrow) and 1195 ms (white arrow). e: T2 mapping: <50 ms (black arrow) and 59 ms (white arrow). f: ECV: <30% (black arrow) and 49% (white arrow). ECV, Extracellular volume; LGE, Late gadolinium enhancement.



in 31% of the patients, myocardial edema increased together with LVH.²⁴ On the other hand, Perry and Colleagues in their study detected an increased signal in the basal inferior-lateral region. Moreover, a correlation between T2 mapping values and troponin levels was demonstrated, thus suggesting that heart involvement in FD results in a chronic inflammatory cardiomyopathy.

Consequently, CMR evaluation should always be completed by T1 and T2 mapping sequences, in order to detect and monitor FD in both suspected and confirmed cases (19).

LGE images

When fibrosis occurs, LGE is usually localized in the basal and mid inferior-lateral wall of the left ventricle, with a mid-wall or subepicardial pattern (Figure 3).²⁴ Hagège et al. supposed that this particular distribution might be due to inhomogeneous left ventricle wall stress, microvascular dysfunction, or chronic myocardial inflammation, but the real cause remains still uncertain (8).

In the study by Deva and Colleagues, in some patients, the authors observed a continuity of the fibrotic scar from the mitral annulus into the mid-wall layer of the inferior-lateral segment of the left ventricle. Since this particular region is the most mobile part of the basal segments during cardiac cycle, it has been hypothesized that it encounters the most junctional stresses transmitted from the fibrous heart skeleton, thus suggesting why LGE is usually detected in the basal inferior-lateral segments.³⁵

It is noteworthy mentioning that the risk of LGE onset is higher in males with classical FD than in those with non-classical FD or females with classical FD. Again, in females, this risk is not associated with LVH, which is the opposite of what observed in male patients, where LVH is a strong predictor of LGE.^{2,21} Indeed, in females, there is no fixed linkage between hypertrophy and fibrosis, so that LGE could be detected in the female patients with FD at a non-hypertrophic stage of the disease.³¹ LGE is detectable in the RV as well (Figure 4).

Figure 3. Case of a male patient with LGE signal in the basal infero-lateral wall of the left ventricle, with a subepicardial disposition. LGE, Late gadolinium enhancement.

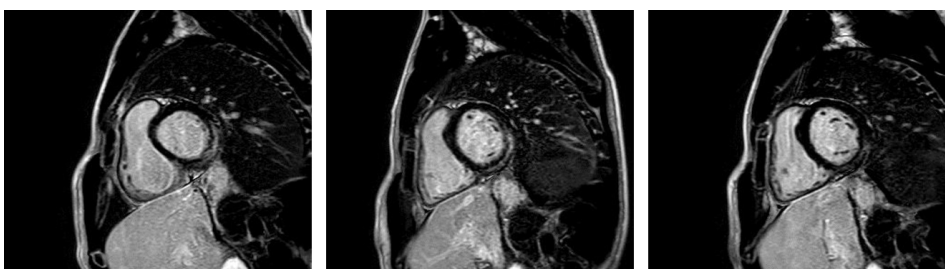
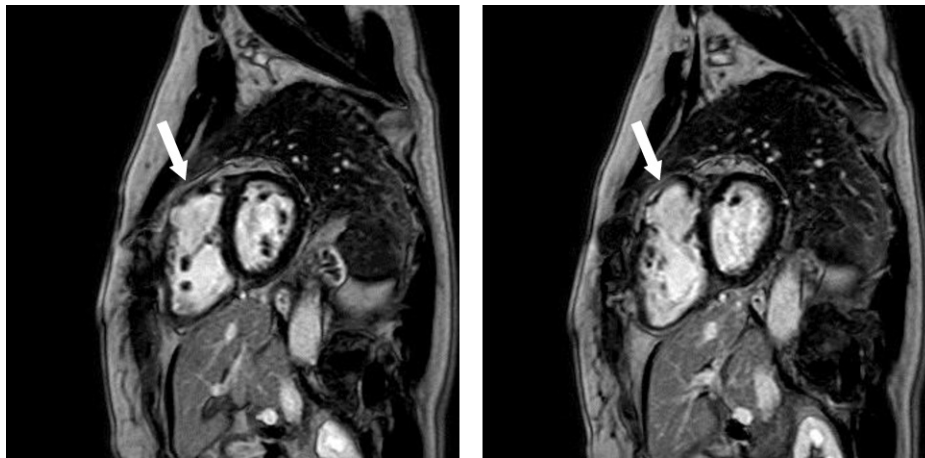


Figure 4. Case of a patient with RV involvement, showed by an LGE signal in the anterior segment of the mid and basal RV (white arrows). LGE, Late gadolinium enhancement; RV, Right ventricle.



Perfusion images

Although stress perfusion usually is not performed in this specific setting, CMR perfusion mapping allows the detection of impairment in myocardial perfusion, which usually is more evident in the subendocardial layers. The lowest perfusion is observed in myocardial segments with LVH, low T1 values, high ECV, and LGE, and can be detected even before LVH onset.

Knott and Colleagues demonstrated a reduction in myocardial blood flow (MBF), which can be detected in the early stages of FD disease, and is correlated with damage severity. In their study, the global stress MBF showed to be lower in patients with FD than in healthy controls, while no differences were noted as to MBF at rest. In particular, stress MBF was significantly lower in the regions with LVH, but also in FD patients without LVH when compared to the control group. A correlation with symptoms, such as chest pain and breathlessness, was found as well and may be due to a microvascular dysfunction, since symptomatic patients had a lower stress MBF than asymptomatic subjects.

The same authors reported stress MBF to be lower in the endocardial than in the epicardial layers, but normal in controls. This was only in the FD subgroup with LVH. Indeed, in patients without any LVH, no difference between epicardial and endocardial stress MBF was detected at all.

These results can be explained on the basis of the structural myocardial microvasculature changes identified through biopsy. In this respect, it is important to mention the study by Chimenti and Coll.,³⁶ in which the endomyocardial biopsies of thirteen FD patients with angina were compared to those of FD subjects without any chest pain. The authors found that the arteriolar lumen was narrowed, not only because of swollen and proliferating endothelial cells but also owing to hypertrophic and hyperplastic smooth muscle cells, with the concomitant contribution of increased fibrosis in the intimal and medial layers. In addition, the most compromised vessels were found to be surrounded by perivascular myocardial fibrosis. Conversely, in FD patients without angina, the luminal narrowing was less significant, and this result was in accordance with the perfusion study of Knot

and Colleagues proving the importance of stress perfusion in detecting microvasculature changes in the affected myocardium.

Moreover, Knott and Colleagues hypothesized that these abnormalities, which might be related to endothelial dysfunction, may precede sphingolipid storage in myocytes, thus being the first sign of myocardial involvement in FD. Besides, a certain amount of storage could be necessary before it is able to determine a reduction of T1 values, and it is possible that, in the early stages of sphingolipids accumulation, MBF as studied at CMR is more sensitive in detecting abnormalities than T1 values reduction.

In addition, perfusion mapping allows to assess the efficacy of enzyme replacement therapy (ERT).²²

Myocardial strain

Mathur and Colleagues tested the capability of CMR in detecting the early cardiac involvement in the disease, through the analysis of the myocardial strain. In their study, the loss of the base-to-apex circumferential strain (CS) gradient may be a marker of an early cardiac involvement, with no difference between males and females. Indeed, this gradient allows to differentiate between FD patients with no hypertrophy or LGE and healthy subjects, regardless of T1 values. In particular, the CS gradient was significantly lower in FD, even when the comparison was limited to subgroups without LVH and LGE, subgroups with only LVH and subgroups with only LGE.

On the contrary, the global longitudinal strain (GLS), the global circumferential strain (GCS), and the base-to-apex longitudinal strain in FD patients were not significantly different from those in control subjects. Thus, the authors concluded that the alterations in the global strain are likely to be relatively late signs of cardiac involvement.³⁷

Not only the left ventricle is involved in FD but also RV may appear hypertrophic and dysfunctional.²¹

With regard to FD cardiac phenotype evolution, Nordin and Colleagues hypothesized a model made up of an *accumulation*

phase, a hypertrophic and inflammatory phase, and finally a fibrosis and impairment (late) phase. The first one, which is subclinical, starts during childhood. In this stage, left ventricle mass and T1 are normal, with just some changes at ECG. With the steady sphingolipid storage, T1 lowers, decreasing faster in males than in females. In the second phase, myocardial inflammation and LGE develop, with a preferential basal inferior-lateral wall distribution. In this stage, LVH is more evident in females. At blood tests, troponin is persistently elevated. Finally, in the last stage, new LGE occurs outside the basal inferior-lateral wall, with elevated NT-proBNP, left ventricle impairment, and heart failure.³⁸

CMR in monitoring therapy

As previously reported CMR plays a pivotal role in assessing FD treatment efficacy. In FD natural evolution, fibrosis causes progressive myocardial thinning. For this reason, if LGE is not evaluated during CMR, it might erroneously lead to think that therapy is having a positive effect with left ventricle mass regression. Thus, LGE sequences should always be acquired.

Moreover, left ventricle mass reduces only in the patients with mild-LVH or little/no LGE, thus demonstrating that ERT should be started before myocardial fibrosis occurring. On the other hand, in patients with myocardial fibrosis as detected by LGE, fibrosis degree increases despite ERT, and it is considered the only independent predictor of the onset of ventricular arrhythmias.

Although currently there are no published studies examining the efficacy of FD therapy by means of T1 mapping assessment, it can be hypothesized that an effective treatment would be able to improve or even normalize T1 values, since T1 relaxation times express myocardial fat deposition. In short, it would be interesting to evaluate therapy response with T1 examination in future research.

Concerning T2 mapping, a decrease of T2 relaxation times was shown, and, interestingly, it correlates with left ventricle mass reduction after 45–48 months of ERT.²¹

DIFFERENTIAL DIAGNOSIS

Since FD may potentially reverse with an appropriate therapy, it is crucial to make a differential diagnosis between this disease and other infiltrative heart conditions, in particular those presenting with left ventricle walls thickening, such as hypertension, aortic stenosis, hypertrophic cardiomyopathy (HCM), and cardiac amyloidosis. The main criteria to make a differential diagnosis between FD and other heart diseases are summarized in Table 6. In HCM, hypertrophy is usually asymmetrical and involves the interventricular septum (but concentric and apical hypertrophy are possible as well), while it is usually concentric in FD, hypertensive heart disease, and cardiac amyloidosis.

In some cases, however, FD might present with an asymmetric septal hypertrophy or an eccentric pattern of hypertrophy, impossible to be distinguished from asymmetric forms of HCM without the analysis of mapping and LGE sequences (Figure 5).³⁹

Moreover, in HCM, left ventricular walls are generally thicker compared to the other conditions. A significant difference between FD and HCM is that FD shows a reduction of regional longitudinal strain in the basal inferior-lateral wall, while in HCM the longitudinal strain is decreased in the most hypertrophic regions, that is, usually at the interventricular septum. Furthermore, a decreased global circumferential strain and abnormalities of the base-to-apex gradient suggest FD diagnosis, regardless of LVH. These alterations allow to differentiate FD from healthy and non-obstructive HCM subjects.²¹

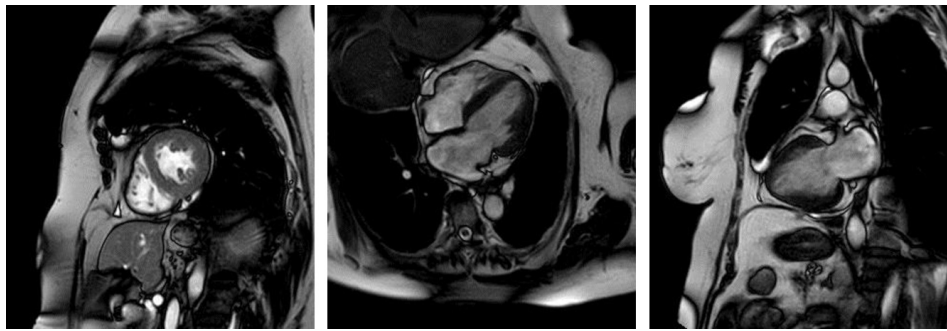
In hypertrophy induced by hypertension, instead, the reduction of longitudinal strain is usually detected at the basal septal regions or at left ventricle basal areas the most. Finally, in aortic

Table 6. Main differential diagnosis between FD and other heart conditions

	Anderson-Fabry disease	Hypertrophic cardiomyopathy	Cardiac amyloidosis	Aortic stenosis	Hypertensive heart disease
Cine Imaging	Concentric hypertrophy	Asymmetrical hypertrophy, involving the IV septum	Concentric hypertrophy	Concentric hypertrophy	Concentric hypertrophy
LGE	Basal inferior-lateral wall of the LV	At the RV insertion points	Global, with a sub endocardial pattern	No specific LGE pattern	No specific LGE pattern
T1 mapping	Low T1 values, starting in the pre-hypertrophic phase	Increased T1 values	- Increased T1 values, sparing the areas of fibrosis replacement	Normal T1 values	Normal T1 values
Strain Imaging	Reduction of regional LS in the basal inferior-lateral wall. Decreased global CS. Abnormalities of the base-to-apex gradient	Reduction of regional LS in the most hypertrophic regions (IV septum)	Reduction of the LS in the basal and mid areas, sparing the apex	Global reduction of the LS	Reduction of the LS in the basal septal regions (LV basal areas the most)

CS, Circumferential strain; IV septum, Interventricular septum; LGE, Late gadolinium enhancement; LS, Longitudinal strain; LV, Left ventricle; RV, Right ventricle.

Figure 5. Case of a patient with mild asymmetrical ventricular hypertrophy, with a septal thickness of 12 mm.



stenosis, the longitudinal strain is globally reduced (depending on the severity of the stenosis) and in cardiac amyloidosis it is decreased in the basal and mid areas, sparing the apex.²¹

Native T1 mapping is another important tool for differential diagnosis. In FD, indeed, T1 values are low, even in the pre-hypertrophic phase, while storage diseases such as amyloidosis show increased T1 attenuation,^{10,21,38,40} with the exception of areas of extensive replacement fibrosis.²⁰ On the other hand, low native T1 values⁴¹ are detectable in patients with hemochromatosis, although T2* analysis is able to discriminate between these conditions.¹⁰

Myocardial LGE is useful in making a differential diagnosis as well. In particular, in FD it is localized in the basal inferior-lateral wall of the left ventricle, while in HCM, for instance, it is usually

detected at RV insertion points. In amyloidosis, instead, the LGE pattern is generally global and with a subendocardial distribution. Conversely, there is no specific LGE pattern in conditions such as hypertensive heart disease and aortic stenosis.²¹

CONCLUSION

CMR is the gold standard for assessing myocardial involvement in FD and providing important information in a non-invasive and reproducible way. Moreover, it is able to differentiate this condition from other heart diseases, thus avoiding misdiagnosis.

Since their strong correlation with echocardiographic features, T1 values measurement and perfusion mapping allow the detection of early myocardial involvement before the occurrence of left ventricular hypertrophy and myocardial fibrosis, when ERT may show the greatest effectiveness.

REFERENCES

- Rozenfeld P, Feriozzi S. Contribution of inflammatory pathways to Fabry disease pathogenesis. *Mol Genet Metab* 2017; **122**: 19–27. doi: <https://doi.org/10.1016/j.ymgme.2017.09.004>
- Arends M, Wanner C, Hughes D, Mehta A, Oder D, Watkinson OT, et al. Characterization of classical and nonclassical Fabry disease: a multicenter study. *J Am Soc Nephrol* 2017; **28**: 1631–41. doi: <https://doi.org/10.1681/ASN.2016090964>
- Schiffmann R, Fuller M, Clarke LA, Aerts JMFG. Is it Fabry disease? *Genet Med* 2016; **18**: 1181–5. doi: <https://doi.org/10.1038/gim.2016.55>
- Miller JJ, Kanack AJ, Dahms NM. Progress in the understanding and treatment of Fabry disease. *Biochimica et biophysica acta. General subjects* 2020; **1864**: 129437.
- Mallett A, Kearey P, Cameron A, Healy H, Denaro C, Thomas M, et al. The CKD. Qld fabry epidemiology (acquire) study protocol: identifying the prevalence of fabry disease amongst patients with kidney disease in Queensland, Australia. *BMC Nephrol* 2020; **21**: 58. doi: <https://doi.org/10.1186/s12882-020-01717-9>
- Mehta A, Ricci R, Widmer U, Dehout F, Garcia de Lorenzo A, Kampmann C, et al. Fabry disease defined: baseline clinical manifestations of 366 patients in the Fabry outcome survey. *Eur J Clin Invest* 2004; **34**: 236–42. doi: <https://doi.org/10.1111/j.1365-2362.2004.01309.x>
- MacDermot KD, Holmes A, Miners AH. Anderson-Fabry disease: clinical manifestations and impact of disease in a cohort of 98 hemizygous males. *J Med Genet* 2001; **38**: 750–60. doi: <https://doi.org/10.1136/jmg.38.11.750>
- Razek AAKA, Elsebaie NA. Imaging of vascular cognitive impairment. *Clin Imaging* 2021; **74**: 45–54. doi: <https://doi.org/10.1016/j.clinimag.2020.12.038>
- van der Veen SJ, Hollak CEM, van Kuilenburg ABP, Langeveld M. Developments in the treatment of Fabry disease. *J Inherit Metab Dis* 2020; **43**: 908–21. doi: <https://doi.org/10.1002/jimd.12228>
- Hagège A, Réant P, Habib G, Damy T, Barone-Rochette G, Soulat G, et al. Fabry disease in cardiology practice: literature review and expert point of view. *Arch Cardiovasc Dis* 2019; **112**: 278–87. doi: <https://doi.org/10.1016/j.acvd.2019.01.002>
- Bassareo PP, Barbanti C, Marras AR, Mercurio G. Enzyme replacement therapy in paediatric patients affected by Anderson-Fabry disease leads to improvement in arterial elasticity, but not normalization. *J Pediatr Neonat Individual Med* 2017; **6**: e060211.
- Schiffmann R, Hughes DA, Linthorst GE, Ortiz A, Svarstad E, Warnock DG, et al. Screening, diagnosis, and management of patients with Fabry disease: conclusions from a "Kidney Disease: Improving Global Outcomes" (KDIGO) Controversies Conference. *Kidney Int* 2017; **91**: 284–93. doi: <https://doi.org/10.1016/j.kint.2016.10.004>
- Echevarria L, Benistan K, Toussaint A, Dubourg O, Hagege AA, Eladari D, et al. X-Chromosome inactivation in female patients

- with Fabry disease. *Clin Genet* 2016; **89**: 44–54. doi: <https://doi.org/10.1111/cge.12613>
14. Seydelmann N, Liu D, Krämer J, Drechsler C, Hu K, Nordbeck P, et al. High-Sensitivity troponin: a clinical blood biomarker for staging cardiomyopathy in Fabry disease. *J Am Heart Assoc* 2016; **5**: e002839. doi: <https://doi.org/10.1161/JAHA.115.002839>
 15. Yeung DF, Sirrs S, Tsang MYC, Gin K, Luong C, Jue J, et al. Echocardiographic assessment of patients with Fabry disease. *J Am Soc Echocardiogr* 2018; **31**: 639–49. Epub 2018 Mar 29. PMID. doi: <https://doi.org/10.1016/j.echo.2018.01.016>
 16. Niemann M, Liu D, Hu K, Herrmann S, Breunig F, Strotmann J, et al. Prominent papillary muscles in Fabry disease: a diagnostic marker? *Ultrasound Med Biol* 2011; **37**: 37–43. doi: <https://doi.org/10.1016/j.ultrasmedbio.2010.10.017>
 17. Pieroni M, Chimenti C, Ricci R, Sale P, Russo MA, Frustaci A. Early detection of Fabry cardiomyopathy by tissue Doppler imaging. *Circulation* 2003; **107**: 1978–84. doi: <https://doi.org/10.1161/01.CIR.0000061952.27445.A0>
 18. Krämer J, Niemann M, Liu D, Hu K, Machann W, Beer M, et al. Two-dimensional speckle tracking as a non-invasive tool for identification of myocardial fibrosis in Fabry disease. *Eur Heart J* 2013; **34**: 1587–96. doi: <https://doi.org/10.1093/eurheartj/ehd098>
 19. Akhtar MM, Elliott PM. Anderson-Fabry disease in heart failure. *Biophys Rev* 2018; **10**: 1107–19. doi: <https://doi.org/10.1007/s12551-018-0432-5>
 20. Perry R, Shah R, Saiedi M, Patil S, Ganesan A, Linhart A, et al. The role of cardiac imaging in the diagnosis and management of Anderson-Fabry disease. *JACC Cardiovasc Imaging* 2019; **12**(7 Pt 1): 1230–42. doi: <https://doi.org/10.1016/j.jcmg.2018.11.039>
 21. Knott KD, Augusto JB, Nordin S, Kozor R, Camaioni C, Xue H, et al. Quantitative myocardial perfusion in Fabry disease. *Circulation* 2019; **12**: e008872. doi: <https://doi.org/10.1161/CIRCIMAGING.119.008872>
 22. Moon J, Sachdev B, Elkington AG, McKenna WJ, Mehta A, Pennell DJ. Gadolinium enhanced cardiovascular magnetic resonance in Anderson-Fabry disease: evidence for a disease specific abnormality of the myocardial interstitium. *Eur Heart J* 2003; **24**: 2151–5. doi: <https://doi.org/10.1016/j.ehj.2003.09.017>
 23. Frustaci A, Verardo R, Grande C, Galea N, Piselli P, Carbone I, et al. Immune-Mediated myocarditis in Fabry disease cardiomyopathy. *J Am Heart Assoc* 2018; **7**: e009052. doi: <https://doi.org/10.1161/JAHA.118.009052>
 24. Camporeale A, Pieroni M, Pieruzzi F, Lusardi P, Pica S, Spada M, et al. Predictors of clinical evolution in prehypertrophic Fabry disease. *Circulation* 2019; **12**: e008424. doi: <https://doi.org/10.1161/CIRCIMAGING.118.008424>
 25. Nordin S, Kozor R, Baig S, Abdel-Gadir A, Medina-Menacho K, Rosmini S, et al. Cardiac phenotype of prehypertrophic Fabry disease. *Circulation* 2018; **11**: e007168. doi: <https://doi.org/10.1161/CIRCIMAGING.117.007168>
 26. Haaf P, Garg P, Messroghli DR, Broadbent DA, Greenwood JP, Plein S. Cardiac T1 mapping and extracellular volume (ECV) in clinical practice: a comprehensive review. *Journal of Cardiovascular Magnetic Resonance* 2017; **18**: 89. doi: <https://doi.org/10.1186/s12968-016-0308-4>
 27. Kawel N, Nacif M, Zavadni A, Jones J, Liu S, Sibley CT, et al. T1 mapping of the myocardium: intra-individual assessment of the effect of field strength, cardiac cycle and variation by myocardial region. *Journal of Cardiovascular Magnetic Resonance* 2012; **14**: 27. doi: <https://doi.org/10.1186/1532-429X-14-27>
 28. Bates J, Teh I, McClymont D, Kohl P, Schneider JE, Grau V. Monte Carlo simulations of diffusion weighted MRI in myocardium: validation and sensitivity analysis. *IEEE Trans Med Imaging* 2017; **36**: 1316–25. doi: <https://doi.org/10.1109/TMI.2017.2679809>
 29. Razeq AAKA, Samir S. Differentiation malignant from benign pericardial effusion with diffusion-weighted MRI. *Clin Radiol* 2019; **74**: 325.e19–325.e24. doi: <https://doi.org/10.1016/j.crad.2019.01.005>
 30. Mekkaoui C, Reese TG, Jackowski MP, Bhat H, Sosnovik DE. Diffusion MRI in the heart. *NMR Biomed* 2017; **30**: e3426. doi: <https://doi.org/10.1002/nbm.3426>
 31. Kozor R, Callaghan F, Tchan M, Hamilton-Craig C, Figtree GA, Grieve SM. A disproportionate contribution of papillary muscles and trabeculations to total left ventricular mass makes choice of cardiovascular magnetic resonance analysis technique critical in Fabry disease. *Journal of Cardiovascular Magnetic Resonance* 2015; **17**: 22. doi: <https://doi.org/10.1186/s12968-015-0114-4>
 32. Thompson RB, Chow K, Khan A, Chan A, Shanks M, Paterson I, et al. T₁ Mapping With Cardiovascular MRI Is Highly Sensitive for Fabry Disease Independent of Hypertrophy and Sex. *Circulation* 2013; **6**: 637–45. doi: <https://doi.org/10.1161/CIRCIMAGING.113.000482>
 33. Deva DP, Hanneman K, Li Q, Ng MY, Wasim S, Morel C, et al. Cardiovascular magnetic resonance demonstration of the spectrum of morphological phenotypes and patterns of myocardial scarring in Anderson-Fabry disease. *Journal of Cardiovascular Magnetic Resonance* 2016; **18**: 14. doi: <https://doi.org/10.1186/s12968-016-0233-6>
 34. Niemann M, Herrmann S, Hu K, Breunig F, Strotmann J, Beer M, et al. Differences in Fabry cardiomyopathy between female and male patients: consequences for diagnostic assessment. *JACC Cardiovasc Imaging* 2011; **4**: 592–601. doi: <https://doi.org/10.1016/j.jcmg.2011.01.020>
 35. Chimenti C, Morgante E, Tanzilli G, Mangieri E, Critelli G, Gaudio C, et al. Angina in Fabry disease reflects coronary small vessel disease. *Circulation* 2008; **1**: 161–9. doi: <https://doi.org/10.1161/CIRCHEARTFAILURE.108.769729>
 36. De Cobelli F, Esposito A, Belloni E, Pieroni M, Perseghin G, Chimenti C, et al. Delayed-Enhanced Cardiac MRI for Differentiation of Fabry's Disease from Symmetric Hypertrophic Cardiomyopathy. *American Journal of Roentgenology* 2009; **192**: W97–102. doi: <https://doi.org/10.2214/AJR.08.1201>
 37. Mathur S, Dreisbach JG, Karur GR, Iwanochko RM, Morel CF, Wasim S, et al. Loss of base-to-apex circumferential strain gradient assessed by cardiovascular magnetic resonance in Fabry disease: relationship to T1 mapping, late gadolinium enhancement and hypertrophy. *Journal of Cardiovascular Magnetic Resonance* 2019; **21**: 45. doi: <https://doi.org/10.1186/s12968-019-0557-0>
 38. Nordin S, Kozor R, Medina-Menacho K, Abdel-Gadir A, Baig S, Sado DM, et al. Proposed Stages of Myocardial Phenotype Development in Fabry Disease. *JACC: Cardiovascular Imaging* 2019; **12**(8 Pt 2): 1673–83. doi: <https://doi.org/10.1016/j.jcmg.2018.03.020>
 39. Labombarda F, Saloux E, Milesi G, Bienvenu B. Loss of base-to-apex circumferential strain gradient: a specific pattern of Fabry cardiomyopathy? *Echocardiography* 2017; **34**: 504–10. doi: <https://doi.org/10.1111/echo.13496>
 40. Sado DM, White SK, Piechnik SK, Banyersad SM, Treibel T, Captur G, et al. Identification and assessment of Anderson-Fabry disease by cardiovascular magnetic resonance noncontrast myocardial T1 mapping. *Circulation* 2013; **6**: 392–8. doi: <https://doi.org/10.1161/CIRCIMAGING.112.000070>
 41. Weidemann F, Strotmann JM, Niemann M, Herrmann S, Wilke M, Beer M, et al. Heart valve involvement in Fabry cardiomyopathy. *Ultrasound Med Biol* 2009; **35**: 730–5. doi: <https://doi.org/10.1016/j.ultrasmedbio.2008.10.010>