

Received: 2013.03.08
Accepted: 2013.09.16
Published: 2014.01.21

Levels of plasma matrix metalloproteinases (MMP-2 and MMP-9) in response to INTEGRA® dermal regeneration template implantation

Authors' Contribution:
Study Design A
Data Collection B
Statistical Analysis C
Data Interpretation D
Manuscript Preparation E
Literature Search F
Funds Collection G

ABCDEF 1,2 **Michał Bohdan Nessler**
AD 2 **Jacek Puchata**
DEF 1 **Anna Chrapusta**
EF 3 **Katarzyna Nessler**
DEG 4 **Justyna Drukała**

1 Department of Plastic and Reconstructive Surgery, Children's Burn Centre, University Children's Hospital, Jagiellonian University Medical College, Cracow, Poland
2 Burns and Plastic Surgery Centre of Małopolska, Ludwik Rydygier Memorial Hospital in Cracow, Cracow, Poland
3 Department of Family Medicine, Jagiellonian University Medical College, Cracow, Poland
4 Laboratory of Cell and Tissue Engineering, Department of Cell Biology, Faculty of Biochemistry, Biophysics and Biotechnology, Jagiellonian University, Cracow, Poland

Corresponding Author: Michał B. Nessler, e-mail: mnessler@gmail.com

Source of support: This work was supported by the Polish Ministry of Scientific Research and Higher Education (N N302 061936) and the European Regional Development Fund within the Operational Programme Innovative Economy (POIG 01.02-00-109/99 "Innovative methods of stem cell application in medicine")

Background: Cutaneous wound healing results in scar formation. Matrix metalloproteinases (MMP) transform extracellular matrix proteins and modulate inflammation and cell signaling, thus determining scar outcome. To provide rapid wound closure and reduced scarring, dermal scaffolds were introduced. Little is known about the influence of these materials on MMPs levels.


Material/Methods: In this *in vivo* study the levels of MMP-2, MMP-9, and mediators of inflammation and fibrosis (IL-4 and TGF-β1) in patients treated with Integra® dermal regeneration template (IDRT) were investigated. In the group of 11 pediatric patients treated with IDRT, levels of selected molecules were analyzed before surgery and at day 1, 7, and 25 after scaffold implantation.

Results: The mean IDRT take rate was 89.5±4.7% with 4 patients (36%) who developed local infection. Patients were divided into 2 groups according to presence of infection (1 group with complications and 1 group without complications). In the group with complications, the IDRT take rate was significantly reduced compared to the group without complications (71.5±5.4 vs. 100±0.1; p<0.005). Plasma levels of MMP-2 were significantly (p<0.05) elevated in both groups on day 7 after the scaffold placement compared to baseline. Positive correlations between IL-4 and MMP-2 (p=0.01) in the group with complications and TGF-β1 and MMP-9 (p=0.012) in both groups were observed.

Conclusions: These findings suggest that Integra® scaffold degradation is mainly caused by MMP-2, whereas inflammation associated with local infection increases levels of this molecule and it is not associated with elevation of MMP-9. This shows that dermal regeneration with Integra® uses molecular mechanisms other than scar formation during dermal wound healing.

Key words: **wound healing • dermal regeneration • metalloproteinases • dermal scaffolds**

Full-text PDF: <http://www.medscimonit.com/download/index/idArt/889135>

 2299

 2

 4

 34

Background

Skin has a complex structure that facilitates multiple functions in maintaining body homeostasis. Because it is also the barrier protecting from the external environment, it is often exposed to injuries. After injury, skin has a limited capability to restore some functions [1]. Cutaneous wound healing is a highly complex process involving inflammation, matrix deposition, and remodeling [2]. These events are governed by a number of different cell types that are influenced by cell-cell and cell-matrix interactions [3].

Proteolytic degradation of the extracellular matrix is one of the principal factors in the repair and remodeling steps of cutaneous wound healing [2]. Matrix metalloproteinases are well known mediators during physiological and pathological remodeling processes, including tissue repair. This group of zinc-dependent endopeptidases are synthesized as pro-enzymes and secreted mostly in inactive form. The domain structure of these proteins provides the capacity to decompose many substrates, including extracellular matrix and basement membranes macromolecules [4,5].

Wound matrix plays a key role as the regulator for cell adhesion, migration, proliferation, and differentiation during repair [6,7]. Recently, it has been shown that MMPs play also important role as the modulators of inflammation but the exact role of these molecules in inflammatory conditions has not yet been elucidated [8]. Special attention is being paid to the role of MMP-2 (gelatinase-A) and MMP-9 (gelatinase-B) in wound healing. These type IV collagenases, which are secreted by both endothelial cells and fibroblasts, have catalytic activity binding to gelatin, collagens, and laminin. The expression of the gelatinases within different cell types in the wound environment is consistent with their role in phases of wound healing. MMP-2 is mainly observed in fibroblasts and the key role of this gelatinase is ECM remodeling. MMP-9 is secreted by keratinocytes and inflammatory cells and is associated with epithelialization. An increased level of MMP-9 is observed during early inflammatory phase of wound healing, whereas MMP-2 level is increased during granulation tissue development and is maintained during ECM remodeling [9]. It is suggested that MMP-2 and MMP-9 are likely to play roles in the remodeling of the basic clot to form scar tissue and during microvessel maturation. Their prolonged activity has a long-term role in remodeling of the scar tissue to regain functional tissue architecture [10,11]. As a result of altered balance between the formation and breakdown of collagen, abnormal scar formation is observed. Recent studies demonstrate that MMP-9 may be useful marker in diagnosis of oxidative stress [12]. MMP-2 and MMP-9 are elevated in systemic fibrotic diseases like sarcoidosis or in case of lung degradation during the pneumonia process [13,14]. MMP-2 is elevated also in

invasive neoplasms cells [15]. Some characteristics of MMP-2 and MMP-9 are presented in Table 1.

Skin is composed of epidermis (superficial) and dermis (deeper) layers. Epidermis is a regenerative tissue in which the healing results in restoring of function, whereas dermis as a non-regenerative tissue in which repair results in scar formation [16]. Thus research efforts were made to design a scaffold that provides rapid wound closure and enables guided dermal regeneration, resulting in improved outcomes. One of the commercially available dermal scaffolds is the Integra® dermal regeneration template (IDRT). After an implantation into the wound bed, the template induces organized regeneration of normal dermal tissue, allowing migration of the host cells. This results in collagen deposition, vasculogenesis, and template degradation, which last approximately 30 days [17,18]. After that, the top layer of Integra DRT is removed, and a very thin layer of the patient's own epithelial cells is implanted. The skin graft placed onto "neodermis" is thinner than the traditional split thickness skin graft. This 2-stage procedure reconstructs full-thickness skin in about 4 to 5 weeks [19]. The main advantage of Integra DRT treatment is the dermal regeneration without unfavorable scar formation, proved by histology examinations [20,21]. Although, Integra DRT was initially designed for treatment of massive burns, today it is widely used in reconstructive surgery. Indications for reconstructive surgery with Integra® DRT include contracture release procedures, hypertrophic scar excision, giant congenital melanotic naevi, and cancer excisions [22–26]. IDRT produces good functional and aesthetic results and enables reconstruction of large surfaces. It can provide a valuable alternative to flaps, tissue expanders, and full thickness skin grafts, decreasing the severity of donor site scars. Complications in the treatment occur rarely and may include hematoma, seroma, and infection, which result in severe scarring [21,27].

Integra® provides tissue-guided dermal regeneration using collagen fibers of the template to enable specific fibroblast migration, vasculogenesis, and deposition of collagen in a nearly natural way. As a result, an elastic dermal layer is created. Current knowledge about the role of metalloproteinases in dermal wound healing suggests MMP-2 and MMP-9 as key modulators of scar tissue formation and remodeling. To help develop scarless healing therapies, we analyzed the action of selected collagenases in the process of dermal regeneration with Integra®. We hypothesized that dermal regeneration with Integra® uses different molecular mechanisms and is associated with different MMP-2 and MMP-9 levels than those observed in normal wound healing. The primary aim of this study was to investigate plasma levels of selected metalloproteinases in response to Integra® dermal scaffold implantation. Additionally, we aimed to assess the level of inflammation and its influence on scaffold formation and levels of

Table 1. MMP-2 and MMP-9 characteristics.

| Metallo-proteinase | Human chromosome | ECM substrates | Cell interaction | | | General action |
|--------------------|------------------|---|------------------|--------------|--------------------|-----------------|
| | | | Keratinocytes | Dermal cells | Inflammatory cells | |
| MMP-2 | 16q13 | Collagens (type I, II, III, IV, V, VII, X, XI) gelatin, elastin, fibronectin, vitronectin, laminin, entactin, tenascin, aggrecan, link protein, galectin-3, versican, decorin, myelin basic protein | - | + | - | Antinflammatory |
| MMP-9 | 20q11.2q13.1 | Collagens (type IV, V, XI, XIV) gelatin, elastin, vitronectin, laminin, aggrecan, link protein, galectin-3, versican, decorin, myelin basic protein | + | - | + | Proinflammatory |

MMPs. Levels of the investigated MMPs were correlated with levels of IL-4 and TGF-β1 during dermal regeneration progress.

Material and Methods

Patient selection

The project was performed with Jagiellonian University Ethics Committee approval (KBET/72/B/2008). We enrolled 11 pediatric patients who were scheduled for elective reconstructive procedures with Integra®. Indications for use of IDRT were either excessive post-burn scarring (n=7) or congenital giant nevi (n=4). Patients after surgical lesion removal had created full thickness wounds with no distinction between the burn scar and nevi groups. During a single procedure, 150–1000 cm² of Integra® in 1 or multiple regions of the body was implanted. Patient characteristics are presented in Table 2.

The selected patients had no systemic comorbidities or active inflammation. Written informed consents were obtained from the patients' guardians or from the patients themselves if they were over 16 years of age.

Surgical scheme

The surgical treatment was performed according to the Integra® implantation instructions provided by the manufacturer and the authors' experience. During surgery, the excision of the scar or lesion was performed followed by implantation of Integra® Dermal Regeneration Template (Integra Life Sciences Corporation, Plainsboro, New Jersey, USA). After the surgery, patients were monitored as in-patients for 3–7 days and then as out-patients until IDRT-treated wounds were completely healed. Dressings were changed according to the scheme and

Table 2. Patients' characteristics.

| General data | Value |
|--|--------|
| Females/Males | 4/7 |
| Age in years [mean±SEM] | 14±1.8 |
| Post-burn Scar/Giant Bath-nevi | 7/4 |
| Regions of implanted Integra® [no of cases]* | |
| Face | 1 |
| Neck | 3 |
| Upper limb | 1 |
| Breast | 3 |
| Trunk | 5 |

* Some patients were operated on more than one region of the body during one surgery.

wounds were assessed by an experienced surgeon and digital photographs were taken. Wound surface was calculated using Image J® (NIH, USA). Wound infection was confirmed by positive microbiology culture from swabs. White cell counts (WCC) and C-reactive protein (CRP) levels were assessed as part of routine testing.

Blood sampling

Three ml of venous blood were collected from each patient on 4 occasions during the study: day 0 – before surgery (baseline), day 1 – 24 hours after implantation of IDRT, day 7 – before discharge from hospital, and day 25 – after admission for the second stage surgery (before split thickness skin grafting). The blood was collected into 1-mL EDTA vacuum containers (MedLab® Raszyn, Poland). Immediately after the blood was taken, it was centrifuged at 4°C and the plasma was stored at –80°C until analysis.

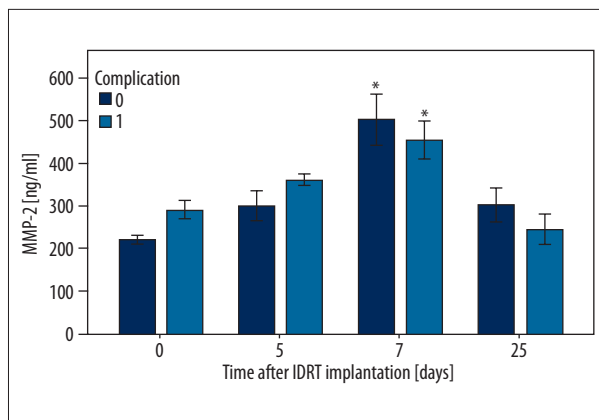


Figure 1. Plasma levels of MMP-2 in patients after Integra® implantation.

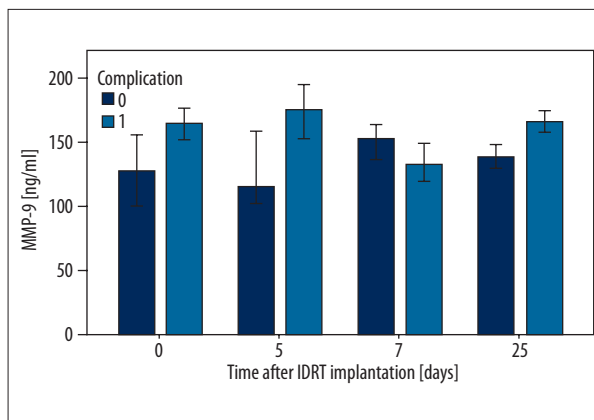


Figure 2. Plasma levels of MMP-9 in patients after Integra® implantation.

Samples analysis

Concentrations of MMP-2 and MMP-9 in plasma were quantitated with a commercial enzyme-linked immunosorbent assays (ELISA: R&D® Systems, Minneapolis, USA). Levels of IL-4 and TGF-β1 were quantitated with a Multiplex® Assay (Invitrogen, Paisley, UK) using the Luminex® 100™ instrument. All reaction steps were performed according to the manufacturers’ protocols.

Statistical analysis

SPSS® 18 statistical software was used to perform statistical analysis. To compare means, student’s t-test and one-way analysis of variance with post-hoc Scheffe test were used. For correlation analysis, the Pearson correlation test was used. The level of significance for all statistical tests was p<0.05. Values in the text, tables, and figures are presented as mean ± standard error of the mean (SEM).

Results

The mean surface area of implanted IDRT was 495±72cm² with the average take rate at the level of 89.5±4.7%. The mean time to heal of implanted IDRT, which was defined as number of days from IDRT placement to split thickness skin graft placement, was 29.1±1.4 days. Four patients (36%) developed local infection, confirmed by Gram-positive organism growth in wound swabs. Due to the lack of a true control group, patients with local infections were considered further as a group with complications, and were compared to patients who did not develop infection (group without complications). Patients with complications had reduced IDRT take rate compared to patients without complications (71.5±5.4 vs. 100±0.1; p<0.005).

Significantly elevated levels of MMP-2 on day 7 comparing to baseline (day 0) (p<0.05) were observed in both groups (Figure 1). Elevated MMP-2 levels were present among patients with and without complications, with no significant difference between the groups. Elevated MMP-2 levels were observed on day 1 after the surgery in both groups, but this was not statistically significant. Levels of MMP-9 remained similar, with surprisingly low levels at day 7 in the group with complications, but these changes were non-significant (Figure 2).

Statistical analysis showed that there was no significant correlation in plasma levels of MMP-2 and MMP-9 at any time-point after IDRT placement for patients with and without complications.

As previously presented [28], systemic inflammation was confirmed by significantly elevated IL-4, which on day 7 was significantly higher (p<0.05) among patients with complications. High levels of this cytokine were also observed on day 25, but without significance. Levels of WCC and CRP remained non-elevated in the analyzed period. Levels of TGF-β1 were elevated among patients with complications at all time-points after the surgery, but it was not statistically significant.

The further analysis revealed positive (R²=0.466) linear correlation of plasma concentration of IL-4 and MMP-2 in the group with complications, which was statistically significant (p=0.037) (Figure 3). Additionally, we found positive (R²=0.119) correlation of TGF-β1 and MMP-9 in both groups of patients, which was statistically significant (p=0.012) (Figure 4).

Discussion

Metalloproteinases are important components in many biological and pathological processes mainly because of their role in degradation of ECM components and ability to influence the process of inflammation. These molecules play crucial roles in

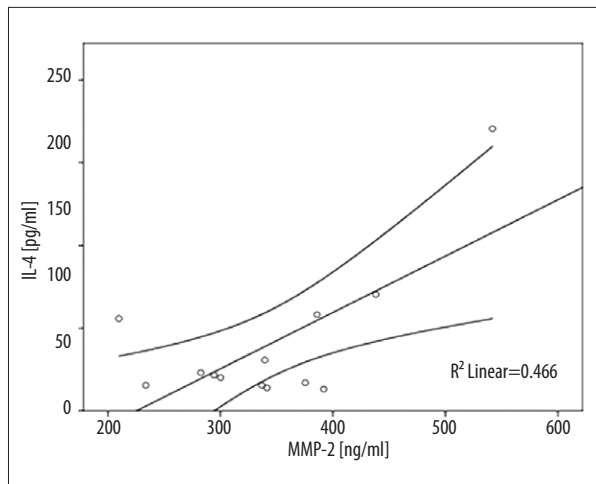


Figure 3. Correlation of plasma levels of IL-4 and MMP-2 in patients after Integra® implantation who developed complications.

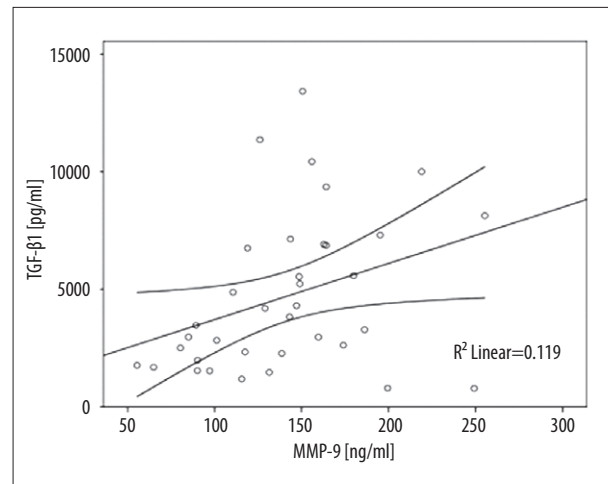


Figure 4. Correlation of plasma levels of TGF-β1 and MMP-9 in patients after Integra® implantation.

early and late stages of wound healing [8,29]. Because normal wound healing results in scar formation, many studies are investigating wound repair and regeneration to improve outcomes.

Dermal regeneration with Integra® results in reduced scarring and in this study we focused on systemic response to this material. Previous studies have shown that metalloproteinases play an important role in wound healing, which is why the present study was undertaken.

In this study, for the first time, plasma levels of metalloproteinases-2 and -9 in patients after Integra® dermal regeneration template implantation were measured. Plasma of 11 patients with significant surface of implanted IDRT was analyzed. Patients were divided into 2 groups according to presence or absence of complications. Results were correlated with serum levels of inflammatory cytokine IL-4 and proliferative growth factor TGF-β1.

Our study revealed significantly elevated levels of MMP-2 in both group of patients after Integra® implantation, compared to levels before the surgery. This strongly suggests that MMP-2 is involved in degradation of the Integra® scaffold. The highest level of this protease was detected on day 7, which is in accordance with other results of other authors and clinical practice, which state that degradation of IDRT starts at day 5–7 [19]. During our study, 4 patients developed local infection that resulted in significantly reduced Integra® take rate, prolonged hospitalization, and scarring. A strong positive correlation between levels of IL-4 and MMP-2 was observed in patients who developed complications. According to our results, even during early stages of inflammation among patients with complications, levels of MMP-2 remained elevated. This result is in contrast to other studies, in which patients with infection had decreased levels of MMP-2 [30]. This suggests that anti-inflammatory MMP-2 action has an opposing

role in the presence of the Integra® dermal scaffold. We observed that MMP-2 presents a consistently negative correlation with MMP-9 in the early days of wound healing. Our results did not reveal any correlation of MMP-2 and MMP-9 at any time-point, which supports the theory that dermal regeneration with Integra® uses different mechanisms than are found in normal wound healing.

Systemic levels of MMP-9 remained at levels similar to baseline during the course of Integra® healing. We did not observe any changes in the concentration of this molecule, even among patients who developed complications. This suggests that MMP-9 as a pro-inflammatory molecule and protease is not associated with degradation of Integra®. It also supports the theory that Integra® has anti-inflammatory action [17].

We found a positive correlation of plasma concentration of MMP-9 and TGF-β1 in patients with and without complications. This result is in line with findings of other authors and suggests that elevated levels of these molecules predict prolonged wound healing and poor outcome [31–33]. Excessive scarring observed in patients with infected wounds is a result of higher fibroblast activity mediated by TGF-β1, moreover, other studies found that inhibition of MMPs can result in prolonged and impaired wound healing [34].

Conclusions

Our study shows that MMP-2 plays an important role in dermal regeneration with Integra®. These findings suggest that the Integra® scaffold is decomposed mainly by MMP-2, whereas MMP-9 may be associated with fibrosis and scarring. Potential therapies for reducing scar formation during wound repair are under investigation. Metalloproteinases, due to their diversity of action during wound healing, are attractive targets for future

pharmacotherapy to reduce scarring. Understanding the role of these molecules in normal and pathological wound healing is a key to design scarless therapies in the future.

References:

1. Grutner GC, Werner S, Barrandon Y, Longaker MT: Wound repair and regeneration. *Nature*, 2008; 453: 315–21
2. Singer AJ, Clark RA: Cutaneous wound healing. *N Engl J Med*, 1999; 341: 738–46
3. Velnar T, Bailey T, Smrkolj V: The wound healing process: an overview of the cellular and molecular mechanisms. *J Int Med Res*, 2009; 37: 1528–42
4. Nagase H, Woessner JF: Matrix metalloproteinases. Minireview. *J Biol Chem*, 1999; 274(31): 21491–94
5. Page-McCaw A, Ewald A, Werb Z: Matrix metalloproteinases and the regulation of tissue remodeling. *Nat Rev Mol Cell Biol*, 2007; 8(3): 221–33
6. Soo C, Shaw W, Zhang X et al: Differential Expression of Matrix Metalloproteinases and Their Tissue-Derived Inhibitors in Cutaneous Wound Repair. *Plast Reconstr Surg*, 2000; 105(2): 638–47
7. Madlener M, Parks WC, Werner S: Matrix metalloproteinases (MMPs) and their physiological inhibitors (TIMPs) are differentially expressed during excisional skin wound repair. *Exp Cell Res*, 1998; 242: 201–10
8. Parks W, Wilson C, López-Boado Y: Matrix metalloproteinases as modulators of inflammation and innate immunity. *Nature Rev Immunol*, 2004; 4: 617–29
9. Gillard JA, Reed MW, Buttle D et al: Matrix metalloproteinase activity and immunohistochemical profile of matrix metalloproteinase-1 and -9 and tissue inhibitor of metalloproteinase-1 during dermal wound healing. *Wound Repair Regen*, 2004; 12(3): 295–304
10. Parks WC: Matrix metalloproteinases in repair. *Wound Repair Regen*, 1999; 7(6): 423–32
11. Visse R, Nagase H: Matrix metalloproteinases and tissue inhibitors of metalloproteinases. Structure, function and biochemistry. *Circ Res*, 2003; 92(8): 827–39
12. Volna J, Kemlink D, Kalousova M et al: Biochemical oxidative stress-related markers in patients with obstructive sleep apnea. *Med Sci Monit*, 2011; 17(9): CR491–97
13. Piotrowski W, Gorski P, Pietras T et al: The selected genetic polymorphisms of metalloproteinases MMP2, 7, 9 and MMP inhibitor TIMP2 in sarcoidosis. *Med Sci Monit*, 2011; 17(10): CR598–607
14. Puljiz I, Markotic A, Krajinovic L et al: Mycoplasma pneumoniae is adult community-acquired pneumonia increases matrix metalloproteinase-9 serum level and induces its gene expression in peripheral blood mononuclear cells. *Med Sci Monit*, 2012; 18(8): CR500–5
15. Partyka R, Gonciarz M, Jałowicki P et al: VEGF and metalloproteinase 2 (MMP 2) expression in gastric cancer tissue. *Med Sci Monit*, 2012; 18(4): BR130–34
16. Yannas I: Tissue and organ regeneration in adults. New York, USA: Springer-Verlag, 2001
17. Yannas IV, Burke JF: Design of an artificial skin. I. Basic design principles. *J Biomed Mat Res*, 1980; 1(14): 65–81
18. Yannas IV, Burke JF, Gordon PL, Rubenstein RH: Design of an artificial skin. II. Control of chemical composition. *J Biomed Mat Res*, 1980; 1(14): 107–31
19. Stern R, McPherson M, Longaker MT: Histologic study of artificial skin used in the treatment of full-thickness thermal injury. *J Burn Care Rehab*, 1990; 11(1): 7–13
20. Burke J, Yannas I, Quinby C et al: Successful use of a physiologically acceptable artificial skin in the treatment of extensive burn injury. *Ann Surg*, 1981; 194: 413–28
21. Moiemien N, Staiano J, Ojeh N et al: Reconstructive surgery with Integra Dermal Regeneration Template: histologic study, clinical evaluation and current practice. *Plast Reconstr Surg*, 2006; 117: 1605–74S
22. Dantzer E, Querel L, Salinier L et al: Integra®, a new surgical alternative for the treatment of massive burns. Clinical assessment of acute surgery and reconstructive surgery: on 39 cases. *Ann Chir Plast Esthet*, 2001; 46: 173–89
23. Frame J, Still J, Lakhel-LeCoadou A et al: Use of Dermal Regeneration Template in Contracture Release Procedures: A Multicenter Evaluation. *Plast Reconstr Surg*, 2004; 5(113): 1330–38
24. Campitello E, Della Corte A, Fattopace A et al: The use of artificial dermis in the treatment of chronic and acute wounds: regeneration of dermis and wound healing. *Acta Biomed*, 2005; 76: 69–71
25. Tufaro A, Buck D, Fischer A: The use of artificial dermis in the reconstruction of oncologic surgical defects. *Plast Reconstr Surg*, 2007; 120(6): 638–46
26. Schiestl C, Stiefel D, Meuli M: Giant naevus, giant excision, eleg(i)ant closure? Reconstructive surgery with Integra Artificial Skin to treat giant congenital melanocytic naevi in children. *J Plast Recon Aesthet Surg*, 2010; 63(4): 610–15
27. Heimbach D, Luteran A, Burke J et al: Artificial dermis for major burns. A multi-center randomized clinical trial. *Ann Surg*, 1988; 208(3): 313–20
28. Nessler M, Puchala J, Wood FM et al: Changes in the plasma cytokine and growth factor profile are associated with impaired healing in pediatric patients treated with INTEGRA® for reconstructive procedures. *Burns*, 2013; 39: 667–73
29. Stamenkovic I: Extracellular matrix remodelling: The role of matrix metalloproteinases. *J Pathol*, 2003; 200: 448–64
30. Loo WT, Sasano H, Chow LW: Pro-inflammatory cytokine, matrix metalloproteinases and TIMP-1 are involved in wound healing after mastectomy in invasive breast cancer patients. *Biomed Pharmacother*, 2007; 61(9): 548–52
31. Wysocki AB, Staiano-Coico L, Grinnell F: Wound fluid from chronic leg ulcers contains elevated levels of metalloproteinases MMP-2 and MMP-9. *J Invest Dermatol*, 1993; 101(1): 64–68
32. Yu Q, Stamenkovic I: Cell surface-localized matrix metalloproteinase-9 proteolytically activates TGF-beta and promotes tumor invasion and angiogenesis. *Genes Dev*, 2000; 14: 163–76
33. Hahm G, Glaser JJ, Elster EA: Biomarkers to Predict Wound Healing: The Future of Complex War Wound Management. *Plast Reconstr Surg*, 2011; 127(1): 215–265
34. Mirastschijski U, Schnabel R, Claes J et al: Matrix metalloproteinase inhibition delays wound healing and blocks the latent transforming growth factor-b1-promoted myofibroblast formation and function. *Wound Rep Reg*, 2010; 18: 223–34

Statement

All authors declare no conflict of interest.