

Correlation between the cervical sagittal alignment and spine - pelvic sagittal alignment in asymptomatic adults

ABSTRACT

Background: Although there are studies that adequately document the linear correlation between pelvic incidence (PI), sacral slope, lumbar lordosis, and thoracic kyphosis, few have analyzed the pelvic-spine correlation including the cervical spine.

Methods: This is a cross-sectional study, wherein the cervical spine was evaluated using radiography and computed tomography (CT) scans, the lumbosacral spine and the pelvis was evaluated using radiography, in adult patients without spinal pathology. Using the Surgimap tool, cervical and spinopelvic parameters were calculated by several investigators. To evaluate the correlation between cervical and spinopelvic parameters, Spearman's coefficient was calculated. To evaluate the concordance correlation of the measured parameters of cervical sagittal alignment on tomography and conventional radiography, Lin's coefficient was calculated and Bland-Altman plots were performed.

Results: A total of 51 healthy adults were included in a follow-up from January 2019 to December 2020. Cervical sagittal alignment and sagittal spinopelvic alignment were assessed using radiography, and a correlation was observed between T1 slope (T1S) and lumbar mismatch (coefficient of 0.28, $P = 0.047$). Then, cervical sagittal alignment was evaluated using CT and sagittal spinopelvic alignment using radiography, and no correlation was observed between PI and thoracic inlet angle or cervical mismatch with lumbar mismatch.

Conclusion: In asymptomatic patients, in whom cervical sagittal alignment and spinal-pelvic alignment were evaluated, only a positive correlation was found between lumbar mismatch and T1S, which lacks clinical significance. No concordance was identified between lumbar mismatch and cervical mismatch. Therefore, it is inferred that there is an independence between the sagittal spine-pelvic alignment with respect to the sagittal cervical alignment.

Keywords: Cervical mismatch, cervical sagittal alignment, lumbar mismatch, spinopelvic sagittal alignment

**JUAN ESTEBAN MUÑOZ MONTOYA^{1,2,3},
ANDRÉS FELIPE VARGAS ROSALES⁴,
DIANA PAOLA DUARTE MORA⁴,
JOHAN DAVID SERRATO PERDOMO⁴,
GABRIEL VARGAS ROSALES⁴, GERARDO ARDILA DUARTE⁵,
ERIK EDGARDO MUÑOZ RODRÍGUEZ⁶**

¹Neurosurgeon, Universidad Militar Nueva Granada, Bogotá, Colombia, ²Master in Spine Surgery, Universidad Cardenal Herrera, Valencia, Spain, ³Member of the AOSpine, Member of the North America Spine Society, Member of the World Spinal Column Society, Member Candidate Fellow Active, SRS: Scoliosis Research Society, ⁴Department of Neurosurgery, Neurosurgery Resident, Universidad Militar Nueva Granada, Bogota, Colombia, ⁵Biostatistical Engineer, Msc Statistics UNAL, Msc Quality and Production ITESM Mexico, Black Belt Six Sigma Arizona, USA, ⁶Department of Neurosurgery, Neurosurgeon Graduated from Universidad Militar Nueva Granada, Vice Chancellor of the School of Medicine, Universidad Militar Nueva Granada, Bogota, Colombia

Address for correspondence: Dr. Juan Esteban Muñoz Montoya, Universidad Militar Nueva Granada, Bogotá, Colombia. Master in Spine Surgery, Universidad Cardenal Herrera, Valencia, Spain.
E-mail: juanesteban1285@gmail.com

Submitted: 28-May-22

Accepted: 19-Jul-22

Published: 14-Sep-22


This is an open access journal, and articles are distributed under the terms of the Creative Commons Attribution-NonCommercial-ShareAlike 4.0 License, which allows others to remix, tweak, and build upon the work non-commercially, as long as appropriate credit is given and the new creations are licensed under the identical terms.

For reprints contact: WKHLRPMedknow_reprints@wolterskluwer.com

How to cite this article: Muñoz Montoya JE, Vargas Rosales AF, Duarte Mora DP, Serrato Perdomo JD, Vargas Rosales G, Ardila Duarte G, *et al.* Correlation between the cervical sagittal alignment and spine - pelvic sagittal alignment in asymptomatic adults. *J Craniovert Jun Spine* 2022;13:339-43.

INTRODUCTION

The evaluation of global sagittal balance in patients with spinal deformities has gained importance, due to its impact on quality of life and its correlation with disability indexes.^[1] However, the correlation of spinopelvic alignment with cervical spine has not been studied in depth.

Access this article online	
Website: www.jcvjs.com	Quick Response Code 
DOI: 10.4103/jcvjs.jcvjs_73_22	

A very important parameter when analyzing the cervical sagittal alignment of a patient is the cervical mismatch, which arises from the need of spine surgeons to reestablish a physiological cervical lordosis (CL) value when operating the cervical spine.^[2] Therefore, it was defined that the cervical mismatch is the result of the subtraction of the T1 of slope (T1S) with respect to the CL (T1S – CL); in the general population, its value is 16.5° ± 2° with a range between 14.5° and 26.5°.^[2] If this parameter is not taken into account, this can generate complications such as residual deformity or iatrogenic deformity at the time of performing procedures on the cervical spine.^[2]

Another parameter of great relevance in cervical sagittal alignment is the T1S. T1S is considered to be the biomechanical variable of the cervical spine, which integrates the cervical spine and thoracolumbar pelvic parameters; if T1S is < 16.5°, it indicates that the cervical spine has a kyphotic cervical sagittal alignment.^[2]

Although several studies have documented the linear correlation between pelvic incidence (PI), sacral slope (SS), lumbar lordosis (LL), and thoracic kyphosis, few have analyzed the pelvic-spine correlation including the cervical spine.^[3]

In this study, the aim is to evaluate the correlation between cervical sagittal alignment measured in conventional radiography and computed tomography (CT) with respect to the sagittal spino - pelvic alignment measured in conventional radiography.

METHODS AND STATISTIC ANALYSIS

This was a cross-sectional study. Patients without spinal pathology who had consulted the Neurosurgery Service of the “Hospital Militar Central” between 2019 and 2020, for other reasons unrelated to the spine, were included. Patients over 18 years of age, without spinal pathology, and with signature of informed consent to perform studies were

included. Patients with previous cervical or lumbar spine surgery were excluded.

Subjects who agreed to participate underwent panoramic spine radiographs, cervical spine radiographs, and cervical spine CT scans in compliance with positioning standards. One investigator performed all measurements in a blinded manner (without knowing which patient the images belonged to or the measurements taken on the other images) using the Surgimap tool (Company: Nemaris Inc, 2008, Methuen, Massachusetts, USA), was developed by a group of spine surgeons, researchers, and engineers to function as a standalone, freeware application. The following parameters were measured for cervical sagittal alignment: T1S, neck tilt (NT), thoracic inlet angle (TIA), and CL; for the calculation of cervical mismatch, the formula was used: T1S – CL. For the calculation of sagittal spinopelvic alignment, the following parameters were measured: SS, pelvic tilt, PI, and LL; for the calculation of lumbar mismatch, the formula was used: PI – LL.

For the sample size calculation, the correlation coefficient between thoracic and cranial inlet angle $r = 0.624$ was taken as a reference;^[3] with a bilateral approach, 95% confidence with a power of 70%, a sample of 50 patients was determined.

Data exploration analysis was used to describe the sample, the mean and confidence intervals (CIs) were calculated for each of the measurements, and the paired sample *t*-test was used to compare means. Spearman’s correlation analysis was performed to determine the correlation between cervical sagittal and pelvic-spine balance. To compare cervical sagittal balance measurements using radiography versus tomography, Lin’s coefficient was determined and Bland–Altman plots were performed. Analyses were performed in SPSS software version 25.0 (Company: IBM, IBM SPSS Statistics 25. 0, March 2017, Armonk, New york) is the world’s leading statistical software used to solve business and research problems by

Table 1. Sagittal spino-pelvic alignment, cervical sagittal alignment characteristics, analyzed in radiography and computed tomography.

	Radiography		Computed Tomography		Difference of means		P
	Mean	IC95%	Mean	IC95%	Mean	IC95%	
Cervical Sagittal Alignment							
T1 Slope	35,20	(30,42 a 39,98)	33,43	(30,64 a 36,22)	1,77	(-2,99 a 6,54)	0,132
Neck tilt	52,14	(48,84 a 55,44)	52,20	(48,89 a 55,51)	-0,06	(-2,71 a 2,59)	0,989
Thoracic Inlet angle	89,05	(84,83 a 93,27)	86,07	(82,33 a 89,82)	2,97	(0,29 a 5,66)	0,050
Cervical mismatch	1,96	(-2,25 a 6,16)	4,78	(1,61 a 7,96)	-2,82	(-6,14 a 0,48)	0,137
Sagittal Spino-pelvic Alignment							
Sacral slope	34,72	(32,37 a 37,08)					
Pelvic tilt	17,16	(13,94 a 20,38)					
Pelvic incidence	52,09	(48,17 a 56,00)					
Lumbar mismatch	2,84	(-0,81 a 6,50)					

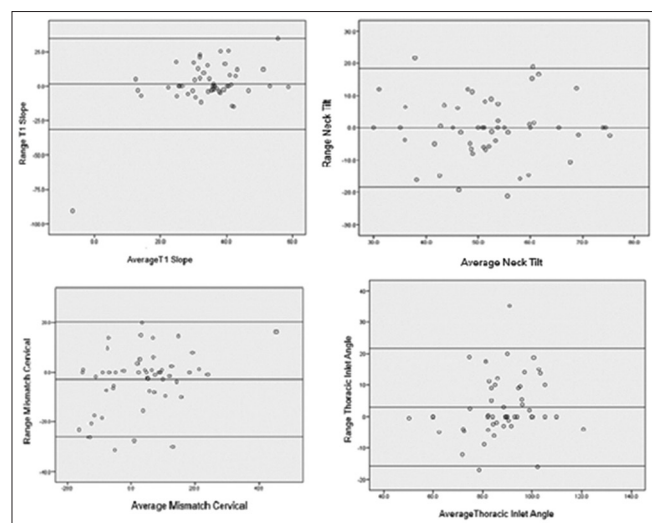
means of ad-hoc analysis, hypothesis testing, and predictive analytics.

RESULTS

Fifty-one subjects were included, comprising 17 women (33.3%) and 34 men (66.7%) with an average age of 60.6 (standard deviation 20.3) years and a range of 20–88 years.

In the cervical sagittal alignment measured on radiography, an average NT of 52.14° (95% CI 48.84° to 55.44°) and an average cervical mismatch of 1.96° (95% CI -2.25° to 6.16 °) were measured; on the other hand, on tomography, the average NT was 52.20° (95% CI 48.89° to 55.51°) and the average cervical mismatch was 4.78° (95% CI 1.61° to 7.96°). In sagittal spinopelvic alignment, an average IP of 52.09° (95% CI 48.17° to 56.00°) and an average lumbar mismatch of 2.84° (95% CI -0.81° to 6.50°) were measured. Table 1 describes the cervical sagittal alignment parameters measured on both radiography and CT scans and also the sagittal spinopelvic alignment parameters measured on radiography.

When comparing the parameters of cervical sagittal alignment measured by CT and radiography, it was observed that the measurements with the greatest difference were TIA (mean difference of 2.97°; 95% CI 0.29° to 5.66°) and cervical mismatch (mean difference of -2.82°; 95% CI -6.14° to 0.48°); however, these differences were not statistically significant. The concordance correlation between the cervical sagittal alignment parameters that were measured on CT and radiography were evaluated with Bland–Altman plots [Graph 1] and Lin’s concordance correlation coefficient. For NT, the Lin’s coefficient was 0.678 (95% CI 0.527–0.829);



Graph 1: Bland–Altman plots for the parameters measured in radiography (R) and by tomography (T) of the cervical sagittal alignment

for T1S, it was 0.257 (95% CI 0.033–0.480), which speaks of a mild concordance correlation and variability of the values in Graph 1; for cervical mismatch, it was 0.591 (95% CI 0.423–0.759), and for TIA, it was 0.756 (95% CI 0.640–0.872), which infers that there is no difference between the parameters measured both in radiography and CT of the cervical sagittal alignment.

With the parameters obtained by radiographic measurement, we sought to establish if there was a correlation between cervical sagittal alignment and sagittal spine-pelvic alignment. A correlation was observed between T1S and lumbar mismatch (coefficient of 0.28; $P = 0.047$). No correlation was observed between PI and TIA nor of cervical mismatch with lumbar mismatch [Table 2].

When evaluating the parameters obtained by measuring cervical sagittal alignment by CT and sagittal spinopelvic

Table 2. Correlation between cervical sagittal alignment and sagittal spino-pelvic alignment with parameters measured on radiography.

	Neck Tilt	T1 Slope	Cervical Mismatch	Thoracic Inlet Angle
Sacral Slope				
Pearson Correlation	-0,019	-0,140	-0,019	-0,143
Sig. (2-tailed)	0,894	0,326	0,895	0,318
Pelvic Tilt				
Pearson Correlation	-0,025	0,151	-0,061	0,064
Sig. (2-tailed)	0,861	0,290	0,671	0,654
Pelvic Incidence				
Pearson Correlation	-0,019	0,043	-0,075	-0,021
Sig. (2-tailed)	0,894	0,766	0,599	0,881
Lumbar Mismatch				
Pearson Correlation	-0,123	,280(*)	0,079	-0,021
Sig. (2-tailed)	0,390	0,047	0,584	0,885

Table 3. Correlation between cervical sagittal alignment measured by CT scan and sagittal spino-pelvic alignment measured by radiography.

	Neck Tilt	T1 Slope	Cervical Mismatch	Thoracic Inlet Angle
Sacral Slope				
Pearson Correlation	0,031	-0,118	-0,194	-0,105
Sig. (2-tailed)	0,830	0,410	0,173	0,463
Pelvic tilt				
Pearson Correlation	-0,030	-0,057	0,184	-0,071
Sig. (2-tailed)	0,834	0,691	0,197	0,622
Pelvic Incidence				
Pearson Correlation	0,019	-0,129	0,048	-0,108
Sig. (2-tailed)	0,894	0,366	0,740	0,452
Lumbar Mismatch				
Pearson Correlation	-0,116	0,030	0,096	-0,087
Sig. (2-tailed)	0,417	0,837	0,503	0,543

alignment measured by radiography, neither correlation was observed between IP and TIA, nor between cervical mismatch and lumbar mismatch [Table 3].

DISCUSSION

The maintenance of horizontal gaze is essential to maintain functionality in daily activities, so a physiological sagittal alignment of the head and neck is necessary to maintain an adequate quality of life. The cervical spine is the part of the spine with the greatest mobility in the sagittal plane, especially at the craniocervical junction (C0–C2); therefore, in degenerative disease, the cervical spine is responsible for compensatory mechanisms to maintain horizontal gaze; these compensatory changes are associated with neck pain, interscapular pain, and headache.^[4,5]

The prevalence of neck pain is approximately 5% and occurs frequently in patients with sagittal balance disturbances, so understanding its pathophysiology is essential to provide efficient and cost-effective management. Among the poor prognostic cervical sagittal alignment parameters are: C7 slope $>20^\circ$, T1S $>25^\circ$, and cervical sagittal alignment (sagittal vertical axis) C2–C7 >4 cm.^[5,6]

When there is an increase in the sagittal vertical axis (SVA) C2–C7, a hyperextension in C0–C2 and a compensatory flexion in C2–C7 are generated to maintain the gaze in the horizontal plane. These compensatory changes associated with degenerative disease (loss of intervertebral disc height, progression of thoracic kyphosis, and facet laxity) cause structural changes that result in compression of neural structures with subsequent radiculopathy or myelopathy; in addition, changes occur in the cervical musculature generating contractures that are associated with trigger points for headache and neck pain.^[6]

SVA and T1S are strongly related since studies have shown that patients with a T1S $>25^\circ$ have at least 10 cm of VAS while those with a T1S $<13^\circ$ correlate with a negative VAS. However, one of the main complications in patients with an altered cervical VAS is the adjacent segment, which consists of development of neurological symptoms such as radiculopathy or myelopathy of the immediately involved segments both superiorly or inferiorly of a previous fixation due to the deterioration of the discs or ligaments.^[7]

For the measurement of these parameters of cervical sagittal alignment, conventional radiography is used; however, in some patients with unfavorable anatomy, such as a short neck, which does not allow or visualize the vertebral body

of T1 and even C7 vertebral body, so the idea of studying it in computed axial tomography was born, so several studies were developed, to find if there was difference in being measured in the two methods, such as the study of Wang *et al.*, in which they analyzed 60 cases of cervical degenerative spondylolisthesis versus control using studies such as radiology and CT for cervical sagittal alignment and found a correlation of the cervical parameters measured by CT and with radiography.^[8]

The compensatory mechanisms in the cervical spine and outside the cervical spine have been supported by several studies, as for example, a simple kyphosis is compensated in the upper and lower segments, as a hyperlordosis in the upper cervical spine and vice versa. Cervical kyphotic changes are compensated with thoracic hypokyphosis to maintain the economy cone of the global sagittal balance.^[9]

It has been described that increasing the lumbar mismatch (PI – LL) increases compensatory mechanisms such as pelvic retroversion, reduction of thoracic kyphosis, increased knee flexion, and pelvic displacement.^[11] This indicates that multiple factors are responsible for achieving proper sagittal alignment in the spine.^[11,10,11]

There is an interesting point, in which there is no direct correlation between CL and LL in the studies of cervical sagittal alignment including thoracolumbar sagittal and pelvic alignment.^[12] Currently, the discussion persists as to whether or not there is a direct correlation between the spine-pelvic and cervical parameters, as for example the study by Lee *et al.* where a sequential relationship was found between the spine-pelvic, thoracic, but no relationship was identified between segmental parameters such as LL with CL, omitting the other parameters.^[13] Another study such as Diebo *et al.*, in 2016, proposed a cervical sagittal alignment based on sagittal thoracolumbar alignment as $CL = 10 - (LL - \text{thoracic kyphosis})/2$ but requires further additional studies.^[14]

In the present study, the parameters obtained by measuring the cervical sagittal alignment on radiography and CT and correlating it with the sagittal spinopelvic alignment. No direct correlation was observed between the spinopelvic parameters and the cervical parameters.

In relation to the complications associated with the results of cervical mismatch and lumbar mismatch, these may predispose to complications such as adjacent segment, proximal function kyphosis, and pseudarthrosis which may result in proximal function failure.^[15-17] However, in the present study, it was not possible to establish a direct

correlation between the cervical mismatch and the lumbar mismatch, behaving as independent segments.

CONCLUSIONS

In asymptomatic patients, in whom cervical sagittal alignment and spinal-pelvic alignment were evaluated, only a positive correlation was found between lumbar mismatch and T1S, which lacks clinical significance. No concordance was identified between lumbar mismatch and cervical mismatch. Therefore, it is inferred that there is an independence between the sagittal spine-pelvic alignment with respect to the sagittal cervical alignment.

There is no difference in the calculation of cervical sagittal alignment parameters in imaging studies both in radiography and computed axial tomography.

Acknowledgment

We would like to acknowledge Diego Alejandro Muñoz Montoya, Víctor Elías Arrieta María, and Linda Margarita Ibatá Bernal for their enormous contribution and help in proofreading the article.

Financial support and sponsorship

Nil.

Conflicts of interest

There are no conflicts of interest.

REFERENCES

- Merrill R, Kim J, Leven D. Beyond pelvic incidence-lumbar lordosis Mismatch: The importance of assessing the entire spine to achieve global sagittal alignment. *Glob Spine J* 2017;7:536-42.
- Staub BN, Lafage R, Kim HJ, Shaffrey CI, Mundis GM, Hostin R, *et al.* Cervical mismatch: The normative value of T1 slope minus cervical lordosis and its ability to predict ideal cervical lordosis. *J Neurosurg Spine* 2018;30:31-7.
- Lee SH, Kim KT, Seo EM, Suk KS, Kwack YH, Son ES. The influence of thoracic inlet alignment on the craniocervical sagittal balance in asymptomatic adults. *J Spinal Disord Tech* 2012;25:E41-7.
- Patwardhan AG, Havey RM, Khayatzaeh S, Muriuki MG, Voronov LI, Carandang G, *et al.* Postural consequences of cervical sagittal imbalance: A novel laboratory model. *Spine (Phila Pa 1976)* 2015;40:783-92.
- Ling FP, Chevillotte T, Leglise A, Thompson W, Bouthors C, Le Huec JC. Which parameters are relevant in sagittal balance analysis of the cervical spine? A literature review. *Eur Spine J* 2018;27:8-15.
- Patwardhan AG, Khayatzaeh S, Havey RM, Voronov LI, Smith ZA, Kalmanson O, *et al.* Cervical sagittal balance: A biomechanical perspective can help clinical practice. *Eur Spine J* 2018;27:25-38.
- Hilibrand AS, Robbins M. Adjacent segment degeneration and adjacent segment disease: The consequences of spinal fusion? *Spine J* 2004;4:190S-194S.
- Wang Q, Wang XT, Zhu L, Wei YX. Thoracic inlet parameters for degenerative cervical spondylolisthesis imaging measurement. *Med Sci Monit* 2018;24:2025-30.
- Protosaltis T, Bronsard N, Soroceanu A, Henry JK, Lafage R, Smith J, *et al.* Cervical sagittal deformity develop after PJK thoracolumbar deformity correction: Radiographic analysis utilizing a novel global sagittal angular parameter, the CTPA. *Eur Spine J* 2017;26:1111-20.
- Schwab F, Patel A, Ungar B, Farcy JP, Lafage V. Adult spinal deformity-postoperative standing imbalance: How much can you tolerate? An overview of key parameters in assessing alignment and planning corrective surgery. *Spine (Phila Pa 1976)* 2010;35:2224-31.
- Lafage V, Schwab F, Patel A, Hawkinson N, Farcy JP. Pelvic tilt and truncal inclination: Two key radiographic parameters in the setting of adults with spinal deformity. *Spine (Phila Pa 1976)* 2009;34:E599-606.
- Smith JS, Lafage V, Schwab FJ, Shaffrey CI, Protosaltis T, Klineberg E, *et al.* Prevalence and type of cervical deformity among 470 adults with thoracolumbar deformity. *Spine (Phila Pa 1976)* 2014;39:E1001-9.
- Lee SH, Son ES, Seo EM, Suk KS, Kim KT. Factors determining cervical spine sagittal balance in asymptomatic adults: Correlation with spinopelvic balance and thoracic inlet alignment. *Spine J* 2015;15:705-12.
- Diebo BG, Challier V, Henry JK, Oren JH, Spiegel MA, Vira S, *et al.* Predicting cervical alignment required to maintain horizontal gaze based on global spinal alignment. *Spine (Phila Pa 1976)* 2016;41:1795-800.
- Rothenfluh DA, Mueller DA, Rothenfluh E, Min K. Pelvic incidence-lumbar lordosis mismatch predisposes to adjacent segment disease after lumbar spinal fusion. *Eur Spine J* 2015;24:1251-8.
- Mendoza-Lattes S, Ries Z, Gao Y, Weinstein SL. Proximal junctional kyphosis in adult reconstructive spine surgery results from incomplete restoration of the lumbar lordosis relative to the magnitude of the thoracic kyphosis. *Iowa Orthop J* 2011;31:199-206.
- Amabile C, LeHuec JC, Skalli W. Invariance of head-pelvis alignment and compensatory mechanism for asymptomatic adults older than 49 years. *Eur Spine J* 2016;25:3630-7.