

## Anesthetic management of craniopagus conjoined twins in a remote location

Sir,

Conjoined twins are one of the most fascinating human malformations. They result from an aberrant twinning process with incomplete fission of the zygote's primitive streak at 20 days of ovulation. Their incidences are very rare (1:200,000) in live births.<sup>[1]</sup> They are classified on the basis of the site of union as thorax - 40% (thoracopagus), upper abdomen - (xiphopagus) or lower abdomen - (omphalopagus) 33%, sacrum - 19% (pyopagus), pelvis - 6% (ischiopagus), or skull - 2% (craniopagus).<sup>[2-5]</sup> We report the anesthetic management for cerebral angiogram of craniopagus twins.

The 12-year-old female, craniopagus twins were admitted for cerebral angiogram. We named twins as V1 and V2 for ease of documentation. Preoperative assessment was done. V1 was 45 kg in weight whereas V2 was only 40 kg. They had no significant medical history. On investigation, no biochemical and hematological abnormalities were detected. A complete cardiac workup with electrocardiogram (ECG) and echocardiogram tests also revealed normal result.

The interventional radiology suite in our institute has a single Boyle's basic anesthesia machine with three parameter Datex-Ohmeda monitor. A day prior to the scheduled procedure, another workstation with multichannel monitoring shifted to the location. After connecting to the gas pipelines, satisfactory working status was confirmed and documented. All anesthesia equipment (airway, drug trays, resuscitation, and suction apparatus) were also duplicated. Two anesthesia teams were formed and a mock drill was rehearsed a day prior, to ensure the feasibility and safety of anesthesia.

Twins were placed in supine position with legs facing in the opposite direction [Figure 1]. Separate intravenous (IV) access secured for both with 20-gauge IV cannula and monitoring included heart rate, ECG, noninvasive blood

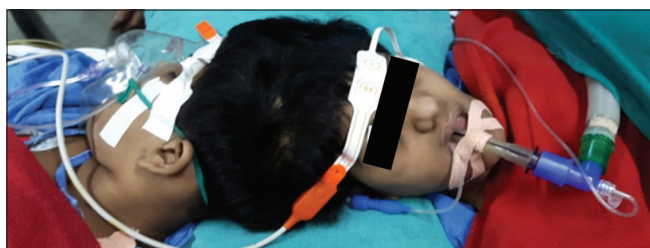

Figure 1: Craniopagus twins

pressure, pulse oximetry, temperature, and end-tidal carbon dioxide. Cerebral angiogram was planned to be conducted for both one after the other through transfemoral arterial access. Transfemoral arterial access was tried to be secured under local anesthesia in V1. However, as the child did not cooperate, the procedure was done under general anesthesia. Before induction, cross-circulation was ruled out by giving anticholinergic to V1 with no significant changes in heart rate of V2. Sequential induction of anesthesia was planned. V1 induced with injection thiopentone sodium 180 mg and fentanyl 40 mcg. Turning heads of both patients led to a reasonably good position to enable bag mass ventilation. Airway was secured with laryngeal mask airway (LMA) size 3 and anesthesia was maintained with inhalational agents. On induction, slight fall in blood pressure was noted in V1 with no hemodynamic changes in V2. Cerebral angiogram was completed in 45 min. During the procedure, vitals were stable in both, V2 was kept sedated with 1 mg midazolam with O<sub>2</sub> supplementation by mask and spontaneous ventilation. After completion of the procedure, LMA was removed under deeper planes of anesthesia to prevent coughing due to stimulation of the airway.<sup>[6]</sup> Consciousness was regained fully with stable vitals. Then, V2 was induced with thiopentone 160 mg and fentanyl 20 µg and LMA size 3 was put. Slight drop in blood pressure to 75/45 mmHg was observed in V2 which was managed with 6 mg mephentermine IV. No change in blood pressure was observed in V1 during induction of V2. The procedure for V2 completed in 1 h; during this period, V1 was maintained on O<sub>2</sub> supplementation by mask with spontaneous ventilation. Both the twins recovered well and were stable hemodynamically. They were kept under observation for 24 h. Cerebral angiogram [Figure 2] revealed no sharing of intracranial arterial circulation. However, V1 was dependent on V2 for cortical venous drainage communicating through the superior sagittal sinus.

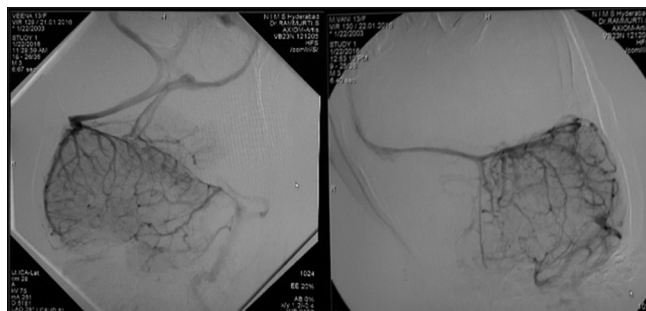


Figure 2: Cerebral angiogram of V1 and V2

Anesthetic management for craniopagus twins is associated with unique concerns of cross-circulation, difficulty in mask ventilation, access to airway, and intubation due to angle between the heads. Cerebral angiography provides invaluable information on cerebral vascular architecture.<sup>[7]</sup>

The lack of hemodynamic and level of consciousness changes in the other twin during premedication, induction, and management of hypotension episodes of first one suggest that there is no or little cross-circulation which was supported by the report of cerebral angiogram also. Cross-circulation is more common in thoracopagus and craniopagus twins and may cause altered and unpredictable drug responses.<sup>[8]</sup> General anesthesia has less adverse events as compared to sedation which has more risk of hypoxia in high-risk children scheduled for magnetic resonance imaging, computed tomography scan, and angiogram. General anesthesia may also be preferable due to long duration of these studies.

We emphasize upon necessity of systematic and advance planning of anesthetic technique along with good coordination between the two anesthetic teams to face the unique challenges in anesthetic management for craniopagus twins.

#### Declaration of patient consent

The authors certify that they have obtained all appropriate patient consent forms. In the form the patient(s) has/have given his/her/their consent for his/her/their images and other clinical information to be reported in the journal. The patients understand that their names and initials will not be published and due efforts will be made to conceal their identity, but anonymity cannot be guaranteed.

#### Acknowledgment

We acknowledge contribution of Dr. Chaitanya Pratyusha (Junior Resident, final year) for being part of the anesthesia team while conducting the case.

#### Financial support and sponsorship

Nil.

#### Conflicts of interest

There are no conflicts of interest.

**MONU YADAV, RAMAKRISHNAPRASAD CHIKKALA,  
DILIP KULKARNI, R. GOPINATH**

Department of Anaesthesiology and Critical Care,  
Nizam's Institute of Medical Sciences, Hyderabad,  
Telangana, India

#### Address for correspondence:

Dr. Monu Yadav,  
Department of Anaesthesiology and Critical Care, Nizam's Institute  
of Medical Sciences, Hyderabad - 500 082, Telangana, India.  
E-mail: monubalbir@yahoo.co.in

#### References

1. Hansen J. Incidence of conjoined twins. *Lancet* 1975;306:1257.
2. Chalam KS. Anaesthetic management of conjoined twins' separation surgery. *Indian J Anaesth* 2009;53:294-301.
3. Lalwani J, Dubey K, Shah P. Anaesthesia for the separation of conjoined twins. *Indian J Anaesth* 2011;55:177-80.
4. Spitz L. Surgery for conjoined twins. *Ann R Coll Surg Engl* 2003;85:230-5.
5. Ezike HA, Ajuzieogu VO, Amucheazi AO, Ekenze SO. General anesthesia for repair of omphalocele in a pair of conjoined twins in Enugu, Nigeria. *Saudi J Anaesth* 2010;4:202-4.
6. Kitching AJ, Walpole AR, Blogg CE. Removal of the laryngeal mask airway in children: Anaesthetized compared with awake. *Br J Anaesth* 1996;76:874-6.
7. Parameswari A, Vakamudi M, Raghupathy V, Siddhartha R. Anaesthetic management of total craniopagus twins for magnetic resonance imaging and cerebral angiography. *Br J Anaesth* 2010;105:368-70.
8. Pal R, Arora KK. Colostomy in an ischiopagus, 3<sup>rd</sup> PND conjoined twins with cross-circulation: Anaesthetic management. *Indian J Anaesth* 2014;58:345-7.

This is an open access article distributed under the terms of the Creative Commons Attribution-NonCommercial-ShareAlike 3.0 License, which allows others to remix, tweak, and build upon the work non-commercially, as long as the author is credited and the new creations are licensed under the identical terms.

Access this article online	
<b>Website:</b> www.saudija.org	<b>Quick Response Code</b> 
<b>DOI:</b> 10.4103/sja.SJA_288_17	

**How to cite this article:** Yadav M, Chikkala R, Kulkarni D, Gopinath R. Anesthetic management of craniopagus conjoined twins in a remote location. *Saudi J Anaesth* 2017;11:516-7.

© 2017 Saudi Journal of Anesthesia | Published by Wolters Kluwer - Medknow