



## Rapid disappearance of pneumorrhachis after chest tube placement

İdris Avcı\*, Ozan Başkurt, Deniz Şirinoğlu, Mehmet Volkan AYDIN

University of Health Sciences Okmeydanı Training and Research Hospital, Department of Neurosurgery, Istanbul, Turkey



### ABSTRACT

**Introduction:** We present a rare case of traumatic pneumorrhachis with the combination of hemothorax which resolved rapidly after insertion of a chest tube.

**Case presentation:** A 55 year old male was admitted to our emergency department after falling from a ladder. His general condition was well, GCS was 15 with no motor deficits. On his spinal CT a fracture on multiple ribs leading to right sided hemothorax was observed with air in the T6-T8 spinal canal. A chest tube was placed and as he did not have any neurological deficits surgical intervention to the pneumorrhachis was not considered. On the next day's a follow-up CT the air in the spinal canal was reduced and on the 5th day resolved completely.

**Conclusion:** Traumatic pneumorrhachis is a rare phenomenon and is not fully understood how the air from the posterior mediastinal wall can spread to the epidural or subarachnoid space. One hypothesis for subarachnoid air is that the high pressure air from a pneumothorax or pneumomediastinum pushes in a one-valve mechanism through the fascial layers of the posterior mediastinum through the neural foramina into the spinal canal. In our case, after the insertion of the chest tube the air in the subarachnoid space resolved and the patient's tingling sensation on his legs disappeared. We believe that the negative pressure of the chest tube did a somehow reverse effect of the air flow back from the spinal canal into the chest tube which has not been reported in the literature before.

### 1. Introduction

Despite being a rare phenomenon, the nomenclature of the presence of air in the spinal canal varies through the literature. Pneumocele,<sup>1</sup> epidural or subarachnoid pneumatosis<sup>2</sup> spinal and epidural emphysema,<sup>3</sup> pneumosaccus<sup>4</sup> pneumo- or air myelogram<sup>5</sup> or pneumomyelography<sup>6</sup> are synonyms for pneumorrhachis which was first described by Newbold et al., in 1987.<sup>7</sup> It may occur in the epidural or subarachnoid space and can be divided into three groups based on its etiology. Iatrogenic pneumorrhachis, being the most common mainly occurs due to epidural injections,<sup>8</sup> whereas non-traumatic pneumorrhachis is often secondary to spontaneous pneumothorax,<sup>3</sup> pneumomediastinum<sup>9</sup> and in some patients with severe degenerative disc disease causing the vacuum phenomenon,<sup>10,11</sup> or infectious gas-producing organisms.<sup>12</sup> Air in the spinal canal secondary to trauma is very rare and mainly occurs after the air of traumatic pneumothorax or pneumomediastinum pushes through the fascial layers of the posterior mediastinum into the epidural or subarachnoid space or direct influx of air secondary to a penetrating trauma.<sup>13</sup> As air in the epidural space is often benign and can be treated conservatively, subarachnoid air is more severe and can lead to pneumocephalus, meningitis or neurological deficits.<sup>14</sup>

We present a rare case of traumatic pneumorrhachis with the combination of hemothorax which resolved rapidly after insertion of a chest tube.

### 2. Case presentation

A 55-year-old male construction worker was admitted to our emergency department after falling from a 3-m ladder. His general condition was well, Glasgow Coma Scale was 15, pupils were isochoric and he had no motor deficits. His blood pressure was 140/80 mmHg with light tachypnea. The patient complained of right sided chest and back pain and a tingling sensation on both legs. A vertebra fracture with possible spinal compression was suspected at first but on his spinal CT, no vertebra fractures but multiple ones on ribs leading to right sided hemothorax were observed. A T6-T8 hypodensity in the subarachnoid spinal canal was detected with a Hounsfield unit of  $-900$  (Fig. 1) which was indicating to be air and confirmed with a MRI scan (Fig. 2). A chest tube was placed due to his hemothorax and the patient was transferred to the surgery ward for further investigation. As he did not have any neurological deficits surgical intervention to the pneumorrhachis was not considered. Routine hourly physical examinations were performed in case the patient developed motor or sensory deficits and needed surgical exploration. The patient stated that the tingling sensations were gone after the chest tube was placed. On the next day a follow-up CT was scheduled and the air in the spinal canal and hemothorax was reducing (Fig. 3) and on the 5th day it was resolved completely (Fig. 4). The patient was discharged from hospital the 8th day without any major complaints.

Peer review under responsibility of The Emergency Medicine Association of Turkey.

\* Corresponding author. M.D. University of Health Sciences Okmeydanı Training And Research Hospital, Department of Neurosurgery, Kaptanpaşa Mh, Darıüacevi Cd, 34384, Şişli, Istanbul, Turkey.

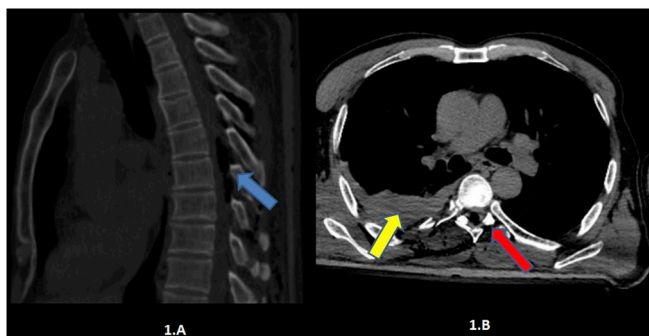
E-mail address: [ıdrisavci@gmail.com](mailto:ıdrisavci@gmail.com) (İ. Avcı).

<https://doi.org/10.1016/j.tjem.2019.07.002>

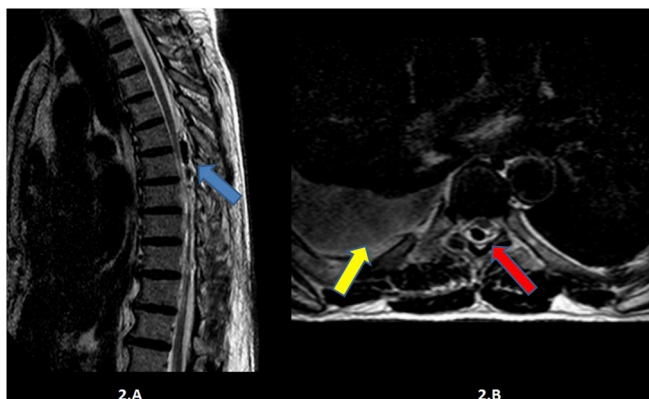
Received 20 June 2019; Received in revised form 12 July 2019; Accepted 16 July 2019

Available online 19 July 2019

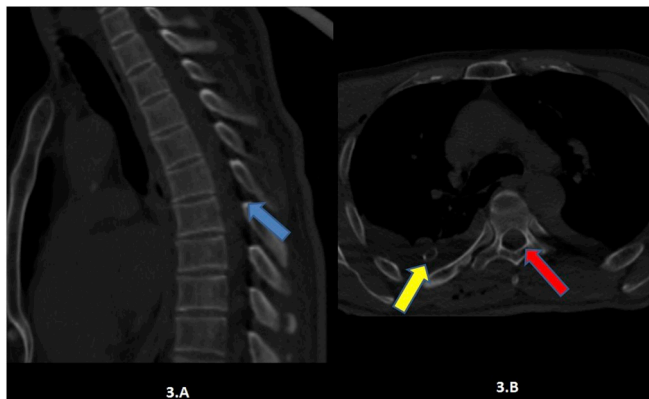
2452-2473/2019 Emergency Medicine Association of Turkey. Production and hosting by Elsevier B. V. on behalf of the Owner. This is an open access article under the CC BY-NC-ND license (<http://creativecommons.org/licenses/by-nc-nd/4.0/>).



**Fig. 1.** Thoracic CT of the patient on admission. Sagittal (1.A) and axial (1.B) view. Hypodensity the spinal canal with Hounsfield unit of  $-900$  resembling air (blue arrow). Right costal fracture and hemothorax (yellow arrow) and intradural pneumorrhachis (red arrow).



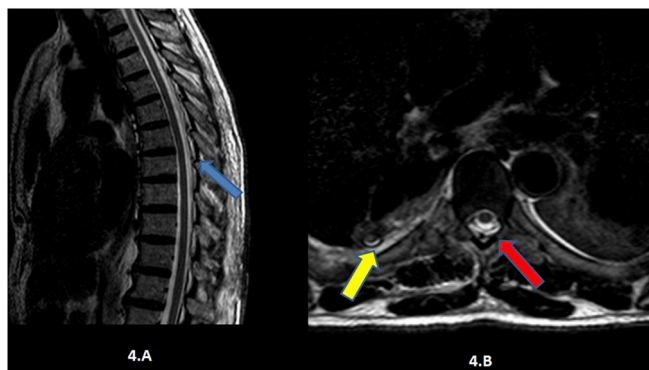
**Fig. 2.** Thoracic MRI of the patient on admission. Sagittal (2.A) and axial (2.B) view. Presence of air in the spinal canal (blue arrow). Right costal fracture and hemothorax (yellow arrow) and intradural pneumorrhachis (red arrow).



**Fig. 3.** Follow-up thoracic CT on the following day. Sagittal (3.A) and axial (3.B). Reduced air in the spinal canal (blue arrow) after the chest drain was placed (yellow arrow). Reduction of intradural air also observed on axial planes (red arrow).

### 3. Discussion

Traumatic pneumorrhachis is a rare phenomenon and it is not fully understood how the air from the posterior mediastinal wall can spread to the epidural or subarachnoid space. Epidural air, mostly occurring iatrogenically after epidural injections in which the outside air passes through the paraspinous fascia and muscles into the epidural space. One hypothesis for subarachnoid air is that the high-pressure air from a pneumothorax or pneumomediastinum pushes in a one-valve



**Fig. 4.** Follow-up thoracic MRI on 5th day. Sagittal (4.A) and axial (4.B). Total disappearance of the air in the spinal canal (blue arrow). Reduction of the hemothorax (yellow arrow) and vanishing of the intradural air (red arrow).

mechanism through the fascial layers of the posterior mediastinum through the neural foramina into the spinal canal.<sup>14</sup> Pneumorrhachis can be asymptomatic but can also cause sensory or motor impairments depending on the location and severity of the air. In our case, after the insertion of the chest tube the air in the subarachnoid space resolved and the patient's tingling sensation on his legs disappeared. We believe that the negative pressure of the chest tube did a somehow reverse effect of the air flow back from the spinal canal into the chest tube. The fact that the instant improvement of the patient's symptoms after the chest tube placement and the radiological vanishing of the air strengthens our hypothesis. Pneumorrhachis, being a mostly benign entity, which does not require surgical intervention might become more serious when the amount of air in the epidural or subarachnoid air gets bigger leading to compressive symptoms due to tension. We are not sure if the symptoms would still resolve as well with the chest tube if the patient would have more severe symptoms like motor or sensory deficits or if surgical exploration would be necessary.

### 4. Conclusion

There are no clear guidelines how to treat a patient with traumatic pneumorrhachis. Most cases do not require surgical intervention but risk of morbidity and mortality increases in case of misdiagnosis. Determining the underlying cause, like in our case, hemothorax, it is essential to understand the right biomechanical pathway of the trauma and symptoms to help physicians to evaluate the differential diagnosis. CT is the gold standard for diagnosing air in the spinal canal. Hounsfield measurements of  $-900$  to  $-1000$  are an indication for air.<sup>15</sup> Symptoms may differ if the pneumorrhachis is epidural or intradural which is difficult to determine on CT and additional MRI might be necessary. Epidural pneumorrhachis, being more often benign, only cause symptoms when the excess amount of air compresses neural structures whereas intradural air might be accompanied with cerebrospinal fluid (CSF) leakage which lead to central nervous system infections such as meningitis and encephalitis so that prophylactic antibiotics might be necessary. In our patient, no CSF leak was detected due to the intact structure of posterior elements and despite the subjective symptoms of tingling sensation on his legs, no neurologic deficits were observed and that was why we approached the patient conservatively with close neurologic follow-up.

The aspect which makes our case unique, is the rapid radiologic and symptomatic improvement after the chest tube placement. Although several mechanisms how the air travels from hollow organs into the spinal canal are envisioned, we still think that further investigations might be needed. The vacuum the negative pressure of the chest tube created to withdraw the air supports the hypothesis of the one-valve mechanism in which high pressure air travels through fascial layers but is unavailable to get back.

## Funding

None.

## Author contribution statement

We hereby verify and confirm that everyone who contributed to this manuscript is listed as an author.

The author İdris AVCI conceived the idea and wrote the paper. Ozan BAŞKURT, Deniz ŞİRİNOĞLU and Mehmet Volkan AYDIN interpreted and analysed the paper.

## Conflict of interest statement

The authors declare no conflict of interest.

## Acknowledgments

None.

## References

- Mangiardi JR, Brisson P, Weitzner I. Traumatic intraspinal pneumocele. *Surg Neurol*. 1987;27:587–588[https://doi.org/10.1016/0090-3019\(87\)90161-3](https://doi.org/10.1016/0090-3019(87)90161-3).
- Bernaerts A, Verniest T, Vanhoenacker F. Pneumomediastinum and epidural pneumatosis after inhalation of Ecstasy. *Eur Radiol*. 2003;13:642–643<https://doi.org/10.1007/s00330-002-1466-3>.
- Aribas OK, Gormus N, Kiresi DA. Epidural emphysema associated with primary spontaneous pneumothorax. *Eur J Cardiothorac Surg*. 2001;20:645–646 PMID: 11509299.
- Prins TR, Vencken LM. Traumatic pneumosaccus. *Neuroradiology*. 1989;31:290<https://doi.org/10.1007/BF00344366>.
- Gordon IJ, Hardman DR. The traumatic pneumomyelogram. A previously undescribed entity. *Neuroradiology*. 1977;13:107–108<https://doi.org/10.1007/BF00339843>.
- Gertzbein SD. Traumatic pneumomyelography. A marker of spinal column injury in the face of innocuous spine fractures: two case reports. *Spine*. 1998;23:1283–1286 PMID: 9636983.
- Newbold RG, Wiener MD, Vogler 3rd JB, Martinez S. Traumatic pneumorrhacis. *AJR Am J Roentgenol*. 1987;148(3):615–616<https://doi.org/10.2214/ajr.148.3.615>.
- Malick K. Air in the epidural space leading to neurological deficit. *Anaesthesia*. 2003;58:292–293 PMID: 12603477.
- Koeliker PD, Brannam LA. Epidural emphysema associated with spontaneous pneumomediastinum: a case report and review of the literature. *J Emerg Med*. 1999;17:247–250[https://doi.org/10.1016/S0736-4679\(98\)00162-0](https://doi.org/10.1016/S0736-4679(98)00162-0).
- Hidalgo-Ovejero AM, Martinez-Grande M, Garcia-Mata S. Disc herniation with gas. *Spine*. 1994;19:2210–2212 PMID: 7809756.
- Ford LT, Gilula LA, Murphy WA. Analysis of gas in vacuum lumbar disc. *AJR Am J Roentgenol*. 1977;128:1056–1057<https://doi.org/10.2214/ajr.128.6.1056>.
- Kirzner H, Oh YK, Lee SH. Intraspinal air: a CT finding of epidural abscess. *AJR Am J Roentgenol*. 1988;151:1217–1218<https://doi.org/10.2214/ajr.151.6.1217>.
- Rathore FA, Gill ZA, Yasin MMA. Pneumorrhacis of thoracic spine after gunshot wound. *J Coll Physicians Surg Pak*. 2012;22(8):529–530.
- Chun BJ, Moon JM. Symptomatic epidural pneumorrhacis associated with an occult pneumomediastinum due to minor trauma. *Spine*. 2009;34(26):979–982<https://doi.org/10.1097/BRS.0b013e3181b03ecb>.
- De Vos W, Casselman J, Schwennen GRJ. Cone-beam computerized tomography (CBCT) imaging of the oral and maxillofacial region: A systematic review of the literature. *Int J Oral Maxillofac Surg*. 2009;38(6):609–625<https://doi.org/10.1016/j.ijom.2009.02.028>.