



Case Report

Trimalleolar fracture and associated Achilles tendon rupture: Ten year follow up of an unusual water-skiing injury

R.N. Brueton^{a,*}, K.S. Javid^b

^a Honorary Consultant Orthopaedic Surgeon, The Royal Free Hospital, London NW3 2QH, United Kingdom of Great Britain and Northern Ireland

^b Consultant Orthopaedic Surgeon, King Faisal Hospital, Taif, Saudi Arabia

ARTICLE INFO

Keywords:

Trimalleolar fracture
Achilles tendon
Waterski-ing
De-gloving

SUMMARY

A 49 year old professional fitness instructor sustained a high velocity rotational injury to his right ankle while waterski-ing. The ski bindings did not release, exacerbating the injury. This resulted in a trimalleolar fracture and a rupture of his Achilles tendon.

A trimalleolar fracture in association with a rupture of the Achilles tendon has not been previously reported.

This combination of injuries posed a dilemma in treatment options and postoperative management.

The authors felt that ensuring that the Achilles tendon healed with no shortening was the priority for future function in this professional athlete.

It was decided to treat the Achilles tendon rupture by open repair and to place the ankle in equinus postoperatively.

It was also decided to openly reduce and internally fix the medial and lateral malleolar fractures before immobilising the ankle in equinus.

Any residual stiffness in the ankle, subtalar and midtarsal joints would be treated with aggressive physiotherapy.

It was felt that the rotational forces may have resulted in a degree of degloving around the ankle. Care was therefore taken in the choice and placement of the surgical incisions.

In spite of this, the lateral surgical wound broke down postoperatively, needing treatment with a fasciocutaneous flap.

When reviewed at ten years following the injury, the patient was continuing to work as a fitness instructor with a view to continuing to retirement in five years at the age of 65.

There was a slight decrease in dorsiflexion of the right ankle but flexion was full and movement of the subtalar and midtarsal joints were also full.

There remained 1 cm of wasting of the right calf.

Radiology of the ankle showed no joint space narrowing or evidence of degenerative change at ten years following the injury.

Introduction

The combination of a tri-malleolar fracture and associated rupture of the Achilles tendon is unusual and has not previously been reported.

* Corresponding author at: 45 Grosvenor Road, London N10 2DR, United Kingdom of Great Britain and Northern Ireland.

E-mail address: bruetons@ar2.net (R.N. Brueton).

<https://doi.org/10.1016/j.tcr.2018.09.008>

Accepted 18 September 2018

Available online 01 October 2018

2352-6440/ © 2018 The Authors. Published by Elsevier Ltd. This is an open access article under the CC BY-NC-ND license

(<http://creativecommons.org/licenses/by-nc-nd/4.0/>).

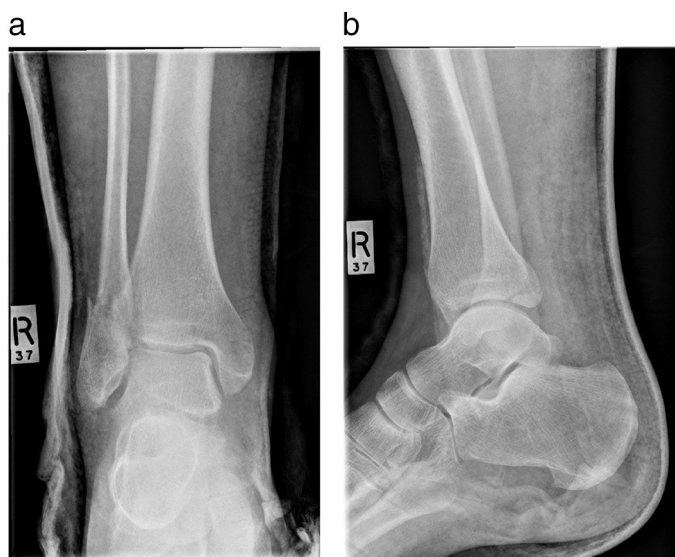

Fig. 1. a: Anteroposterior radiograph of the right ankle dated 5 August 2006 showing a trimalleolar fracture.
b: Lateral radiograph of the right ankle dated 5 August 2006 showing a trimalleolar fracture.

Ankle injuries involving a fracture of the medial malleolus and associated rupture of the Achilles tendon have been described [1–7].

In two instances, the rupture of the Achilles tendon was diagnosed but the medial malleolar fracture was initially missed [3,7].

In two instances, the medial malleolar fracture was diagnosed but the Achilles tendon rupture was initially missed [1,6].

Case report

A 49 year old fitness instructor sustained a high velocity twisting injury to his right ankle on 5th August 2006 while waterski-ing on a slalom ski. He was travelling at 30mph, although he reached 40 mph at the turns.

He said that he clipped a buoy, causing him to fall. The binding of the ski did not release and had to be unscrewed subsequently to free the patient's foot.

Clinically, there was bruising and swelling of the right ankle and a gap could be palpated in the Achilles tendon. The Simmonds test was positive. Dorsalis pedis and posterior tibial pulses were present and neurology was normal.

AP and lateral radiographs showed there to be a tri-malleolar fracture (Fig. 1a and b).

An MRI scan carried out on 9 August 2018 confirmed the trimalleolar fracture and demonstrated a rupture of the Achilles tendon together with a complete tear of the anterior tibio-fibular ligament and a partial tear of the anterior talo-fibular ligament. (Fig. 2a, b and c).

The foot was elevated to reduce the swelling.

Taking into account the patient's job as a professional fitness instructor, it was decided to carry out an open repair of the Achilles tendon to avoid any shortening. The ankle would have to be placed in equinus post-operatively and it was decided to openly reduce and internally fix the medial and lateral malleolar fractures to avoid their displacement. It was explained to the patient that there would be post-operative stiffness of the ankle and subtalar joints at the expense of restoring the correct length of the Achilles tendon.

On 18th August 2006, through a posterior incision medial to the Achilles tendon, the tendon was seen to be completely ruptured 2 cm proximal to its insertion into the calcaneum and was repaired with a Bunnell suture using "1" Ethibond.

Through a lateral incision over the lateral malleolus, the fibular fracture was reduced and held with an interfragmentary screw and a two third semitubular six hole plate.

Through a medial incision, the medial malleolus was reduced and held with a 45 mm cortical screw.

A backslab was applied with the foot in equinus.

Post-operative radiographs on 21 August 2006 showed that the fractures had been anatomically reduced (Fig. 3a and b).

After six days of elevation, the patient was discharged non weight bearing in an equinus cast.

The lateral wound subsequently broke down. The Plastic Surgeons carried out a distally based fasciocutaneous flap on 21 September 2006, that healed uneventfully.

When reviewed on 29 November 2006, he was fully weight bearing with 10° dorsiflexion and 20° plantarflexion of the right ankle.

He returned to work as a fitness instructor and continued with physiotherapy two or three times a week over the next year.

He complained of discomfort related to the fibular plate and the metalwork was removed on 23 February 2009 under general anaesthetic.

The patient was reviewed ten years after the injury, on 22 March 2017.

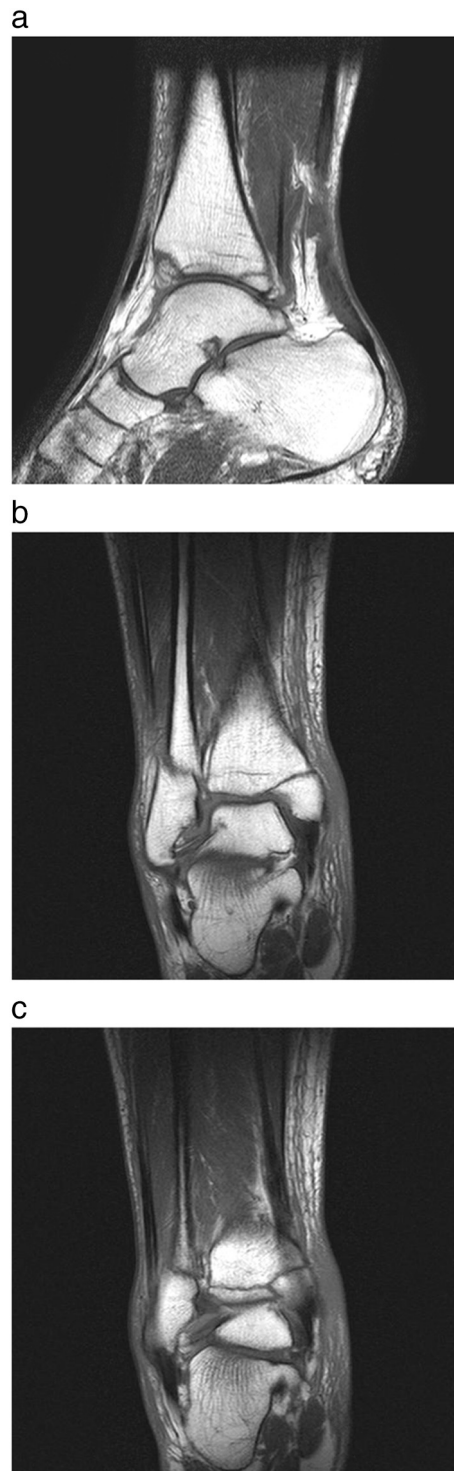

Fig. 2. a: MRI scan of right ankle dated 9 August 2006, showing fractures of the medial and posterior malleoli and rupture of the Achilles tendon. T1WTSE, TE 20/TR 500.

b: MRI scan of right ankle dated 9 August 2006, showing fractures of the medial, lateral and posterior malleoli. T1WTSE, TE 20/TR 500.

c: MRI scan of right ankle dated 9 August 2006, showing fractures of the medial, lateral and posterior malleoli. T1WTSE, TE 20/TR 500.

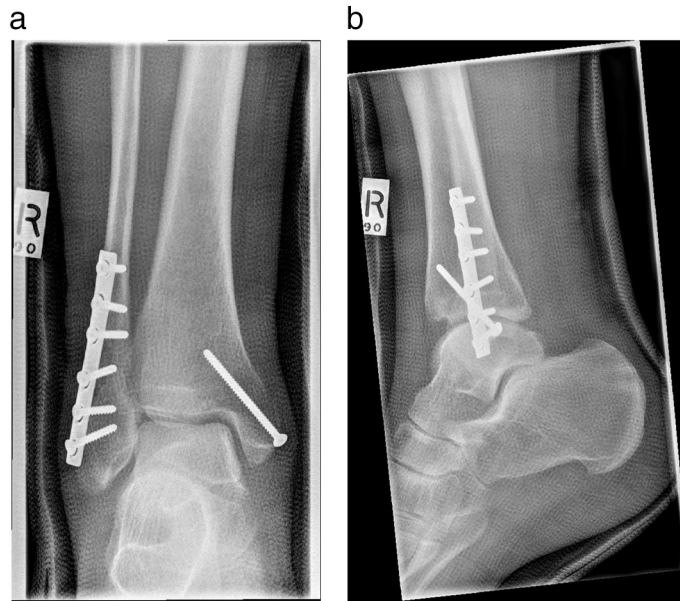


Fig. 3. a: Anteroposterior radiograph of the right ankle dated 21 August 2006 showing internal fixation of the lateral malleolar fracture with an interfragmentary screw and a six hole plate and of the medial malleolar fracture with one screw.
b: Lateral radiograph of the right ankle dated 21 August 2006 showing internal fixation of the lateral malleolar fracture with an interfragmentary screw and a six hole plate and of the medial malleolar fracture with one screw.

The patient was still working full time as a fitness instructor that involved using a treadmill.

He had returned to water-skiing using a slalom ski but kept the bindings loose.

He carried out hill walking and was able to walk for eight to 10 miles. He felt that his symptoms had reached a plateau.

He was aware of some discomfort posteriorly by the skin flap where an area of hard skin would develop. He protected this area with neoprene when carrying out sports and protected the grafted region with sunscreen. He had decided against revision of the skin flap.

There was a slight reduction of dorsiflexion of the right ankle that was of no clinical significance.

Dorsiflexion of the right ankle was 5° compared with 20° on the left.

Flexion of the ankles was 30° bilaterally.

Subtalar and midtarsal joint movements were full and equal bilaterally.

There was slight wasting of the right calf in that the circumference was 37 cm compared to 38 cm on the left.

The patient walked with a slight limp (Video 1a) but could crouch without protecting his right ankle (Video 1b) and could stand on tiptoe unaided (Video 1c).

Radiology of the right ankle taken on 22 March 2017 showed there to be no narrowing of the tibiotalar joint and no evidence of degenerative change (Fig. 4a and b).

Now 60 years of age, he intended to continue working until retirement at 65 years.

Discussion

The combination of a trimalleolar fracture of the ankle with a rupture of the Achilles tendon is unusual and poses a conflict of interests in the treatment options for each injury and in their postoperative management.

In treating the Achilles tendon rupture operatively, the ideal postoperative position for the ankle would be in equinus.

However, in treating the malleolar fractures operatively, the ideal postoperative position for the ankle would be in neutral.

The patient was a professional fitness trainer and it was essential that his ankle and Achilles tendon should function efficiently.

The authors considered that the first priority was that the Achilles tendon should heal with no residual shortening. They therefore decided upon open repair of the Achilles tendon and to position the foot in equinus postoperatively.

This equinus position would risk displacing the ankle fractures if these were not securely reduced and internally fixed.

It was therefore decided to openly reduce the malleolar fractures and risk developing stiffness of the ankle joint following post-operative immobilisation of the ankle in the equinus position.

The treatment options were discussed with the patient who was highly motivated and prepared to carry out an intensive physiotherapy regime postoperatively.

This was a high velocity rotational injury with forced dorsiflexion that had been accentuated by the failure of the water ski to release from the foot.

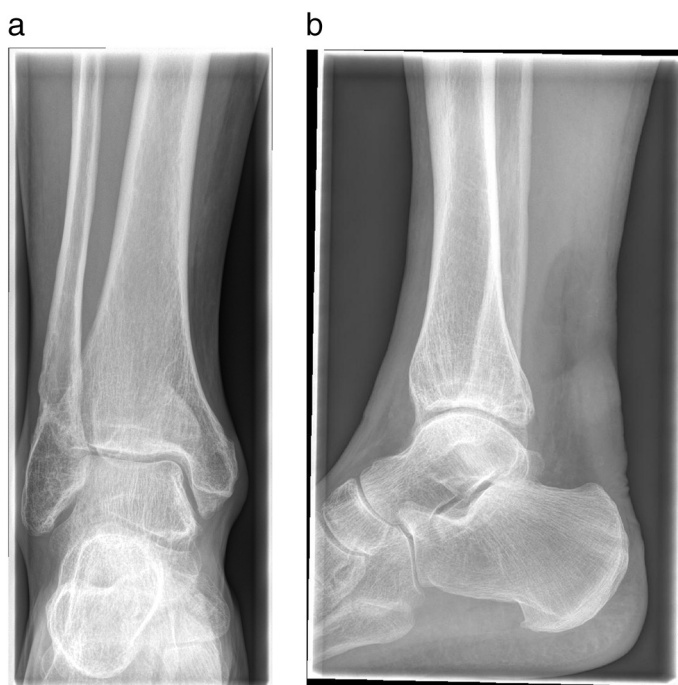


Fig. 4. a: Anteroposterior radiograph of the right ankle dated 22 March 2017.
b: Lateral radiograph of the right ankle dated 22 March 2017.

The authors realised that there may be an element of subcutaneous de-gloving that may have a bearing on the positioning of the surgical incisions and influence skin healing post-operatively.

For this reason, the limb was elevated for thirteen days preoperatively and for six days post-operatively to reduce swelling and give optimum conditions for wound healing.

In spite of these precautions, there was breakdown of the lateral wound post-operatively.

Treatment with a fasciocutaneous flap was successful.

Ten years later, the patient remains with a good clinical result that has enabled him to continue in his employment as a fitness instructor.

Supplementary data to this article can be found online at <https://doi.org/10.1016/j.tcr.2018.09.008>.

Conflict of interest statement

The authors have no conflict of interest to declare.

Informed consent

The patient has given his informed consent to the presentation of this case report.

Acknowledgement

The authors would like to thank Dr. Brian Holloway, Consultant Radiologist at the Royal Free Hospital, for his assistance with the radiology.

References

- [1] J.L. Barron, L.A. Yocum, Unrecognised Achilles tendon rupture associated with ipsilateral medial malleolar fracture, *Am. J. Sports Med.* 21 (4) (July 1993) 629–631 (0363-5465).
- [2] A. Peshev, E. Nedyalkov, Tsvetanov, Achilles tendon rupture associated with ipsilateral fracture of the medial malleolus, *Ortopediya i Travmatologiya* 33 (1) (1996) 42–43 (0473-4378).
- [3] M. Assal, R. Stern, R. Peter, Fracture of the ankle associated with rupture of the achilles tendon: case report and review of the literature, *J. Orthop. Trauma* 16 (5) (2002) 358–361 (0890-5339).
- [4] N. Maffulli, P.J. Richards, Subcutaneous rupture of the Achilles tendon and ipsilateral fracture of the medial malleolus, *BMC Musculoskelet. Disord.* 7 (2006) 59(1471-2474).
- [5] J.W. Lubin, R.A. Millar, B.J. Robinson, F.T. Blevins, Achilles tendon rupture associated with ankle fracture, *Am. J. Orthop.* 29 (9) (2000 Sep) 707–708.

- [6] J.W. Martin, Thompson GH Achilles tendon rupture. Occurrence with a closed ankle fracture, *Clin. Orthop. Relat. Res.* 210 (1986 Sept) 216–218.
- [7] H.G. Peiper, C.B. Radas, G. Quack, H. Khrahl, Mediomalleolar fracture combined with Achilles tendon rupture – a rare simultaneous injury of the ankle, *Int. J. Sports Med.* 18 (1) (1998 Jan) 68–70.