



# HIGH-FLOW NASAL CANNULA COMBINED WITH PRONE POSITIONING AS AN INTUBATION ALTERNATIVE IN COVID-19: A CASE REPORT AND REVIEW OF THE LITERATURE

Nataša Sojčić<sup>1</sup>, Jasminka Peršec<sup>1,2</sup> and Andrej Šribar<sup>1,2</sup>

<sup>1</sup>Department of Anesthesiology, Resuscitation and Intensive Care Medicine, Dubrava University Hospital, Zagreb, Croatia;

<sup>2</sup>School of Dental Medicine, University of Zagreb, Zagreb, Croatia

**SUMMARY** – The use of high-flow nasal cannula (HFNC) in COVID-19 patients is a controversial topic due to the benefits and risks which may occur in patients and healthcare workers. The goal of this treatment modality is potential avoidance of invasive mechanical ventilation, but generation of aerosol and increased healthcare professional infection risk must be considered. We present a case of a SARS-CoV-2-positive 71-year-old male with acute hypoxemic respiratory failure, who was successfully treated with HFNC combined with prone positioning. Furthermore, we discuss recent literature concerning potential issues of HFNC treatment in COVID-19 patients.

**Key words:** *Noninvasive ventilation; COVID-19; SARS-CoV-2; Oxygen inhalation therapy; Respiratory failure*

## Introduction

The use of high-flow nasal cannula (HFNC) to provide oxygen supplementation and improve the ventilation-perfusion ratio is a well-established treatment modality in patients with hypoxemic respiratory failure (HRF)<sup>1</sup>. However, its use in COVID-19 patients is discouraged due to the potential aerosol spread and increased infection risk<sup>2</sup>. We present a patient with borderline moderate to severe HRF in whom invasive mechanical ventilation was avoided by combined use of HFNC and prone positioning.

---

Correspondence to: *Andrej Šribar, MD, PhD*, Department of Anesthesiology, Resuscitation and Intensive Care Medicine, Dubrava University Hospital, Av. Gojka Šuška 6, HR-10000 Zagreb, Croatia

E-mail: [andrej.sribar@gmail.com](mailto:andrej.sribar@gmail.com)

Received July 17, 2020, accepted October 14, 2020

## Case Report

In April 2020, a 71-year-old male patient with arterial hypertension and mild obesity (body mass index 27.5 kg/m<sup>2</sup>) was admitted to the Intensive Care Unit (ICU) in primary respiratory intensive care center specialized for COVID-19 patients (PRIC). Eight days prior to the onset of symptoms, he was in contact with a friend who was SARS-CoV-2 positive. On day 7 after symptom onset and positive SARS-CoV-2 real-time polymerase chain reaction test, he was admitted to PRIC. Symptoms and signs included fatigue, muscle pain, fever (up to 39 °C), non-productive cough, and anosmia. Two days prior to hospital admission, he developed mild dyspnea and occasional chest pressure. Physical examination at admission showed mild respiratory distress with the following vital signs: axillary temperature 37.2 °C, heart rate 86/min, blood pressure 170/90 mm Hg, respiratory rate 20/min, peripheral

oxygen saturation ( $\text{SpO}_2$ ) 84% on room air in upright position and 90% in lateral decubital or prone position. Arterial blood gas analysis showed moderate hypoxemia and mild hypocapnia ( $\text{PaO}_2$  6.5 kPa,  $\text{PaCO}_2$  4.4 kPa) with normal base deficit and lactate levels. Chest x-ray showed discrete inhomogeneous opacities in the right lower lobe (Fig. 1). Immediately after admission and blood sampling, the patient received 4 L/min of  $\text{O}_2$  through facemask, which resulted in fast relief of dyspnea with improvement of  $\text{SpO}_2$  to 98% and  $\text{PaO}_2$  to 10.8 kPa. According to the hospital protocol, chloroquine phosphate (total of 5 days) and azithromycin (total of 3 days) were prescribed. QTc interval and liver enzymes were regularly checked given the possible side effects of the previously mentioned drugs. After day 4 of ICU stay, the patient showed fatigue during mild physical exertion (for example, going to the bathroom) with  $\text{SpO}_2$  82%. Repeated chest x-ray showed worsening of bilateral infiltrates and small pleural effusion on the left side. From that moment, the patient was encouraged to lie in a prone position for several hours through day and night, which led to relief of symptoms and improvement of  $\text{SpO}_2$ .

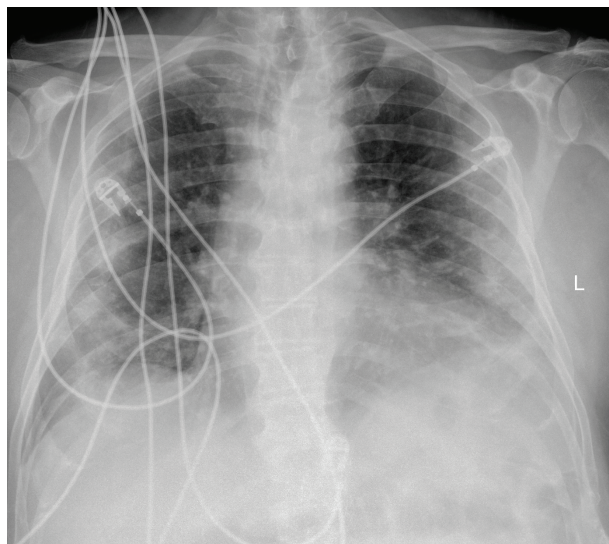


Fig. 1. Chest x-ray at admission.

Nevertheless, on day 6 of ICU stay, his state worsened further with aggravation of hypoxemia (with 6 L/min of  $\text{O}_2$  through facemask  $\text{SpO}_2$  fell to 82%,  $\text{PaO}_2$  to 6.2 kPa, and  $\text{PaO}_2/\text{FiO}_2$  105 mm Hg). Disparity between the clinical condition (primarily in the severity of dyspnea) and oxygen blood levels was present,

hence the patient was not in severe respiratory distress nor did he complain of shortness of breath to the extent it would be expected. Also, further progressive changes in radiographic findings were recorded. Figure 2 demonstrates extensive bilateral infiltrates affecting the entire lung with predominance in the lower and medial lung fields. Computed tomography (CT) showed subpleural perihilar diffuse alveolar consolidations, ground-glass opacities, and intra- and interlobular septal thickening as common CT features in COVID-19.

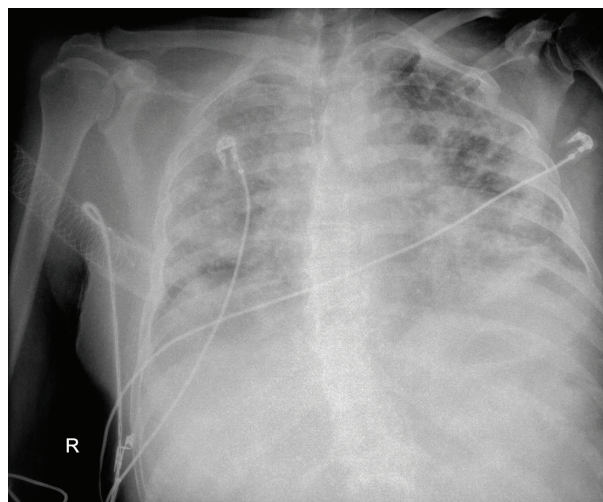


Fig. 2. Chest x-ray on day 6 of Intensive Care Unit stay.

Considering worsening of hypoxemia and chest radiograph, HFNC (Hi-Flow Star, Dräger, Lübeck, Germany) was initiated, with  $\text{FiO}_2$  1.0, flow 35 L/min and temperature of  $37^\circ\text{C}$  as initial settings, which were subsequently adjusted to the aimed  $\text{SpO}_2 >93\%$ . When necessary, maximum HFNC flow was utilized (50 L/min). Additionally, surgical mask was used over the nose and mouth to reduce the risk of aerosol spread. The patient reported alleviated breathing approximately 30 minutes after starting HFNC, accompanied with gradual rise of  $\text{SpO}_2$  up to 92% and  $\text{PaO}_2$  to 8.7 kPa, which were even more pronounced in prone position ( $\text{SpO}_2$  up to 94%). Due to respiratory function impairment and worsening of gas exchange, intravenous methylprednisolone was applied (1 mg/kg for 3 days, tapered to 0.5 mg/kg for the next 4 days). Laboratory findings reflected elevated systemic inflammation markers (white blood cell count, serum C-reactive protein, procalcitonin, ferritin and

D-dimer). Lung ultrasound was regularly performed to reduce ionizing radiation exposure, and a decrease of B-line density was recorded over time. The patient was hemodynamically stable at all times without significant signs of other organ damage. Restrictive fluid administration regimen and daily respiratory therapy were implemented.

High-flow nasal cannula was applied for a total of 15 days, and the patient was gradually weaned to facemask and subsequently to room air. The basic principle we used in weaning HFNC therapy was firstly gradual reduction of  $\text{FiO}_2$  (approximately to 0.3-0.35) and if the respiratory rate and  $\text{SpO}_2$  were satisfactory, gradual reduction of flow was performed<sup>3</sup>. In total, supplemental oxygen therapy was needed for a total of 40 days. At 22 days of admission, nasopharyngeal swabs were confirmed negative for SARS-CoV-2. The patient was discharged home 46 days after admission fully recovered with complete regression of pulmonary infiltrates, normal parameters of gas exchange and other laboratory findings.

## Discussion

Endotracheal intubation and mechanical ventilation are still the gold standard in the treatment of acute HRF but it is associated with a high complication rate and increased mortality in COVID-19 patients<sup>4</sup>. There is a hypothesis that certain patients with COVID-19 have presented a new phenotype that differs from clinical features previously seen in hypoxemic patients. In these patients, respiratory mechanics are preserved, and hypoxemia may be attributed to pulmonary thromboembolism and loss of hypoxic pulmonary vasoconstriction<sup>5,6</sup>. It may be reversed by a combination of high  $\text{FiO}_2$ , positive airway pressure and reduced work of breathing created by HFNC coupled with decrease of intrapulmonary shunting and increase of lung compliance provided by prone positioning<sup>7,8</sup>. Simultaneous use of these two treatment modalities enabled avoidance of invasive mechanical ventilation in this patient. As shown in a study from China, in COVID-19 patients with  $\text{PaO}_2/\text{FIO}_2 < 300$  mm Hg combining prone position with HFNC significantly improved ventilation-perfusion mismatch and proved to be a good strategy in avoiding intubation and reducing the medical staff workload<sup>9</sup>. It must also be noted that, although recently published data suggest

that stress ulcer prophylaxis might increase the risk of bacterial superinfection<sup>10</sup>, in this patient it was not the case and the collected sputum specimens showed no pathogen growth.

As COVID-19 pandemic erupted in early 2020, a main concern was limiting the spread of this highly virulent virus. Because of that, the use of HFNC was observed with skepticism and was initially discouraged in these patients<sup>2,11</sup>. However, both experimental and clinical published data showed HFNC to be safe to use when all the precautionary measures are employed<sup>12</sup> (confirmed by the fact that none of the healthcare personnel that treated this patient were infected with SARS-CoV-2) and may greatly reduce the intubation and complications rate, as well as ICU stay<sup>13</sup>.

## References

1. Mauri T, Turrini C, Eronia N, Grasselli G, Volta CA, Bellani G, *et al.* Physiologic effects of high-flow nasal cannula in acute hypoxemic respiratory failure. *Am J Respir Crit Care Med.* 2017 May 1;195(9):1207-15. doi: 10.1164/rtc.201605-0916OC. PMID: 27997805.
2. ANZICS COVID-19 Guidelines. ANZICS Available from: <https://www.anzics.com.au/coronavirus-guidelines/>. Accessed June 1, 2020.
3. Kim MC, Lee YJ, Park JS, Cho YJ, Yoon HI, Lee CT, *et al.* Simultaneous reduction of flow and fraction of inspired oxygen ( $\text{FiO}_2$ ) versus reduction of flow first or  $\text{FiO}_2$  first in patients ready to be weaned from high-flow nasal cannula oxygen therapy: study protocol for a randomized controlled trial (SLOWH trial). *Trials.* 2020 Jan 14;21(1):81. doi: 10.1186/s13063-019-4019-7. PMID: 31937322; PMCID: PMC6961313.
4. Weiss P, Murdoch DR. Clinical course and mortality risk of severe COVID-19. *Lancet.* 2020;395:1014-5. doi: 10.1016/S0140-6736(20)30633-4. Epub 2020 Mar 17. PMID: 32197108; PMCID: PMC7138151.
5. Gattinoni L, Chiumello D, Rossi S. COVID-19 pneumonia: ARDS or not? *Crit Care.* 2020 Apr 16;24(1):154. doi: 10.1186/s13054-020-02880-z. PMID: 32299472; PMCID: PMC7160817.
6. Deshpande C. Thromboembolic findings in COVID-19 autopsies: pulmonary thrombosis or embolism? *Ann Intern Med.* 2020 Sep 1;173(5):394-5. doi: 10.7326/M20-3255. Epub 2020 May 15. PMID: 32422061; PMCID: PMC7249508.
7. Despres C, Brunin Y, Berthier F, Pili-Floury S, Besch G. Prone positioning combined with high-flow nasal or conventional oxygen therapy in severe COVID-19 patients. *Crit Care.* 2020 May 26;24(1):256. doi: 10.1186/s13054-020-03001-6. PMID: 32456663; PMCID: PMC7250283.
8. Ghelichkhani P, Esmaeili M. Prone position in management of COVID-19 patients; a commentary. *Arch Acad Emerg.* 2020 Apr 11;8(1):e48. PMID: 32309812; PMCID: PMC7158870.

9. Xu Q, Wang T, Qin X, Jie Y, Zha L, Lu W. Early awake prone position combined with high-flow nasal oxygen therapy in severe COVID-19: a case series. *Crit Care*. 2020 May 24;24(1):250. doi: 10.1186/s13054-020-02991-7. PMID: 32448330; PMCID: PMC7246000.
10. Muzlović I, Štubljar D. Stress ulcer prophylaxis as a risk factor for tracheal colonization and hospital-acquired pneumonia in intensive care patients: impact on latency time for pneumonia. *Acta Clin Croat*. 2019 Mar;58(1):72-86. doi: 10.20471/acc.2019.58.01.10. PMID: 31363328; PMCID: PMC6629202.
11. Brewster DJ, Chrimes N, Do TB, Fraser K, Groombridge CJ, Higgs A, *et al.* Consensus statement: Safe Airway Society principles of airway management and tracheal intubation specific to the COVID-19 adult patient group. *Med J Aust*. 2020 Jun;212(10):472-81. doi: 10.5694/mja2.50598. Epub 2020 May 1. PMID: 32356900; PMCID: PMC7267410.
12. Tran K, Cimon K, Severn M, Pessoa-Silva CL, Conly J. Aerosol generating procedures and risk of transmission of acute respiratory infections to healthcare workers: a systematic review. *PLoS One*. 2012;7(4):e35797. doi: 10.1371/journal.pone.0035797. Epub 2012 Apr 26. PMID: 22563403; PMCID: PMC3338532.
13. Lyons C, Callaghan M. The use of high-flow nasal oxygen in COVID-19. *Anaesthesia*. 2020 Jul;75(7):843-7. doi: 10.1111/anae.15073. Epub 2020 Apr 20. PMID: 32246843.

#### Sažetak

### KOMBINIRANA PRIMJENA TERAPIJE VISOKIM PROTOCIMA KISIKA I POTRBUŠNOG POLOŽAJA KAO ALTERNATIVA INTUBACIJI U COVID-19: PRIKAZ SLUČAJA I PREGLED LITERATURE

*N. Sojčić, J. Persec i A. Šribar*

Terapija visokim protocima kisika u bolesnika oboljelih od COVID-19 kontroverzna je tema zbog koristi i rizika za bolesnike i zdravstvene djelatnike. Cilj ovog modaliteta liječenja je potencijalno izbjegavanje potrebe za endotrahealnom intubacijom i mehaničkom ventilacijom, ali zbog povećanog generiranja aerosola potrebno je uzeti u obzir povećan rizik za obolijevanje zdravstvenih djelatnika. Prikazujemo slučaj 71-godišnjaka oboljelog od infekcije SARS-CoV-2 s akutnim respiracijskim zatajenjem koji je uspješno liječen terapijom visokim protocima kisika u potrbušnom položaju. Uz prikaz slučaja daje se i kratak osvrt na noviju literaturu koja se bavi terapijom visokim protocima kisika u bolesnika s COVID-19.

**Ključne riječi:** *Neinvazivna ventilacija; COVID-19; SARS-CoV-2; Inhalacijska terapija kisikom; Respiracijsko zatajenje*