

Received: 2016.03.06
Accepted: 2016.04.21
Published: 2016.05.16

An Anatomical Study of the Nutrient Foramina of the Human Humeral Diaphysis

Authors' Contribution:
Study Design A
Data Collection B
Statistical Analysis C
Data Interpretation D
Manuscript Preparation E
Literature Search F
Funds Collection G

ABCDEF 1 **Zichao Xue**
BCD 1 **Haoliang Ding**
ABD 2 **Chuanzhen Hu**
BC 1 **Haitao Xu**
AG 1 **Zhiquan An**

1 Department of Orthopaedic Surgery, Shanghai Jiao Tong University Affiliated Sixth People's Hospital, Shanghai, P.R.China
2 Department of Orthopaedics, Shanghai Ruijin Hospital, Shanghai, P.R. China

Corresponding Author: Zhiquan An, e-mail: anzhiquan@126.com

Source of support: This study was funded by National Natural Science Foundation of China (81171704)

Background: Understanding the nutrient foramina is critical to clinical practice. An insult to the nutrient foramina can be caused by trauma and/or surgical dissection and lead to devascularization and bad outcomes. Few studies have looked at the humerus, and no studies have described relative information of humeral nutrient foramen related to anatomical structures that might be located by palpable landmarks. In this study, we analyzed the anatomical features of the nutrient foramina of the diaphyseal humerus and provide a discussion of clinical relevance.


Material/Methods: We dissected 19 cadavers and analyzed the relative positions of the foramina and surrounding muscles, and the number, direction, diameter, and location of the nutrient foramina. Foramina index and a new landmark index were used to calculate the location. We compared the data from both sides and the relationships between transverse and longitudinal locations, diameter and total length, and foramina index and landmark index were also analyzed.

Results: The humeri had one or two main nutrient foramina located in a small area between the coracobrachialis and brachial muscles and oriented toward the elbow. The mean diameter was 1.11 ± 0.32 mm. The mean index and landmark index were $43.76 \pm 4.94\%$ and $42.26 \pm 5.35\%$, respectively. There were no differences between sides in terms of diameter, length, or nutrient foramina index. There were no significant correlations between transverse and longitudinal locations or diameter and total length. The foramina index and landmark index showed strong positive correlation ($r=0.994$, $p<0.0001$).

Conclusions: Our study provides details about the nutrient foramina that will benefit clinicians who treat injuries and diseases of the humerus. Surgeons should be mindful of soft tissue in the foraminal area during surgical procedures.

MeSH Keywords: **Arteries • Haversian System • Humerus**

Full-text PDF: <http://www.medscimonit.com/abstract/index/idArt/898361>

 3161

 2

 10

 36



Background

The physiology of bones, including their growth and repair, is dependent on their blood supply [1–11]. The major blood supply to long bones is provided by the nutrient arteries [8,10].

In the humerus, 90% of the blood supply to the diaphyseal cortical bone is supplied from the nutrient artery [8]. Menck et al. reported that the humerus is usually supplied by a single nutrient artery entering the nutrient foramen just below its midpoint [12]. Unfortunately, a significant proportion of humeral fractures are located in this area and will likely destroy the main nutrient artery [13,14]. Clinicians should be aware that fractures passing through the foraminal area are likely to heal slowly or not at all [4,14,15].

Fractures of the humeral shaft account for approximately 3% of all fractures [16,17]. With advancements in bone fixation techniques and increasing pressure from patients, humeral shaft fractures are increasingly being treated surgically, which is associated with high costs and risks of complications [14,17]. Inappropriate therapy or poor surgical technique can impair the foraminal area and nutrient artery, and therefore interfere with fracture union [6,10]. Nonunion occurs 15–30% of the time, depending on the treatment [18–20], leading to substantial additional cost [14,21]. If surgeons were able to avoid the bone area containing the nutrient foramen during surgeries, improved management and outcomes would likely be realized [15].

Therefore, an understanding of the anatomy of the nutrient foramina in long bones is critical to the success of surgical procedures and outcomes [1,2,4–6,9,10,13,15,22–25].

Many scholars have studied the nutrient foramina of long bones [1,2,4,5,13,15,22–27]. Most of these studies were performed many years ago, and mainly focused on the number, location, and direction of the nutrient foramina. Few studies were specific to the humerus, and study findings were limited to anatomical descriptions and often differed from one another [1,15]. In addition, while anatomical structures can be identified by palpable landmarks in clinical practice, a palpable landmark for the nutrient foramina has not been described in the literature.

In this study, we systematically observed the anatomical features of nutrient foramina in humeral diaphysis. Based on these findings, we also provide a conclusive descriptive interpretation of previously published studies, which indicate that each humerus has one or two main nutrient arteries and several accessory arteries. Our study also provides novel data, including the diameter and symmetry analysis of the nutrient foramen. We also provide observations regarding the relative

positions of the nutrient foramen and the surrounding muscles. Most importantly, we introduce a novel landmark index that will help clinicians to locate the nutrient foramen by palpation.

Material and Methods

The Ethics Committee of Shanghai Sixth People's Hospital Affiliated to Shanghai Jiao Tong University approved the study protocol. Nineteen adult Chinese cadavers (10 males and 9 females) were separately collected. The cadaver donors were free of any history of upper limb trauma or vascular or hemorrhagic diseases.

Our study was guided by findings from previous studies that showed the majority of the foramina were observed in the anteromedial portion of the mid-distal diaphysis [1,2,4,5,13,15,22,23]. The foramina were first exposed by careful dissection to determine the relationship between the foramina and the surrounding muscles (Figure 1).

Next, the soft tissues and periosteum were removed. As Laing [1] previously observed, the accessory nutrient arteries entered the posterior surface in the spiral groove, and these vessels were all small, with no nutrient foramina visible on the bone surface. Additionally, because our study aimed to benefit surgical outcomes, only macroscopic foramina of the diaphysis were included. All bone surfaces were systematically examined macroscopically so that small foramina would not be overlooked.

The nutrient foramina were identified by the presence of distal grooves and the canals, which were raised above the surface of the bone (Figure 1). In ambiguous cases, we passed a fine wire through the foramen to confirm that it did indeed enter the medullary cavity. For bones with more than one foramen, all foramina in that bone were recorded.

For each limb, the number, direction, diameter, and location of the nutrient foramina were recorded. The anatomic surface bearing the foramen was also noted. Foramina within 1 mm of the anterior or medial border were considered to be on that border. The diameters of the nutrient foramina were measured using a sliding caliper that was accurate to 0.01 mm (Figure 2).

The transverse distribution of the foramina was recorded relative to the medial border. The longitudinal location of a foramen was determined by measuring its distance from both fixed points and apices at the proximal and distal ends of the bone; these measurements were then expressed as percentages of the palpable and maximal lengths. Measurements were made using a divider that was read on a scale graduated in millimeters.

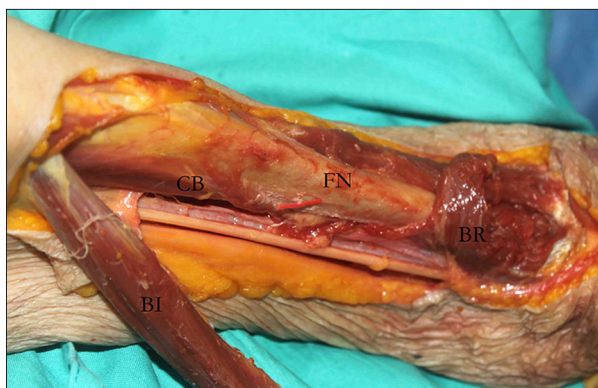


Figure 1. The upper arm was dissected (Specimen 1), and the nutrient foramen was identified by the presence of a groove and adjacent canal. The location was between the insertion of the coracobrachial muscle and the origin of the brachial muscle. The foramen was directed distally. BI – biceps brachii; CB – coracobrachial muscle; NF – nutrient foramen; BR – brachial muscle.

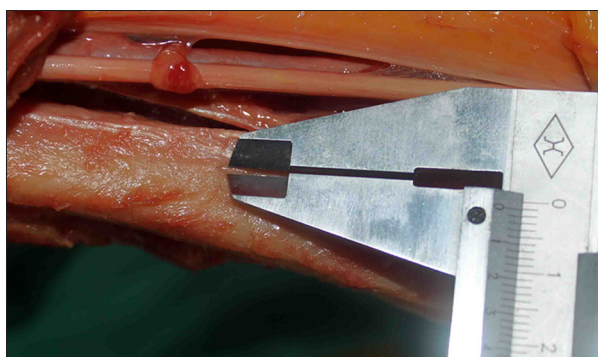


Figure 2. The diameters of nutrient foramina were measured using a sliding caliper accurate to 0.01 mm.

While it is impossible to make perfectly precise measurements, all measurements were performed by one author using a standardized process to avoid inter-observer variability to the greatest extent possible.

Hughes introduced a formula to calculate the index (I) of the nutrient foramina away from the proximal ends [28]. To provide more practical information for clinical use in surgery, we modified the formula to create a landmark index (I') in this study. In clinical practice, especially in surgery, many anatomical structures can be located by palpation of landmarks on the body surface. Furthermore, because most of the foramina were observed in the anteromedial diaphyseal humerus, we selected the medial epicondyle and the greater tuberosity as two fixed points from which to calculate the landmark index; of these, the epicondyle is more easily palpable than the greater tuberosity. We calculated both indices from the distal end.

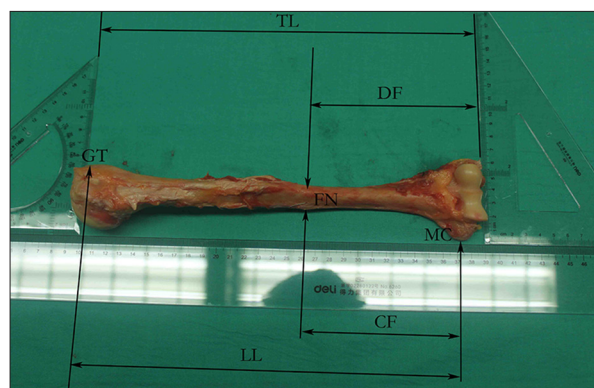

Figure 3. Measurements of foramina index (I) and landmark index (I'). TL is the total length of the bone; DF is the distance from the distal end of the bone to the nutrient foramen; CF is the distance between the medial epicondyle and the nutrient foramen; and LL is the distance between the medial epicondyle and the greater tuberosity.

The formulas are expressed as $I = DF/TL \times 100$, where I is the foramina index, DF is the distance from the distal end of the bone to the nutrient foramen, and TL is the total length from apex to apex, and $I' = CF/LL \times 100$, where I' is the landmark index, CF is the distance between the medial epicondyle and the nutrient foramen, and LL is the distance between the medial epicondyle and the greater tuberosity (Figure 3).

The bones were photographed with a digital camera. Data were analyzed with Pearson's correlation coefficient and the paired t-test using SPSS software (Statistical Package for the Social Sciences-SPSS Inc. v20, Chicago, IL, USA).

Results

In all limbs but one, the nutrient foramina were consistently found between the insertion of the coracobrachial muscle and the origin of the brachial muscle anterior and inferior to the coracobrachialis (Figure 1).

The data are displayed in Table 1. A total of 42 nutrient foramina were found in 38 humeri. Thirty-two (84.21%) humeri had a single nutrient foramen. Double foramina were observed in five (13.16%) humeri, while the foramen was absent in one (2.63%) humerus (Figures 4, 5). All nutrient foramina entered the diaphysis obliquely and were oriented distally in the direction of the elbow (Figure 1). The mean foramen diameter was 1.11 ± 0.32 mm (range 0.42–1.78 mm). All foramina were found on the surface from the medial to the anterior border. To illustrate the transverse distribution, we created a similar ratio of the distance from the medial border to the nutrient foramen and from the foramen to the anterior border. As shown in Figure 6, there was a highly significant tendency for the foramina to

Table 1. Observation and demographic data of nutrient foramina of humerus diaphysis.

NO.	Gender	Side	Number	Direction	Diameter (mm)	Transverse (%)	TL (mm)	D-C (mm)	C-F (mm)	F-T (mm)	I (%)	I' (%)
1	F	L	1	Distal	1.02	33.3	290	19	108	148	43.79	42.19
		R	1	Distal	1.02	0	276	15	84	156	35.87	35.00
2	M	L	1	Distal	0.80	0	295	15	110	160	42.37	40.74
		R	1	Distal	0.84	0	300	17	103	167	40.00	38.15
3	F	L	1	Distal	1.58	40	304	17	114	154	43.09	42.54
		R	1	Distal	1.66	50	305	18	105	165	40.33	38.89
4	F	L	1	Distal	1.24	0	310	17	122	160	44.84	43.26
		R	2	Distal	0.42	0	312	18	97	190	36.86	33.80
				Distal	1.10	100	312	18	113	174	41.99	39.37
5	F	L	1	Distal	1.10	50	335	19	131	174	44.78	42.95
		R	1	Distal	1.40	0	332	20	145	160	49.70	47.54
6	M	L	1	Distal	1.40	0	324	17	116	175	41.05	39.86
		R	1	Distal	1.10	25	334	18	117	192	40.42	37.86
7	M	L	1	Distal	0.80	0	313	20	131	149	48.24	46.79
		R	1	Distal	0.78	0	313	19	140	135	50.80	50.91
8	M	L	1	Distal	1.52	0	324	19	122	168	43.52	42.07
		R	1	Distal	0.94	0	324	17	123	167	43.21	42.41
9	M	L	2	Distal	1.00	0	298	17	109	158	42.28	40.82
				Distal	1.48	0	298	17	136	131	51.34	50.94
		R	1	Distal	1.58	0	299	17	141	128	52.84	52.42
10	F	L	1	Distal	1.36	25	287	16	116	143	45.99	44.79
		R	2	Distal	0.90	0	289	16	75	191	31.49	28.20
				Distal	0.90	0	289	16	124	142	48.44	46.62
11	M	L	2	Distal	1.42	33.3	328	16	105	195	36.89	35.00
				Distal	0.56	33.3	328	16	141	159	47.87	47.00
		R	1	Distal	1.78	33.3	327	15	121	182	41.59	39.93
12	F	L	1	Distal	0.52	33.3	292	15	113	154	43.84	42.32
		R	1	Distal	1.18	0	298	15	110	164	41.95	40.15
13	M	L	1	Distal	1.44	20	317	19	125	157	45.43	44.33
		R	1	Distal	0.90	0	314	17	98	184	36.62	34.75
14	F	L	1	Distal	1.12	33.3	277	14	112	141	45.49	44.27
		R	1	Distal	1.48	25	278	13	122	137	48.56	47.10
15	M	L	0	.	.	.	290
		R	1	Distal	1.12	25	296	16	91	178	36.15	33.83
16	M	L	1	Distal	1.18	40	307	21	122	154	46.58	44.20
		R	2	Distal	0.90	33.3	306	12	99	186	36.27	34.74
				Distal	0.60	40	306	12	132	153	47.06	46.32
17	F	L	1	Distal	1.12	20	285	18	114	143	46.32	44.36
		R	1	Distal	1.18	0	288	16	126	136	49.31	48.09
18	F	L	1	Distal	1.06	33.3	292	20	135	122	53.08	52.53
		R	1	Distal	1.12	25	292	18	106	153	42.47	40.93
19	M	L	1	Distal	0.92	25	317	20	119	162	43.85	42.35
		R	1	Distal	1.28	0	319	17	128	160	45.45	44.44
Total			42									
Average			1.11		1.11		305.12				43.76	42.26
STDEV					0.32		16.29				4.94	5.35

TL – total long; D-C – distance from distal end of the bone to medial epicondyle; C-F – distance from the epicondyle to nutrient foramen; F-T – distance from nutrient foramen to greatest tuberosity.

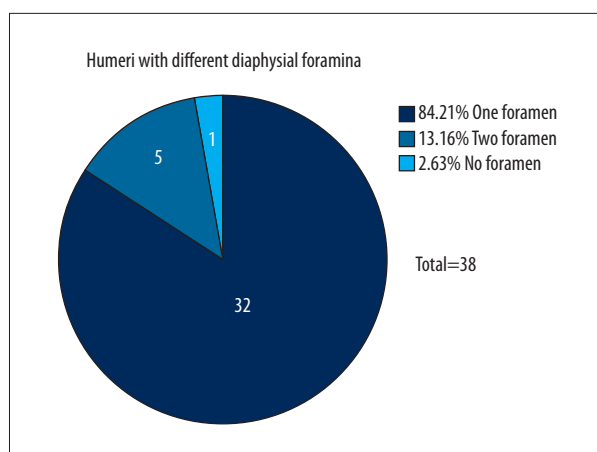


Figure 4. Thirty-two (84.21%) humeri had a single nutrient foramen. Five (13.16%) humeri had two foramina, and one (2.63%) humerus had no foramen.

be medial (97.62%). The mean total length was 305.12 ± 16.29 mm (range 276–335 mm). The mean foramina index (I) was $43.76 \pm 4.94\%$ (range 31.49–53.08%), and the mean landmark index (I') was $42.26 \pm 5.35\%$ (range 28.20–52.53%). The nutrient foramina were located in the distal portion near the mid-point; the majority (73.81%) were located with a foramina index of 40–50% (Figure 7).

Correlations between the transverse and longitudinal distributions, diameter and total length, and foramina and landmark indices were analyzed using Pearson's correlation coefficient. There was no significant correlation between the transverse and longitudinal distribution ($r = -0.38$, $p = 0.809$) (Figure 8). Similarly, there was no correlation between the foramina diameter and the total humerus length ($r = 0.094$, $p = 0.552$) (Figure 9).

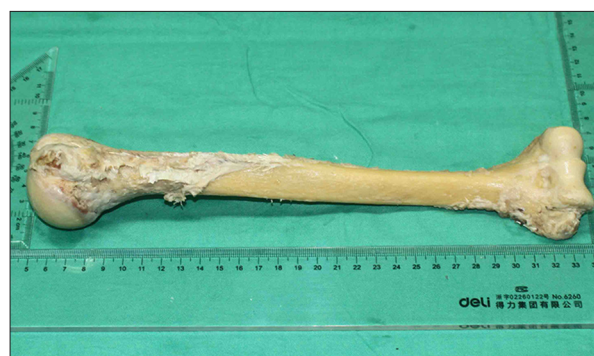

Figure 5. Left humerus of Specimen 15 showed no nutrient foramen.

In contrast, a strong correlation was observed between the two indices ($r = 0.994$, $p < 0.0001$) (Figure 10).

The availability of full cadavers allowed comparison of data between both sides of the body. The statistical data for the left and right sides are presented in Table 2. Paired *t*-tests were performed for diameter, length, and nutrient foramina index. Specimens with absent or two foramina were excluded. No significant differences were observed between the left and right sides for diameter, length, and nutrient foramina index (*p* values: 0.713, 0.431, and 0.278, respectively).

Discussion

The arrangement of the diaphyseal nutrient foramina in the long bones usually follows a defined pattern in which the foramina are located on the flexor surface of the bones (anterior in the upper limbs and posterior in the lower) [15–23]. Dissection

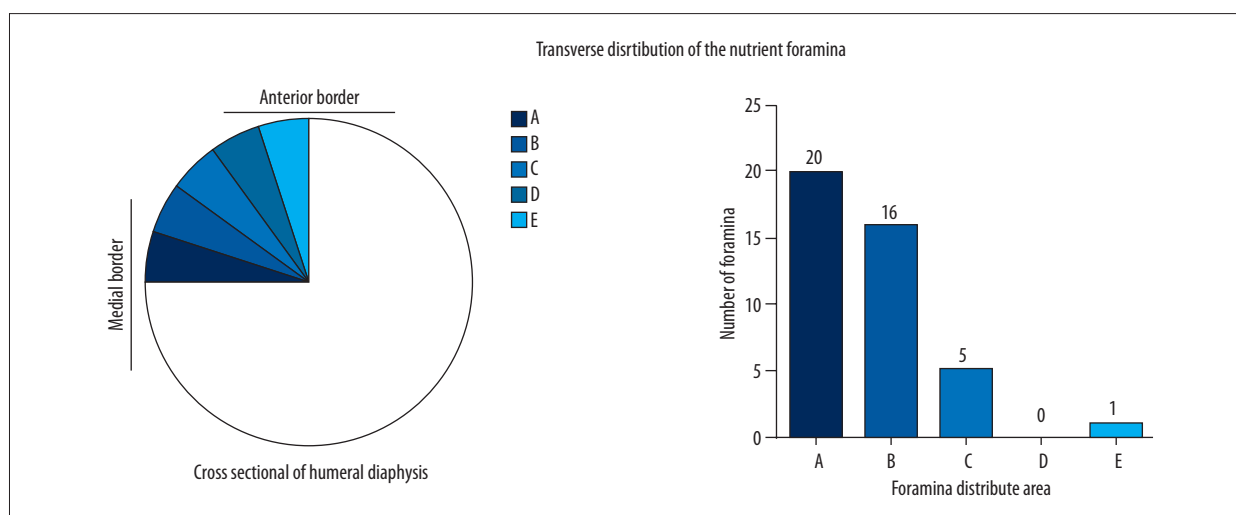


Figure 6. The graph of transverse distribution showed that there was a highly significant tendency for the foramina to be medial (97.62%).

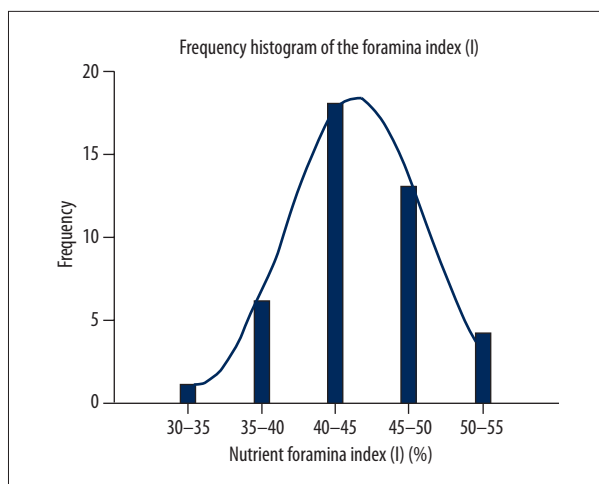


Figure 7. The frequency histogram of the foramina index (I) showed that the majority (73.81%) were located with a foramina index of 40–50%.

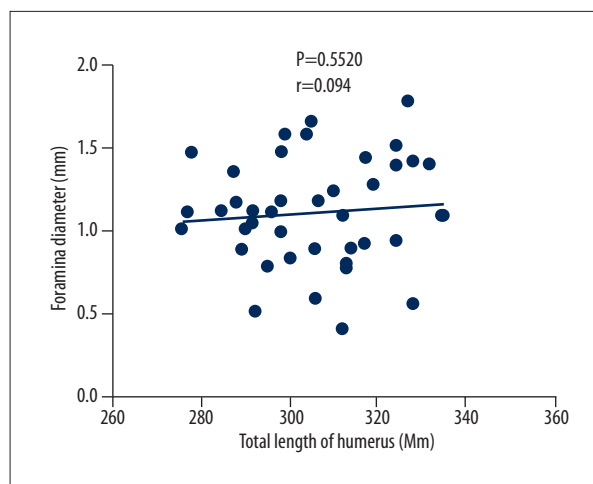


Figure 9. Scattergram shows no relationship between the foramina diameter and the total length of the humerus.

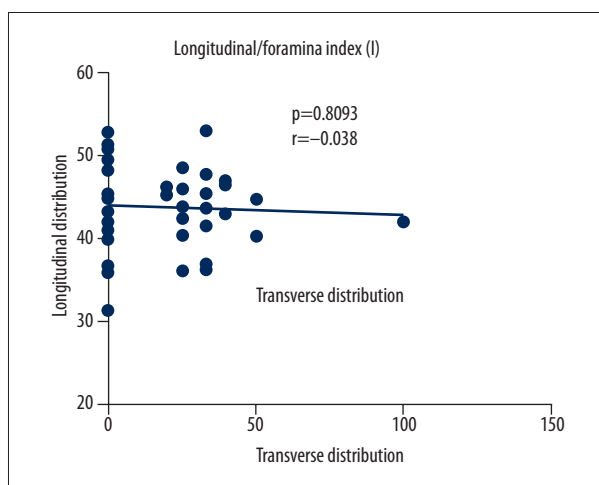


Figure 8. Scattergram shows no significant relationship between transverse and longitudinal distribution. No significant trend line was found.

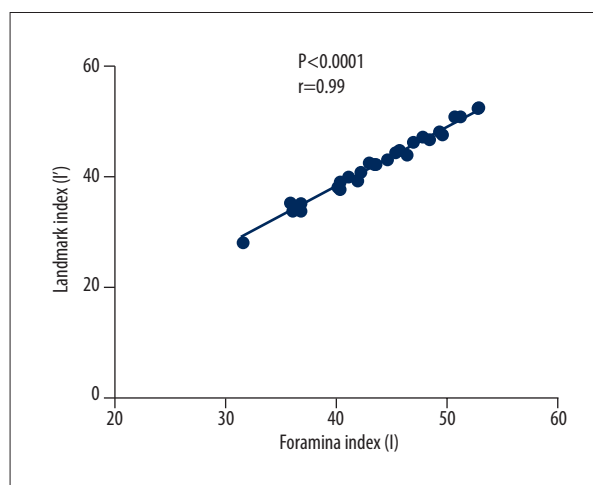


Figure 10. Scattergram shows a strong correlation between the foramina index (I) and the landmark index (I').

Table 2. Statistic data of nutrient foramina on different sides.

	Mean number	Mean diameter (mm)	Mean horizontal distribution	Mean TL (mm)	Mean I (%)	Mean I' (%)
L	1.05	1.13±0.31	20.99±17.16%	305.29±33.38	45.03±3.52	43.66±3.78
R	1.16	1.10±0.34	16.21±24.92%	304.95±16.31	42.61±5.79	40.97±6.33

revealed that the main blood supply to the shaft of the humerus enters through a restricted surface area on the anteromedial aspect of the distal half of the shaft. This finding was consistent with most previously reported studies [1,2,4,5,15,23].

Among these studies, only Carroll and Forriol investigated the relationship between nutrient foramina and the surrounding

muscles. Carroll measured the distances from the foramen to the apex of the deltoid insertion [15]. Forriol found that the location of the nutrient foramina was below the insertion of the coracobrachialis muscles [4]. Because the main nutrient arteries enter the humerus medially, it is appropriate to observe the relative locations between the nutrient foramina and the medial muscles. Our findings were consistent with

those of Forriol. We believe this information will assist surgeons in locating the nutrient foramina during surgery, thereby preserving the circulation in the region. Kizilkanat suggested a direct relationship between the position of the nutrient foramina and a continuous blood supply because the foramina were always located near major muscle attachments [2]. This may also explain the location of the nutrient foramina in the diaphyseal humeri.

The observation that the majority of the humeri had a single nutrient foramen is consistent with most studies, including those conducted with different races [1,2,4,5,13,15,23]. As we observed, some authors also reported a small number of humeri with no foramina [5,22–24]. Nutrient arteries divide into ascending and descending arteries after entering the cortex of the bone [10]. In the humerus, this division may take place outside the cortex, with each branch having its own canal and nutrient foramen [1]. This could explain the humeri with two foramina that were observed by our team and by other researchers. In Mysorekar's study, 42% of the specimens (from Hindu patients) had more than one nutrient foramen, and 19% of the foramina were found in the spiral groove [22]. Because the other two authors from India reported conclusions similar to those of most studies, we rejected the idea that the differences observed could be attributed to race; instead, we surmised that Mysorekar might have noted the foramina of both the main and accessory nutrient arteries on the basis of Laing's definition [1]. Laing and Forriol reported that the main nutrient foramina were always found on the anteromedial surface of the bone [1,4]. Laing also stated that one or several accessory arteries of the humerus arise from the profunda brachii and enter the posterior surface in the spiral groove [1]. This can explain the humeri that were observed to have more than two foramina or foramina on the posterior surface. The accessory nutrient arteries varied in number, and their foramina were too small to identify with the naked eye [1,4]. Therefore, the main nutrient foramina are more clinically meaningful during surgery.

Previous studies have focused largely on the direction and orientation of the nutrient foramina. Some authors have proposed theories to account for the generally consistent direction of the nutrient foramina as well as the anomalously directed ones. Among these, the "vascular theory" proposed by Hughes and favored by most authors offers the best explanation for both the normal nutrient foramina and anomalies [11,23,24,27,28]. Hughes stated that the foramina were directed away from the growing end, which was the proximal end in the case of the humerus, and anomalous foramina are frequently observed in the femur but rarely occur in the radius and other bones. In his article, Hughes also noted that anomalous foramina were extremely rare in the human femur but were common in other species [28]. In the present study, we observed that the foramina were consistently directed toward the elbow. Previous authors have demonstrated that the obliquity and location of

the nutrient foramina are not significantly correlated with the known bone age [22,24], which supports the vascular theory.

The diameter of the nutrient foramina in human long bones has been reported in only a few papers. Because there have been no reference data on the humerus to date, the results reported here are novel data. In some studies, when a bone had more than one foramen, the larger was considered the main foramen [15,22]. Mysorekar reported reciprocity between foraminal sizes in humeri with two foramina [22]. In the studies of Kizilkanat and Longia, on the other hand, some humeri were found to have two nutrient foramina, neither of which was dominant and with no reciprocity observed in their size [2,23]. In our series, we observed one humerus that had two foramina with the same diameters (Specimen 10). We also observed no relationship between the foraminal size and their proximal or distal location. Some authors discussed the concept of acquired disposition [15,25]. Carroll observed a significantly greater proportion of large foramina on the right side and attributed this to the increased function of the right arm, which is usually dominant [15]. Sendemir proposed that the difficult living conditions experienced by warriors might play a role in the differences observed between ancient and modern humans after studying the lower limb long bones of 305 unearthed ancient skeletons [25]. We analyzed the data from our sample and found no significant differences between left and right sides ($p=0.713$). Because all of our specimens were Chinese, this observation may not necessarily be extrapolated to other populations.

According to Patake, the number of foramina is not significantly related to the length of the bone [27]. In our series, the mean total bone length was 305.12 ± 16.29 mm. We analyzed the relationship between foramen size and humerus length and found no correlation ($r=0.094$, $p=0.552$). This suggests that clinicians cannot estimate the size of nutrient arteries by their patients' body size.

There is no currently available method for comparing data from different studies other than the foramina index [25,28]. Because this is a theoretical parameter that cannot be applied to clinical practice, we introduced the landmark index. The epicondyles are more prominent than the proximal landmarks, and the medial epicondyle is on the same border as the nutrient foramina; therefore, we modified the indices by calculating them from the distal end. One method based on specific landmarks has been applied by Carroll, who measured the distance between the foramen and the medial epicondyle. However, he reported these in the form of an absolute distance, which could be easily affected by differences in the total length of the humerus [15]. In our study, the foramina index was similar to those reported in previous studies after conversion. We also found a strong correlation between the two indices, with a correlation coefficient of 0.994 ($p<0.0001$).

This suggests that the foramina indices reported in previous works could be used as the landmark index in clinical practice.

Due to the differences in methodology and in the definition of foramina, it was difficult to compare data on the transverse location. While there was no standard measurement, there was a tendency for nearly all of the foramina in our study to lie on a longitudinal area near the medial border, which was consistent with previous studies [1,2,4,13,15,22,23]. Carroll found that the medial foramina were found further distally and verified this finding statistically [15]. In our data, while no significant correlation was found between transverse and longitudinal distribution, the scattergram did confirm the tendency for the foramina to be medial. Future studies on the aspect of transverse distribution will be necessary for a better understanding of these anatomic relationships.

When dealing with humeral shaft fractures, a good understanding of anatomy of nutrient foramina can help clinicians to assess if the fracture passes through the foraminal area. If this is the case, clinicians should be aware that the nutrient artery might be impaired and this might lead to poor prognosis. Great caution should be exercised in the management of these cases. When the nutrient artery is disrupted, the humeral shaft is fed by accessory arteries [29]. Therefore, minimal invasive technique or anterior approach would be preferable if surgical options are considered.

The knowledge of anatomy of nutrient foramina is also crucial when surgeries are required in cases where the nutrient artery is not impacted or the dissection of the anteromedial humerus is necessary. Since the anatomical structures are located by palpable landmarks in surgeries, the landmark index could efficiently help surgeons to locate the foraminal area and avoid disturbing the nutrient foramina.

Understanding the foramina is also essential in the reconstructive and plastic surgery of tumor resection, traumatic or septic skeletal defects, and fracture nonunion [2,9,11,13,23,25,30]. While adequate resection with large safety margins decreases

the chance of osteomyelitis and tumor recurrence [9,30], the indices can help to determine the safety limits of resection.

Large bony defects in the upper extremity, with or without infection, remain difficult to treat. Free vascular bone grafting, i.e., vascularized fibular graft (VFG), has been successfully used as a reconstruction option in patients with bony defects of the humerus. A thorough understanding of the blood supply to the humerus is critically important to the success of this procedure [9,30–33]. The landmark index can help to locate the main nutrient artery for vascular anastomoses.

The major limitation of the current study was that the number of the specimens was relatively small. However, the sample size was still larger than the previous anatomy studies of the humerus [34,35]. Furthermore, a study with more specimens has shown little variation in the vascular anatomy of the humerus [36].

Conclusions

The humerus has one or two main nutrient foramina on the anteromedial aspect of the distal half of the shaft that are directed toward the elbow. There is no reciprocity in humeri with two foramina. There is no correlation between the size and distribution of foramina. Surgeons should protect any nutrient artery in surgeries. The size of the nutrient artery cannot be inferred by acquired disposition or body shape in clinical practice. Both the foramina index and the landmark index can help clinicians locate the nutrient artery. Fractures passing through the foraminal area may lead to poor prognosis. The dissection of this region should be avoided in surgeries, and the accessory arteries should be protected when the main nutrient artery is disturbed. The location of nutrient foramina is also essential in reconstructive and plastic surgery.

Conflict of interest

There is no conflict of interest in relation to this article.

References:

- Laing PG: The arterial supply of the adult humerus. *J Bone Joint Surg Am*, 1956; 38-A: 1105–16
- Kizilkanat E, Boyan N, Ozsahin ET et al: Location, number and clinical significance of nutrient foramina in human long bones. *Ann Anat*, 2007; 189: 87–95
- Coolbaugh CC: Effects of reduced blood supply on bone. *Am J Physiol*, 1952; 169: 26–33
- Forriol Campos F, Gomez Pellico L, Gianonatti Alias M, Fernandez-Valencia R: A study of the nutrient foramina in human long bones. *Surg Radiol Anat*, 1987; 9: 251–55
- Murlimanju BV, Prashanth KU, Prabhu LV et al: Morphological and topographical anatomy of nutrient foramina in human upper limb long bones and their surgical importance. *Rom J Morphol Embryol*, 2011; 52: 859–62
- Trueta J: Blood supply and the rate of healing of tibial fractures. *Clin Orthop Relat Res*, 1974; 105: 11–26
- Welch JA, Boudrieau RJ, Delardin LM, Spodnick GJ: The intraosseous blood supply of the canine radius: Implications for healing of distal fractures in small dogs. *Vet Surg*, 1997; 26: 57–61
- Rhineland FW: Tibial blood supply in relation to fracture healing. *Clin Orthop Relat Res*, 1974; 105: 34–81
- Kirschner MH, Menck J, Hennerbichler A et al: Importance of arterial blood supply to the femur and tibia for transplantation of vascularized femoral diaphyses and knee joints. *World J Surg*, 1998; 22: 845–51; discussion 852
- Wilson JW: Vascular supply to normal bone and healing fractures. *Semin Vet Med Surg (Small Anim)*, 1991; 6: 26–38

11. Ahn D: Anatomical study on the diaphyseal nutrient foramen of the femur and tibia of the German shepherd dog. *J Vet Med Sci*, 2013; 75: 803–8
12. Menck J, Dobler A, Dohler JR: [Vascularization of the humerus]. *Langenbecks Arch Chir*, 1997; 382: 123–27 [in German]
13. Nagel A: The clinical significance of the nutrient artery. *Orthop Rev*, 1993; 22: 557–61
14. Pidhorz L: Acute and chronic humeral shaft fractures in adults. *Orthop Traumatol Surg Res*, 2015; 101: S41–49
15. Carroll SE: A study of the nutrient foramina of the humeral diaphysis. *J Bone Joint Surg Br*, 1963; 45-B: 176–81
16. Ekholm R, Adami J, Tidermark J et al: Fractures of the shaft of the humerus. An epidemiological study of 401 fractures. *J Bone Joint Surg Br*, 2006; 88: 1469–73
17. Bonafede M, Espindle D, Bower AG: The direct and indirect costs of long bone fractures in a working age US population. *J Med Econ*, 2013; 16: 169–78
18. Toivanen JA, Nieminen J, Laine HJ et al: Functional treatment of closed humeral shaft fractures. *Int Orthop*, 2005; 29: 10–13
19. Volgas DA, Stannard JP, Alonso JE: Nonunions of the humerus. *Clin Orthop Relat Res*, 2004; 419: 46–50
20. Sarmiento A, Zagorski JB, Zych GA et al: Functional bracing for the treatment of fractures of the humeral diaphysis. *J Bone Joint Surg Am*, 2000; 82: 478–86
21. Kanakaris NK, Giannoudis PV: The health economics of the treatment of long-bone non-unions. *Injury*, 2007; 38(Suppl. 2): S77–84
22. Mysorekar VR: Diaphyseal nutrient foramina in human long bones. *J Anat*, 1967; 101: 813–22
23. Longia GS, Ajmani ML, Saxena SK, Thomas RJ: Study of diaphyseal nutrient foramina in human long bones. *Acta Anat (Basel)*, 1980; 107: 399–406
24. Shulman SS: Observations on the nutrient foramina of the human radius and ulna. *Anat Rec*, 1959; 134: 685–97
25. Sendemir E, Cimen A: Nutrient foramina in the shafts of lower limb long bones: Situation and number. *Surg Radiol Anat*, 1991; 13: 105–8
26. Laing PG: The blood supply of the femoral shaft; An anatomical study. *J Bone Joint Surg Br*, 1953; 35-B: 462–66
27. Patake SM, Mysorekar VR: Diaphyseal nutrient foramina in human metacarpals and metatarsals. *J Anat*, 1977; 124: 299–304
28. Hughes H: The factors determining the direction of the canal for the nutrient artery in the long bones of mammals and birds. *Acta Anat (Basel)*, 1952; 15: 261–80
29. Gairola BJ, Metzler M: Humeral shaft fracture with brachial artery injury. *Clin Orthop Relat Res*, 1986; 154–61
30. Noaman HH: Management of upper limb bone defects using free vascularized osteoseptocutaneous fibular bone graft. *Ann Plast Surg*, 2013; 71: 503–9
31. Guo QF, Xu ZH, Wen SF et al: Value of a skin island flap as a postoperative predictor of vascularized fibula graft viability in extensive diaphyseal bone defect reconstruction. *Orthop Traumatol Surg Res*, 2012; 98: 576–82
32. Kerfant N, Valenti P, Kilinc AS, Falcone MO: Free vascularised fibular graft in multi-operated patients for an aseptic non-union of the humerus with segmental defect: Surgical technique and results. *Orthop Traumatol Surg Res*, 2012; 98: 603–7
33. Tanaka K, Maehara H, Kanaya F: Vascularized fibular graft for bone defects after wide resection of musculoskeletal tumors. *J Orthop Sci*, 2012; 17: 156–62
34. Meyer C, Alt V, Hassanin H et al: The arteries of the humeral head and their relevance in fracture treatment. *Surg Radiol Anat*, 2005; 27: 232–37
35. Gardner MJ, Voos JE, Wanich T et al: Vascular implications of minimally invasive plating of proximal humerus fractures. *J Orthop Trauma*, 2006; 20: 602–7
36. Gerber C, Schneeberger AG, Vinh TS: The arterial vascularization of the humeral head. An anatomical study. *J Bone Joint Surg Am*, 1990; 72: 1486–94