

A Suturing Method without Exposure of Barbs on the Wound Surface Using a Unidirectional Barbed Monofilament Absorbable Suture (STRATAFIX™) in Laparoscopic Myomectomy: A Feasibility Study

Yoshiaki Ota^{1#}, Kuniaki Ota^{2#}, Toshifumi Takahashi^{2*}, Soichiro Suzuki¹, Rikiya Sano¹, Mitsuru Shiota¹

¹Department of Gynecological Oncology, Kawasaki Medical School, Kurashiki, ²Fukushima Medical Center for Children and Women, Fukushima Medical University, Fukushima, Japan

[#]Both authors contributed equally to this work

Abstract

Objectives: We examined whether a new suturing method that used a single-thread unidirectional barbed suture without exposing the barbs on the wound surface was acceptable compared with the conventional suture method during laparoscopic myomectomy (LM).

Materials and Methods: This was a retrospective study. The subjects were 26 women who underwent LM for symptomatic uterine fibroids. The operative time, amount of blood loss, and number of threads used were compared between a group in which suturing was performed with a conventional synthetic absorbable suture (conventional suture group, $n = 13$) and a group in which suturing was performed using a barbed suture (barbed suture group, $n = 13$).

Results: Operative time in the barbed suture group was significantly shorter than that in the conventional suture group, while blood loss during LM in the barbed suture group was significantly lower than that in the conventional suture group. The number of threads used in the conventional suture group was significantly larger than that in the barbed suture group. No complications were observed in both the groups during LM.

Conclusion: This new technique using a barbed suture is safe and feasible for LM.

Keywords: Laparoscopy, leiomyoma, minimally invasive surgical procedures, myomectomy, suture techniques

INTRODUCTION

Laparoscopic myomectomy (LM) is widely used as a standard treatment for women with symptomatic fibroids.^[1] There are several problems associated with performing LM, such as the number, size, and location of the fibroids. The most important problem associated with performing LM is the strength of myometrial closure after fibroid enucleation, since spontaneous uterine rupture has occurred LM patients.^[2,3]

A barbed suture represents a new concept where the suture self-anchors at every 1 mm of tissue, eliminating the need to

tie knots, resulting in more secure sutures.^[4] Use of the barbed suture technique reduce suturing time, blood loss, and operative time for gynecologic laparoscopic surgeries, including LM.^[5-7]

Although barbed sutures have advantages in gynecologic laparoscopic surgery, there are also disadvantages, such as high thread cost and intestinal involvement, due to exposed barbs on the wound surface. Intestinal obstruction has been caused by barb exposure on the wound surface in LM.^[8-10]

Article History:

Submitted: 23 August 2020

Revised: 12 October 2020

Accepted: 23 December 2020

Published: 30 April 2021

Video Available on: www.e-gmit.com

Access this article online

Quick Response Code:



Website:
www.e-gmit.com

DOI:
10.4103/GMIT.GMIT_105_20

Address for correspondence: Prof. Toshifumi Takahashi, Fukushima Medical Center for Children and Women, Fukushima Medical University, 1 Hikarigaoka, Fukushima City, Fukushima 960-1295, Japan.
E-mail: totakaha@fmu.ac.jp

This is an open access journal, and articles are distributed under the terms of the Creative Commons Attribution-NonCommercial-ShareAlike 4.0 License, which allows others to remix, tweak, and build upon the work non-commercially, as long as appropriate credit is given and the new creations are licensed under the identical terms.

For reprints contact: WKHLRPMedknow_reprints@wolterskluwer.com

How to cite this article: Ota Y, Ota K, Takahashi T, Suzuki S, Sano R, Shiota M. A suturing method without exposure of barbs on the wound surface using a unidirectional barbed monofilament absorbable suture (STRATAFIX™) in laparoscopic myomectomy: A feasibility study. *Gynecol Minim Invasive Ther* 2021;10:104-8.

Herein, we developed a new suturing method that used a single-thread unidirectional barbed suture with a single thread and did not expose barbs on the wound surface during LM and evaluated whether it was clinically acceptable compared with the conventional suturing method.

MATERIALS AND METHODS

Ethics

This study was approved by the institutional review board of Kawasaki Medical School (approval no. 3959). Patients who underwent LM provided signed informed consent after receiving counseling on their treatment options.

Study design and setting

This was a retrospective study based on medical records. Data used in this study were collected from January to June 2020. Conventional sutures were used for cases from January to March 2020, and single-thread suturing methods with unidirectional monofilament barbed suture were used for cases from April to July 2020. Cases were divided into the conventional and barbed suture groups, accordingly.

Selection of patients who underwent laparoscopic myomectomy

LM was performed in women who wanted to preserve their uterus and had experienced menorrhagia, dysmenorrhea, pressure symptoms, and infertility. Patients who underwent LM provided signed informed consent after receiving counseling on their treatment options. All patients underwent magnetic resonance imaging to determine the fibroid number, size, and location of the fibroids. Individual fibroids larger than 10 cm in size and type 0 and 1 submucosal fibroids were excluded from the indications for LM. No exclusion criteria were established for the number of uterine fibroids. Other exclusion criteria were as follows: women with age ≥ 40 years, body mass index ≥ 30 , pregnancy, and systemic complications such as severe cardiovascular disease, pulmonary obstructive disease, and a history of hip replacement surgery.

Laparoscopic surgery setting

All surgical procedures were performed by a single surgeon; LM was performed in the Trendelenburg position under general anesthesia with a four-port 2D/4K laparoscopy system (VISERA 4K UHD Camera Control Unit; Olympus Medical Systems, Tokyo, Japan). A 10-mm trocar (ENDOPATH XCEL[®], Ethicon Endo-Surgery, Cincinnati, OH, USA) for the zero-degree laparoscope was introduced intraumbilically; 3 additional 5-mm lateral trocars (ENDOPATH XCEL[®], Ethicon Endo-Surgery, Cincinnati, OH, USA) were placed centrally and on the left and right flanks under direct vision. The surgeon used the central and left-sided lateral ports to perform most of the procedures. A uterine manipulator was used to mobilize the uterus.

Laparoscopic myomectomy procedure

After setting all trocars, the small intestine was evacuated up to the upper abdomen to secure the laparoscopic operative field. The number and location of fibroids were confirmed and 1 IU of diluted vasopressin in 70 mL normal saline was injected into the uterine wall to reduce intraoperative bleeding. The serosa overlying the fibroid was incised with ultrasonic scissors (Harmonic[®] HD1000i, Ethicon Endo-Surgery, Tokyo, Japan) or a monopolar electrode (ENDOPATH[®] PROBE PLUS II System, Ethicon Endo-Surgery, Tokyo, Japan) until the fibroid pseudocapsule was reached. When the cleavage plane was identified, the fibroid was fixed with a 5-mm grasper and manually enucleated by traction. Hemostasis was achieved using a bipolar coagulation electro-surgical unit.

In the conventional suture group, a size 0 Vicryl suture in a CT-1 needle (Ethicon Endo-Surgery, Tokyo, Japan) was used to close the myometrium either with two-layer continuous or interrupted sutures or, depending on the incision depth, single-layer sutures. A 45-cm Vicryl piece was cut into 30-cm pieces and used depending on the number of fibroids; 3–6 pieces were used to suture the myomectomy sites. After the first layer was sutured, the second layer (including seromuscular layers) was sutured using the “baseball” suture technique. All myomectomy sites were sutured similarly.

In the barbed suture group, a size 0 STRATAFIX[®] Symmetric PDS Plus[®] (Ethicon Endo-Surgery, Tokyo, Japan), an absorbable unidirectional barbed suture, in a CT-1 needle was used to close the myometrium with a two-layer continuous suture or, depending on the incision depth, a single-layer suture. The enucleation sites of all uterine fibroids were sutured with a single 45-cm thread. The first layer of sutures was made wider apart than conventional continuous sutures, which was advantageous for hemostasis, as it allows for the tight adherence of multiple muscle layers. The second layer (including seromuscular layers) was sutured using the “baseball” suture technique with a barbed thread, which was different from the common “baseball” suture. In a common “baseball” suture, the needle is inserted through the muscle layer inside the wound surface and passed through the serosal surface separate from the wound edge. The use of barbed thread in this suturing method results in exposed barbs on the muscle fiber surface. In the “baseball” suture with barbed thread (unlike the usual “baseball” suture), the needle with a barbed suture was inserted inside the wound surface and passed through the serosa adjacent to the wound edge to prevent the barbs from surfacing. After suturing one myomectomy site, the needle with the barbed suture was passed through the muscle layer to another myomectomy site; then, the same suture was performed using a barbed thread [Figure 1 and Video 1 (Video 1 is also

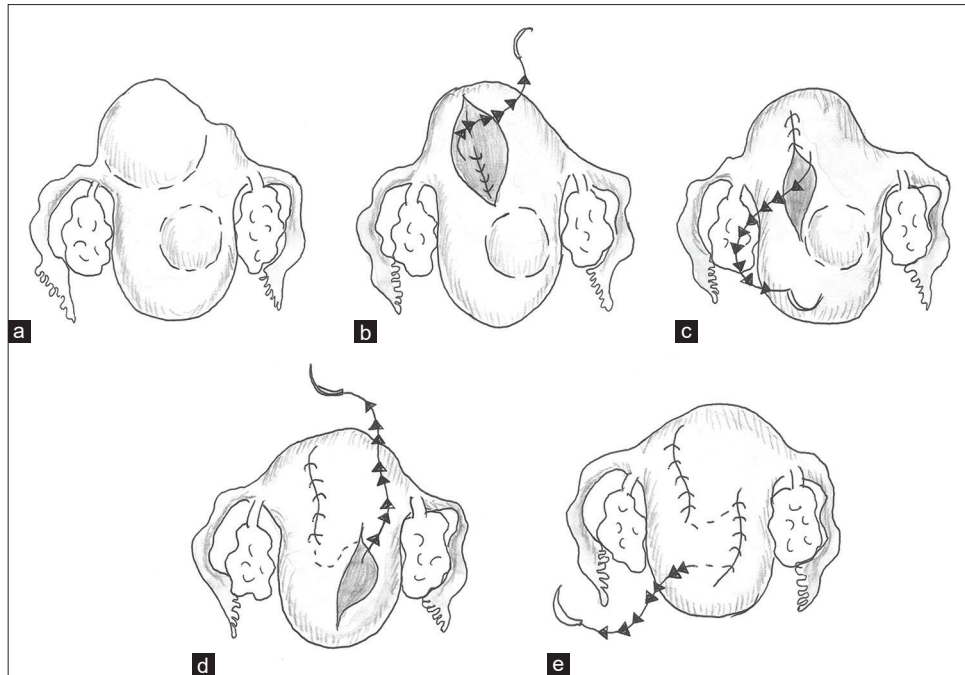


Figure 1: Procedure for the new suturing method using a barbed suture during laparoscopic myomectomy. The myometrium was closed with a two-layer continuous suture using a size 0 STRATAFIX Symmetric PDS Plus in a CT-1 needle (Ethicon Endo-Surgery, Tokyo, Japan). Enuclation sites of all uterine fibroids were sutured with a single 45-cm thread. The first layer of sutures was made wider than the conventional continuous suture, which is advantageous for hemostasis, as it allows for tight muscle layer adherence (a and b, white arrow indicates point of needle insertion; yellow arrow indicates the suture direction). The “baseball” suture technique with a barbed thread was used for the second suture layer. In the “baseball” suture with a barbed thread, the needle with a barbed suture was inserted from the inside and passed through the serosa adjacent to the wound edge to prevent barb surfacing (c, yellow arrow indicates suture direction). After suturing one myomectomy site (d), the needle with the barbed suture was passed through the muscle layer to another myomectomy site; then, the same suture was performed (e)

available at <http://www.apagemit.com/page/video/show.aspx?num=268&page=1>]. After suturing was completed, the barbed thread was carefully cut to prevent the barbs from surfacing.

After suturing, a posterior 1–2-cm transverse colpotomy was performed laparoscopically, precisely in the midline of the posterior vaginal fornix, demarcated using a Vagi-Pipe® (Hakko Medical, Nagano, Japan). All enucleated fibroids were removed through the colpotomy incision. Finally, the surface of the uterus was covered with a cellulose absorbable adhesion barrier (Interseed, Ethicon Endo-Surgery, Tokyo, Japan). The pneumoperitoneum was desufflated and trocars were removed, followed by closure of all trocar sites. All extirpated tissues underwent histopathological examination to confirm the fibroids.

Evaluation of parameters

We compared the clinical validity of a new barbed suturing method using STRATAFIX® Symmetric PDS Plus® with the conventional method using a Vicryl suture. Clinical validity was evaluated by the operative time, blood loss, and number of threads used. Operative time was calculated from the time of pneumoperitoneum creation through desufflation. The amount of bleeding was estimated by subtracting the

amount of water used for irrigation from the total suction volume.

Statistical analysis

Data are shown as median (range); all statistical analyses were performed with EZR (Saitama Medical Center, Jichi Medical University, Saitama, Japan), which is a graphical user interface for R (The R Foundation for Statistical Computing, Vienna, Austria).^[11] Parameters were compared between the conventional and barbed suture groups using the Mann–Whitney *U*-test. $P < 0.05$ was considered statistically significant.

RESULTS

Patient characteristics and operative parameters are shown in Table 1. There were no significant differences in age, body mass index, number of fibroids, fibroid maximum diameter, and total weight of the fibroids removed between the conventional suture ($n = 13$) and the barbed suture groups ($n = 13$). Operative time in the barbed suture group was significantly shorter than that in the conventional suture group. Blood loss during LM in the barbed suture group was significantly lower than that in the conventional suture group. The number of threads used in the conventional suture group was significantly larger

Table 1: Patients' characteristics and operative parameters in conventional suture group and barbed suture group data

	Conventional suture group (n=13)	Barbed suture group (n=13)	P
Age (years)	34 (28–40)	34 (29–39)	0.98
BMI (kg/m ²)	21.6 (19.1–24.1)	20.3 (19.9–24.8)	0.56
Number of fibroids	6 (4–7)	5 (3–7)	0.08
Maximum diameter of each fibroid	8.4 (7.1–9.1)	8.4 (7.1–9.0)	0.76
Total weight of removed fibroids	267 (199–301)	255 (223–289)	0.61
Operating time (min)	120 (92–128)	98 (80–113)	<0.001
Bleeding volume	245 (201–260)	190 (159–223)	<0.001
Number of used threads	4 (3–5)	1	0.004

Data represent the median (range). BMI: Body mass index

than that in the barbed suture group. No complications were observed in both the groups during LM. All the specimens that were removed were histopathologically confirmed as uterine fibroids. During the 1st month after the surgery, no complications such as intra-abdominal bleeding due to suture failure, postoperative infection, or hematoma formation at the fibroid enucleation site were observed in both the groups.

DISCUSSION

This study showed that, when compared with conventional suturing, the new suturing method with a unidirectional barbed suture is feasible for LM. The new suturing method is superior in terms of shortening operative time and reducing the amount of blood loss; moreover, it is not inferior to the conventional method in terms of cost.

First, the point of this new suturing method that uses a barbed suture is that it ensures hemostasis without exposing barbs on the wound surface. In LM, it is common to follow a narrow-pitch design when suturing to achieve hemostasis. However, suturing with a large pitch is advantageous for hemostasis, since this allows for muscle layer involvement when suturing. When the second suture is performed, the needle is inserted at a position far from the wound edge, and the muscle layer is sutured largely by increasing the pitch, like with the first suture. As a result, the barbs reach the wound surface. In other words, in order to prevent the barbs from reaching the wound surface in the second layer when using a barbed thread, it is necessary to insert the needle from one wound edge to the next.

The advantage of this suturing method that does not expose the barbs on the wound surface is the prevention of adhesion between the barbs and the intestine, which is followed by the development of ileus. It has been reported that, when the barbs were exposed on the wound surface, they caused bowel entanglement and subsequent intestinal obstruction.^[10,12] Einarsson *et al.* reported a technique for suturing the first layer with a barbed suture and the second layer with a nonbarbed suture; the barbs were not exposed on the wound surface which prevented the ileus caused by bowel entanglement.^[6]

Our technique uses a barbed suture in the second muscle layer, but “burying” the barbs within the muscular layer prevents their exposure on the wound surface. In addition, covering of the myomectomy sites with an absorbable adhesion barrier is recommended in anticipation of barbs appearing due to muscle shrinkage after surgery. This is also effective in preventing pelvic adhesions.

Second, the point of this new suturing method with a barbed suture is that multiple enucleation sites are sutured with a single barb. After suturing one fibroid enucleation site, the needle is inserted into the muscle layer, and brought out at the bottom of the wound at another fibroid enucleation site, and the other site is sutured. Using this method, multiple enucleation sites could be sutured with a single barbed thread.

Suturing with a single barbed thread has two advantages: less time required for inserting and removing the needle through the trocar, and reduced cost by not using multiple threads. A barbed suture is more expensive than conventional synthetic absorbable suture. In this study, all cases were sutured with a single barbed thread. The prices of barbed or Vicryl sutures vary between hospitals; therefore, it is not possible to evaluate them accurately for all institutions. However, the difference is likely to be several times that of the actual price per thread. Since the median number of Vicryl threads used in a single-session surgery was 4 (range, 3–5), the total cost of barbed sutures is comparable to that of the conventional method using Vicryl sutures.

The limitations of this study were the subject selection bias due to the retrospective nature of the study. A prospective randomized controlled trial is required in this regard. In addition, in this study, it was necessary to examine whether similar procedures could be performed by other surgeons who had performed suturing operations by one surgeon, in order to eliminate variations between surgeons.

CONCLUSION

The new suturing method that used barbed sutures resulted in shorter operative time and less blood loss during LM,

compared to the conventional suturing technique that used Vicryl sutures. In addition, the cost of the new method with a single barbed suture was comparable to the conventional method with Vicryl sutures. This new technique using a barbed suture is safe and feasible for LM.

Acknowledgment

The drawing was greatly assisted by Ikuko Ota. We thank Professor Hideki Mizunuma for his encouragement for this study.

Financial support and sponsorship

Nil.

Conflicts of interest

Prof. Mitsuru Shiota, an editorial board member at *Gynecology and Minimally Invasive Therapy*, had no role in the peer review process of or decision to publish this article. The other authors declared no conflicts of interest in writing this paper.

REFERENCES

1. Sizzi O, Rossetti A, Malzoni M, Minelli L, La Grotta F, Soranna L, *et al.* Italian multicenter study on complications of laparoscopic myomectomy. *J Minim Invasive Gynecol* 2007;14:453-62.
2. Mahajan N, Moretti ML, Lakhi NA. Spontaneous early first and second trimester uterine rupture following robotic-assisted myomectomy. *J Obstet Gynaecol* 2019;39:278-80.
3. Wachira L, de Silva L, Orangun I, Shehzad S, Kulkarni A, Yoong W. Spontaneous preterm recurrent fundal uterine rupture at 26 weeks following laparoscopic myomectomy. *J Obstet Gynaecol* 2019;39:731-2.
4. Murtha AP, Kaplan AL, Paglia MJ, Mills BB, Feldstein ML, Ruff GL. Evaluation of a novel technique for wound closure using a barbed suture. *Plast Reconstr Surg* 2006;117:1769-80.
5. Alessandri F, Remorgida V, Venturini PL, Ferrero S. Unidirectional barbed suture versus continuous suture with intracorporeal knots in laparoscopic myomectomy: A randomized study. *J Minim Invasive Gynecol* 2010;17:725-9.
6. Einarsson JI, Chavan NR, Suzuki Y, Jonsdottir G, Vellinga TT, Greenberg JA. Use of bidirectional barbed suture in laparoscopic myomectomy: Evaluation of perioperative outcomes, safety, and efficacy. *J Minim Invasive Gynecol* 2011;18:92-5.
7. Angioli R, Plotti F, Montera R, Damiani P, Terranova C, Orzani I, *et al.* A new type of absorbable barbed suture for use in laparoscopic myomectomy. *Int J Gynaecol Obstet* 2012;117:220-3.
8. Kindinger LM, Setchell TE, Miskry TS. Bowel obstruction due to entanglement with unidirectional barbed suture following laparoscopic myomectomy. *Gynecol Surg* 2012;9:357-8.
9. Burchett MA, Mattar SG, McKenna DT. Iatrogenic intestinal and mesenteric injuries with small bowel volvulus following use of barbed suture during laparoscopic myomectomy. *J Laparoendosc Adv Surg Tech A* 2013;23:632-4.
10. Lee ET, Wong FW. Small bowel obstruction from barbed suture following laparoscopic myomectomy-A case report. *Int J Surg Case Rep* 2015;16:146-9.
11. Kanda Y. Investigation of the freely available easy-to-use software "EZ" for medical statistics. *Bone Marrow Transplant* 2013;48:452-8.
12. Clapp B, Klingsporn W, Lodeiro C, Wicker E, Christensen L, Jones R, *et al.* Small bowel obstructions following the use of barbed suture: A review of the literature and analysis of the MAUDE database. *Surg Endosc* 2020;34:1261-9.