



ELSEVIER

Contents lists available at ScienceDirect

## Leukemia Research Reports

journal homepage: [www.elsevier.com/locate/lrr](http://www.elsevier.com/locate/lrr)

## Case report

# Acute myeloid leukemia arising from a donor derived premalignant hematopoietic clone: A possible mechanism for the origin of leukemia in donor cells



Mark A. Dickson, Esperanza B. Papadopoulos, Cyrus V. Hedvat, Suresh C. Jhanwar\*, Renier J. Brentjens

Departments of Medicine (M.A.D., E.B.P., S.C.J., R.J.B.) and Pathology (S.C.J., C.V.H.), Memorial Sloan-Kettering Cancer Center, New York, N.Y. 10065, USA

## ARTICLE INFO

## Article history:

Received 30 May 2013

Received in revised form

7 April 2014

Accepted 8 April 2014

Available online 20 May 2014

## Keywords:

Donor leukemia

Acute secondary leukemia

Telomere length in translocation

Allogeneic bone marrow transplantation

Origin of donor leukemia mechanism

## ABSTRACT

During recent years, it has become increasingly evident that donor leukemia following allogeneic transplant may be more common than realized in the past. We identified five cases of potential donor leukemia cases during past five years. The precise mechanism of the origin of such leukemias, however, remains poorly defined. In this short communication, we report a well documented case of donor-derived *de novo* acute myeloid leukemia (AML) that developed fourteen years after allogeneic stem cell transplantation for treatment induced AML for his primary malignancy Immunoblastic lymphoma. This case allows us to postulate a possible mechanism of the origin of donor leukemia. The *de novo* AML clone contained a distinct cytogenetic abnormality, trisomy 11, which was simultaneously detected in preserved peripheral blood obtained at the time of transplantation as well as in the current bone marrow from an otherwise clinically and phenotypically normal donor. The findings from this unique case, provides insight into the process of leukemogenesis, and suggests that the sequence of events leading to leukemogenesis in this patient involved the senescence/apoptosis of normal donor hematopoietic cells due to telomere shortening resulting in the selective proliferation and transformation of this clone with MLL (mixed-lineage leukemia) gene amplification.

© 2014 The Authors. Published by Elsevier Ltd. This is an open access article under the CC BY-NC-ND license (<http://creativecommons.org/licenses/by-nc-nd/3.0/>).

## 1. Introduction

Donor-derived leukemias following allogeneic bone marrow transplantation are rare but may offer significant insights into the mechanisms of leukemogenesis. Since the first report of donor-derived leukemia in 1971, only 50 cases have been reported in the literature (reviewed in Ref. 1). A number of mechanisms have been proposed to explain donor-derived leukemogenesis including impaired immune surveillance in the recipient, transfer of oncogenic material from recipient to donor cells, or residual effects of conditioning chemotherapy or radiation [1]. Inadvertent transfer of leukemic blasts from a donor with undetected AML has also been reported. Other hematologic malignancies including acute lymphoblastic leukemia, chronic lymphocytic leukemia and non-Hodgkin lymphoma have also been accidentally transmitted [1]. Significantly, in these previously reported cases, the transmission was discovered when the malignancy was manifested in the donor [1].

We describe a novel case, wherein a patient with AML with inv (16) underwent allogeneic bone marrow transplantation from a

related sibling donor which contained a small subpopulation of premalignant stem cells with trisomy 11. Fourteen years following transplantation, this patient presented with a *de novo* AML derived from this inadvertently transmitted premalignant clone. Significantly, over time, this premalignant clone has remained quiescent but persisted in the donor.

## 2. Methods

Conventional cytogenetics and FISH analyses were performed employing routine methods. Donor-recipient DNA chimerism was studied by using semiquantitative PCR with fluorochrome-labeled primers for the polymorphic microsatellite markers D7S820 and D16S539 using the GenePrint fluorescent STR multiplex system (Promega, Madison, WI).

## 3. Results

A 42-year-old man was diagnosed with Stage IIIA immunoblastic lymphoma and treated with cyclophosphamide, doxorubicin, etoposide, bleomycin, vincristine, methotrexate and prednisone. He achieved a complete remission but 17 months later developed acute

\* Correspondence to: Department of Pathology, Memorial Sloan-Kettering Cancer Center, 1275 York Avenue, Box #147, New York, N.Y. 10065, USA.  
Tel.: +212 639 8895; fax: +212 794 5830.

E-mail address: [Jhanwars@mskcc.org](mailto:Jhanwars@mskcc.org) (S.C. Jhanwar).

myeloid leukemia (AML) with an *inv(16)(p13q22)* clonal cytogenetic abnormality, known to be associated with AML-M4 sub-type, as the sole abnormality detected by karyotype analysis. Standard induction therapy with cytarabine and idarubicin was administered and the patient achieved a complete remission. He subsequently underwent allogeneic stem cell transplantation from his 54 year old HLA-identical brother after conditioning with total-body irradiation, thiotepa and cyclophosphamide. The patient achieved a sustained complete remission. However, 14 years following transplantation, the patient developed fatigue and easy bruising. The laboratory findings included WBC count of 29,300/uL, 31% blasts, Hb 12.3gm/uL and platelets 29,000/uL. Bone marrow morphologic and flow cytometric profile was consistent with AML. The clonal abnormality detected by karyotype included a 47,XY,+11 (Fig. 1A), which was confirmed by FISH analysis (Fig. 1B). DNA chimerism assays of both peripheral blood and bone marrow from the patient at the time of relapse showed full donor chimerism, demonstrating that the leukemic clone was of donor origin (Fig. 1C).

At the time of this second AML diagnosis, the donor was well and without evidence of any hematologic disorder and normal male karyotype. However, FISH analysis revealed trisomy 11 in 2% of the cells analyzed (upper limit of normal <0.2%); frozen peripheral blood from the donor stored at the time of the initial

bone marrow transplantation 14 years earlier also showed trisomy 11 in 0.4% cells (Fig. 1D).

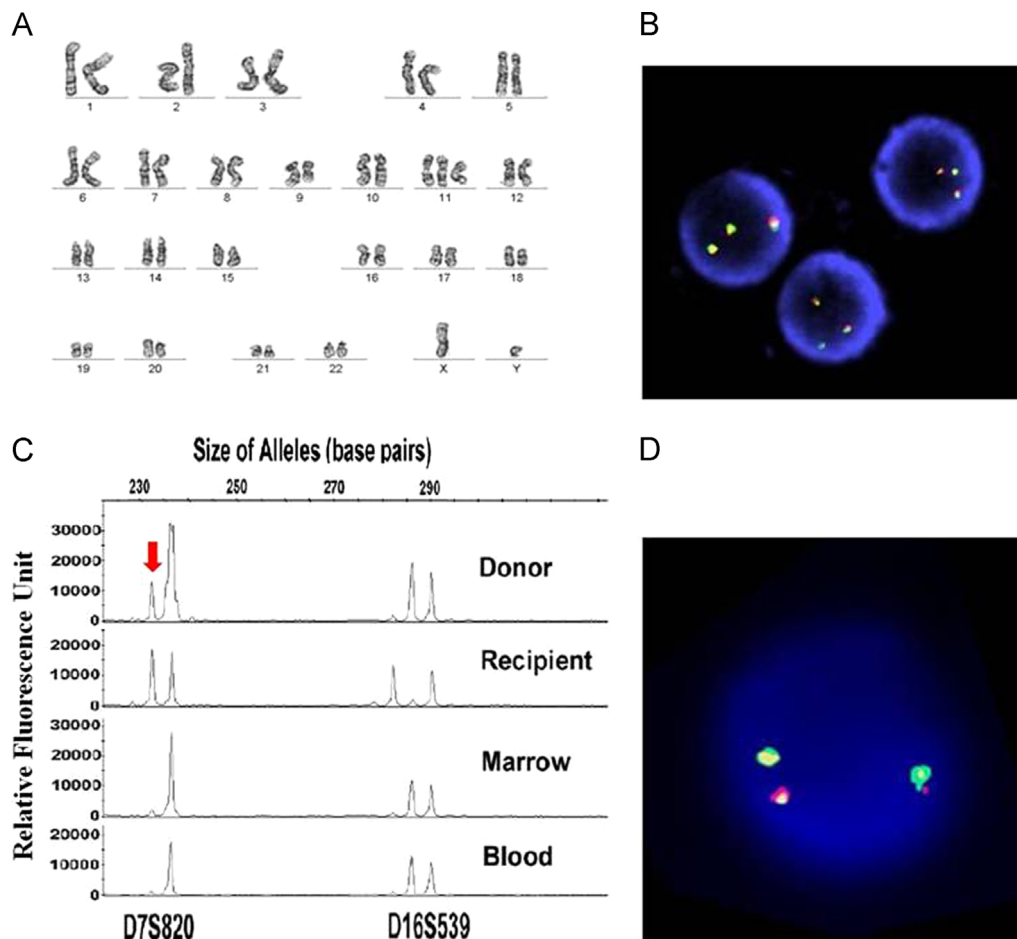
#### 4. Discussion

The presence of a low level of trisomy 11 in the donor's peripheral blood from the time of donation, as well as its persistence in his bone marrow 14 years later, suggest it was present at the time of stem cell donation and has, to date, followed an indolent clinical course.

This unique case, wherein a genetically abnormal premalignant clone, rather than a frankly malignant clone, was inadvertently transmitted from the donor to the patient and which subsequently transformed into leukemia in the recipient but not the donor. This malignant process required a long period of latency, and this case represents the longest reported interval from stem cell transplant to the development of a donor-derived leukemia.

The sequence of genetic and/or epigenetic events leading to selective proliferation and subsequent neoplastic transformation of the clone with trisomy 11 (three copies of MLL gene) may evoke several possibilities.

Immunodeficiency may facilitate the neoplastic transformation of a premalignant clone. Primary immunodeficiency is well documented in



**Fig. 1.** Analysis of patient and donor blood and bone marrow samples. (A) A G-banded karyotype shows a 47,XY,+11 chromosome constitution; a *del(9q)* was seen as a non-clonal abnormality only in this metaphase. (B) Interphase nuclei show three copies of the MLL gene in patient's marrow at the time of AML diagnosis; MLL probe was obtained from VYSIS, Inc (Des Plaines, IL). (C) Electropherogram of semiquantitative analysis of microsatellite markers with variable tetranucleotide repeats. The peripheral blood (mononuclear cells) of the donor is shown (Top Panel), followed by the buccal mucosa of recipient (Second panel), recipient bone marrow (Third panel) and recipient peripheral blood (Bottom panel) at the time of diagnosis of trisomy 11 AML, confirming the presence of donor hematopoietic cells with no evidence of recipient cells. PCR primers were fluorochrome-labeled and PCR products analyzed on an ABI 3730 automated DNA sequence analyser (PE Biosystems, Foster City, CA). Please note that a smaller peak (indicated by Red arrow) detected in donor mononuclear cells is due to overloading of the sample, as the marker D7S820 consists of only one specific allele. (D) Interphase nucleus to show three copies of the MLL gene in donor peripheral blood sample collected at the time of transplantation 14 years earlier.

patients with ataxia-telangiectasia (AT) and Bloom's Syndrome (BS) and such immune deficient states are known to permit clonal expansion of cells with underlying mutations in the lymphoid and myeloid systems respectively [2]. The primary immunodeficiency as a contributory factor in the development of donor leukemia in the patient is unlikely. Secondary immunodeficiency due to chemotherapy and radiation administered is likely a possibility in leukemia arising following autologous stem cell transplantation with short latency period, but highly unlikely in this case given the long latency period of fourteen years in this case.

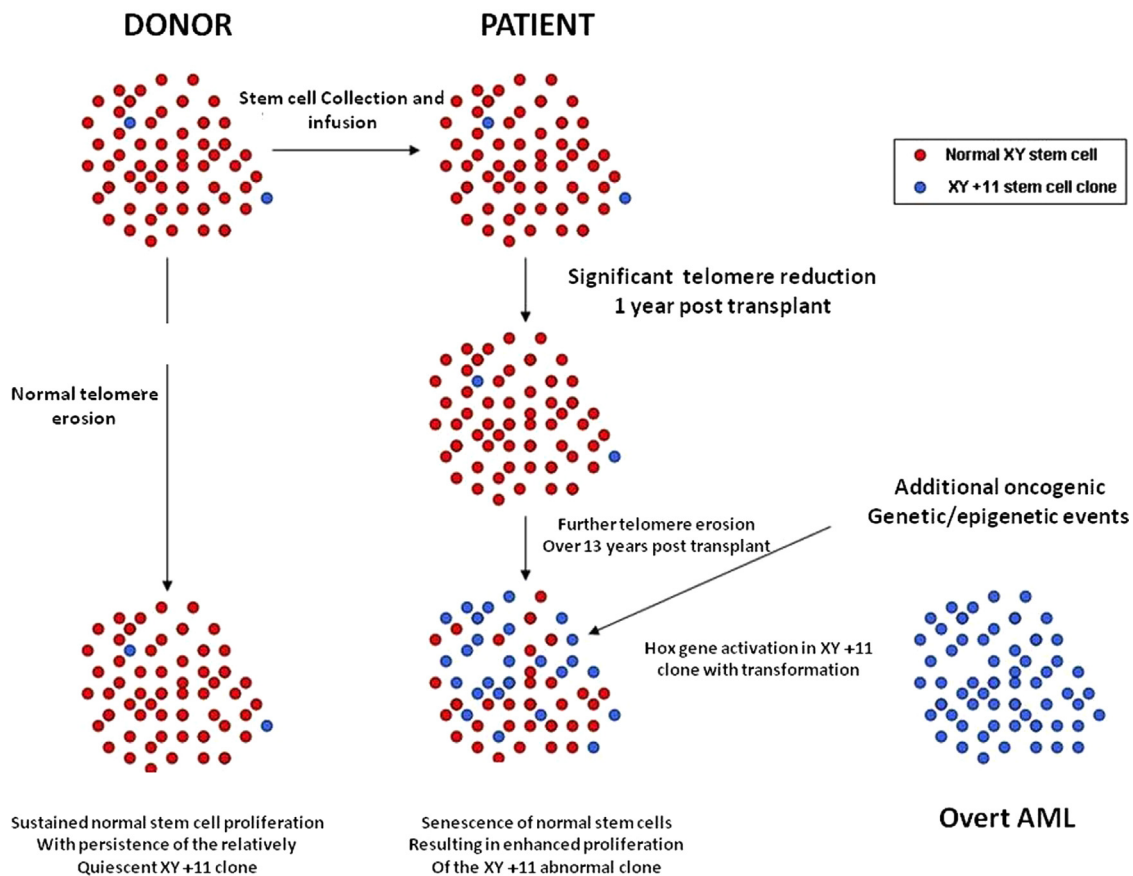
We suggest, alternatively, that premature senescence and or programmed cell death of the normal transplanted donor stem cells due to telomere erosion may have played a role (Fig. 2). The difference in telomere dynamics between normal donor cells and donor cells with trisomy 11 may contribute significantly to the selective proliferation and neoplastic transformation of the latter. In fact, *Notaro et al. (1997)* [3] previously found that telomere length of engrafted donor cells was significantly reduced when compared to donor cells, suggesting that telomere shortening may reduce the proliferative potential of the engrafted donor cells. In addition, it is also well recognized that telomere erosion also results in a significant genomic instability, the hall mark of malignant transformation [4]. It is furthermore known that following allogeneic stem cell transplantation, the reduction in telomere length of donor hematopoietic cells is equivalent to approximately 15 years, and in some instances 40–60 years, of aging [5,6]. Several studies suggest that the reduction in telomere length, which occurs predominantly during the first year following transplantation, is unlikely to significantly compromise bone marrow function. However, it is important to recognize that such data

is largely derived from a younger donor and recipient population (age < 40) [7]. It is therefore conceivable that in the present case, with an older donor (54 at the time of stem collection), this well recognized reduction in telomere length may have compounded the overall effect of this phenomenon. Therefore, normal stem cells from an older donor are placed under replicative stress, which in turn may reduce the proliferative capacity of these cells [3]. The resulting senescence of normal donor hematopoietic cells over the 14 years following transplantation in our patient may have set the stage for the expansion of cells with trisomy 11. The amplification of MLL protein in these, now dividing cells may have triggered a cascade of events leading to frank leukemia [8]. Several studies reviewed elsewhere have suggested that amplification of MLL gene may activate HOX genes which are known to play important role in leukemogenesis [8].

Lastly, it is equally important to mention that the microenvironment and genetic background of the host with a previous history of two independent malignancies may have further facilitated the selective proliferation of a clone with trisomy 11 [9,10], while normal cells suffered proliferative stress resulting in senescence or apoptosis.

We, therefore, propose that the sequence of genetic and epigenetic events leading to leukemogenesis of donor cells with trisomy 11 includes telomere shortening in normal donor derived hematopoietic stem cells due to excessive stress to reconstitute host hematopoietic compartment, results in selective proliferation of a clone with MLL amplification, which in turn activated genes such as HOX, known to be deregulated in MDS and AML [8].

Donor-derived leukemia holds promise as a method to study in vivo leukemogenesis, in both allogeneic and autologous transplants.



**Fig. 2.** A proposed mechanism whereby a pre-malignant donor clone containing the trisomy 11 cytogenetic abnormality transferred into the patient at the time of an allogeneic bone marrow transplantation evolved into a frankly malignant AML clone over 14 years following transplantation. In the recipient, rapid telomere erosion in normal donor stem cells following transplantation results over time (14 years) in selective growth advantage of the clone with trisomy 11 and subsequent transformation to a true malignant clone due to activation of HOX genes and possibly other genetic/epigenetic events not fully recognized, as additional cells and DNA sample were not available for molecular studies. In the donor, a lack of dramatic telomere shortening in normal stem cells explains the persistent but quiescent nature of the trisomy 11 clone.

This unusual case provides new insight into this process. It suggests that genetic abnormalities which ultimately lead to leukemia may be latent for long periods of time. Although uncommon, donor-derived leukemia incidence may not be exceptionally rare and perhaps is under-reported. Multi-institutional prospective studies should be considered in cases of leukemic relapse after stem cell transplantation to investigate the underlying genetic/epigenetic molecular mechanism (s) of donor leukemia to support or refute our hypothesis of leukemogenesis.

### Authorship

### Contributions

M.A.D. performed research, collected data and wrote paper, E.P. and C.V.H. produced data and analyzed results, R.J.B. and S.C.J. synthesized data and wrote paper.

### References

- [1] Reichard KK, Zhang QY, Sanchez L, Hozier J, Viswanatha D, Foucar K. Acute myeloid leukemia of donor origin after allogeneic bone marrow transplantation for precursor T-cell acute lymphoblastic leukemia: case report and review of the literature. *Am J Hematol* 2006;81:178–85.
- [2] Chaganti RSK. The significance of chromosome change to neoplastic development. In: German J, editor. *Chromosome mutation and neoplasia*. New York: Alan R. Liss Inc; 1983. p. 359–96.
- [3] Notaro R, Cimmino A, Tabarini D, Rotoli B, Luzzatto L. *In vivo* telomere dynamics of human hematopoietic stem cells. *Proc Natl Acad Sci USA* 1997;94:13782–5.
- [4] Calado RT, Young NS. Telomere maintenance and human bone marrow failure. *Blood* 2008;111:4446–55.
- [5] Lee J, Kook H, Chung I, et al. Telomere length changes in patients undergoing hematopoietic stem cell transplantation. *Bone Marrow Transplant*. 1999;24:411–5.
- [6] Shay JW. Accelerated telomere shortening in bone-marrow recipients. *Lancet* 1998;351:153–4.
- [7] Elwood N. Telomere biology of human hematopoietic stem cells. *Cancer Control* 2004;11:77–85.
- [8] Look AT. Molecular pathogenesis of MDS. *Hematology Am Soc Hematol Educ Program* 2005:156–60.
- [9] Olipitz W, Hopfinger G, Aguiar RC, et al. Defective DNA-mismatch repair: a potential mediator of leukemogenic susceptibility in therapy-related myelodysplasia and leukemia. *Genes Chromosom Cancer* 2002;34:243–8.
- [10] Smith MA, McCaffrey RP, Karp JE. The secondary leukemias: challenges and research directions. *J Natl Cancer Inst*. 1996;88:407–18.