



Renal Spindle Cell Tumor with Thrombus Extension into the Inferior Vena Cava and the Right Atrium Depicted by PET/CT Scan

Deya' Aldeen Sweedat¹ Nabeela Al-Hajaj¹ Jakub Khzouz² Akram Al-Ibraheem¹

¹ Department of Nuclear Medicine, King Hussein Cancer Center, Amman, Jordan

² Department of Histopathology, King Hussein Cancer Center, Amman, Jordan

Address for correspondence Akram Al-Ibraheem, MD, FEBNM, DCBNC, FANMB, Department of Nuclear Medicine and PET/CT, King Hussein Cancer Center, King Hussein Cancer Center, P.O. Box 1269 Al-Jubeiha, Amman 11941, Jordan
(e-mail: aibraheem@khcc.jo; akramalibrahim@gmail.com).

World J Nuclear Med 2022;21:59–61.

Abstract

Tumor thrombus (also called intravascular tumor extension) can be defined as tumor extending into vessel; typically a vein, it occurs in a lot of malignancies like hepatocellular carcinoma, Wilms tumor, and others.¹ Tumor thrombus has been reported to demonstrate increase in fluorine-18 fluorodeoxyglucose (FDG) uptake that would differentiate it from the benign bland thrombus which would not take up FDG on positron emission tomography/computed tomography (PET/CT) scan.¹ We present a case of spindle cell sarcoma of right kidney whose baseline contrast-enhanced CT revealed a mass replacing the right kidney and right renal vein associated with thrombus in the inferior vena cava (IVC). ¹⁸F-FDG PET/CT imaging was done that revealed an FDG-avid hypermetabolic malignant right renal mass with hypermetabolic IVC thrombus extending to the right atrium.

Keywords

- tumor thrombus
- PET/CT
- spindle cell sarcoma
- ¹⁸F-FDG

Introduction

Spindle cell sarcomas are one of the rare tumors that can affect the kidneys. The presence of tumor thrombus changes staging, prognosis, and surgical approach, for example, renal vein ligation in case of limited tumor to the renal vein and its tributaries, or a potential thoracotomy and open heart surgery in case of tumor extension above the diaphragm.¹ Furthermore, removal of the thrombus could provide a better quality of life, regardless of therapy outcome (cure/palliation).² We present a case of fluorine-18 fluorodeoxyglucose (FDG)-avid spindle cell sarcoma of the right kidney with involvement of the right renal vein and tumor thrombus extending through the inferior vena cava (IVC).

Case Study

A 56-year-old female patient with a history of hypertension, cardiomyopathy, and chronic atrial fibrillation presented with right flank pain, loss of appetite, and impaired kidney function.

Computerized tomography (CT) abdomen was performed and showed a huge mass replacing the right kidney and right renal vein. The mass is compressing the infrarenal IVC (►Fig. 1A) and associated huge IVC thrombus (►Fig. 1B). Biopsy was taken from the right kidney that showed high-grade spindle cell tumor (►Fig. 2A, B).

Positron emission tomography/computed tomography (PET/CT) scan was performed for staging to assess tumor extension and to improve/exclude tumor thrombus. The

DOI <https://doi.org/10.1055/s-0042-1744199>.
ISSN 1450-1147.

© 2022. World Association of Radiopharmaceutical and Molecular Therapy (WARMTH). All rights reserved.

This is an open access article published by Thieme under the terms of the Creative Commons Attribution-NonDerivative-NonCommercial-License, permitting copying and reproduction so long as the original work is given appropriate credit. Contents may not be used for commercial purposes, or adapted, remixed, transformed or built upon. (<https://creativecommons.org/licenses/by-nc-nd/4.0/>)

Thieme Medical and Scientific Publishers Pvt. Ltd., A-12, 2nd Floor, Sector 2, Noida-201301 UP, India

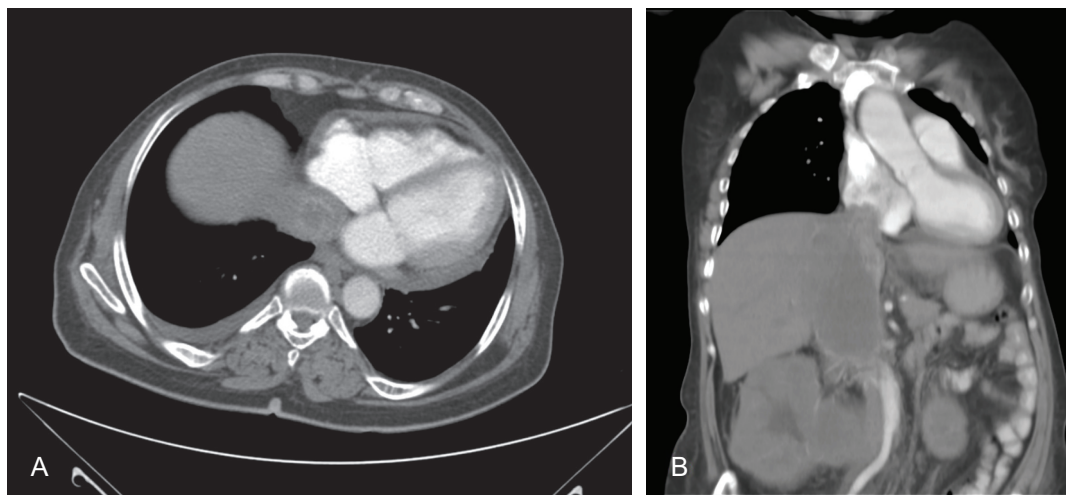


Fig. 1 Contrast-enhanced computed tomography (CT) scan axial view at the level of lower chest/upper abdomen arterial phase (A) showing dilated inferior vena cava at the level of inferior cavoatrial junction along with intraluminal heterogeneous mainly hyperattenuating rounded structure in keeping with thrombus; coronal view chest and abdomen CT scan venous phase (B) showing dilated right atrium with evidence of intra-atrial filling defect.

scan revealed a huge right renal mass showing intense abnormal heterogeneous FDG metabolic activity with areas of central necrosis; it measures approximately 15.5×11.6 cm with maximum standardized uptake value of 11.4. This mass was replacing the right kidney and right renal vein, indenting the infrarenal IVC and extending upward through the IVC (**Fig. 3A**).

The scan also showed a tumor extension to the IVC and right atrium (**Fig. 3B, C**). The patient's bleeding profile was within normal limits. He was on antiplatelet and anticoagulant medications.

Discussion

Tumor thrombus is a rare complication of many solid tumors.³ A high FDG accumulation in a thrombus generally indicates a malignant origin. The intense and extensive FDG uptake appeared to support the extensive growth of the tumor thrombus itself rather than bland thrombus.^{4,5} Furthermore, tumor thrombus follows the metabolic signature of spindle cell sarcoma in which higher grades with increased cellularity and increased mitosis show high FDG uptake, and cells with fibroblastic differentiation show decreased FDG

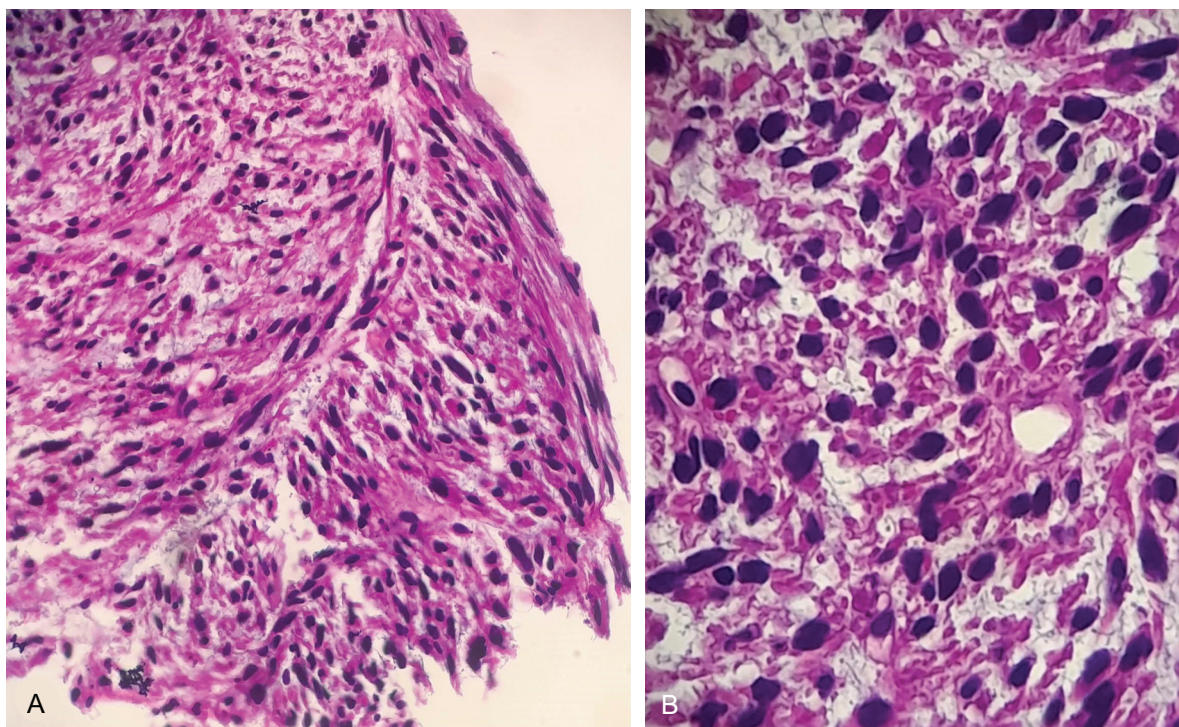


Fig. 2 Trucut biopsy showing spindle cell tumor. Tumor cells are showing pleomorphic hyperchromatic nuclei and increased mitotic activity. Cytoplasm is abundant and eosinophilic (A, B) (20 \times and 40 \times hematoxylin and eosin).

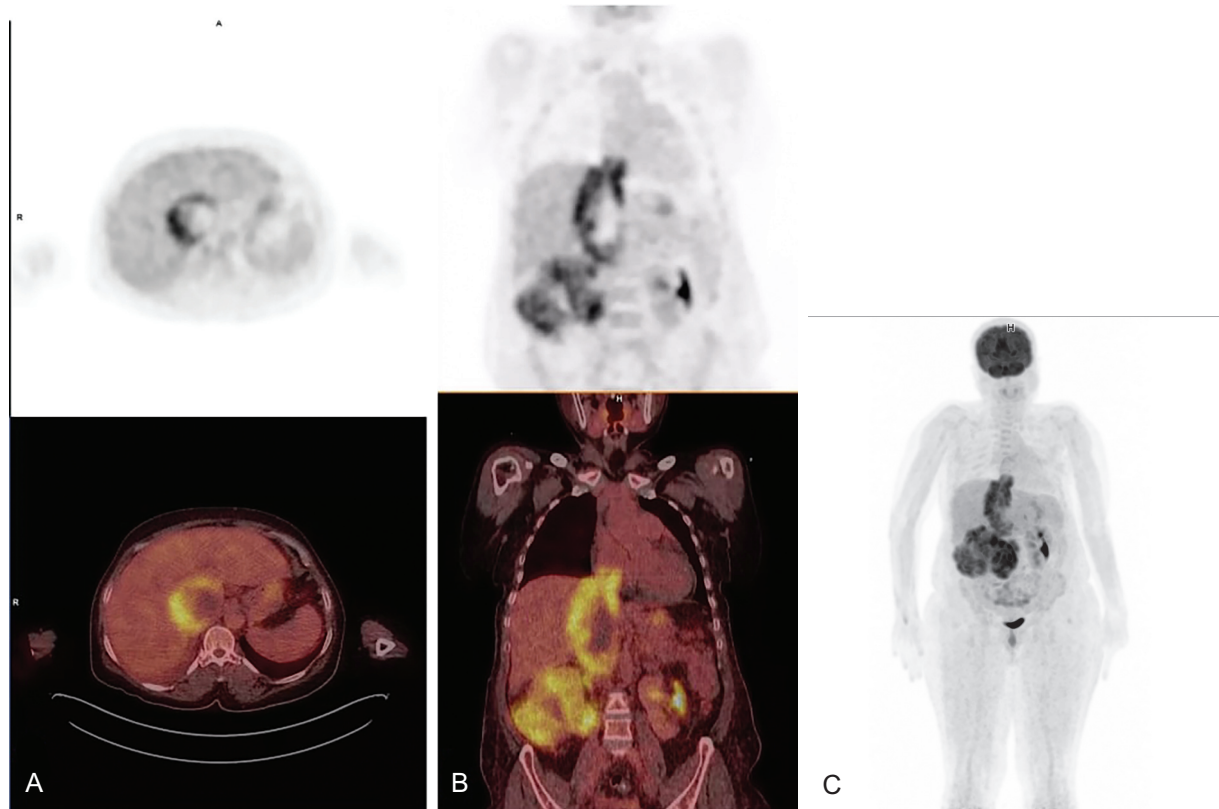


Fig. 3 Positron emission tomography/computed tomography (PET/CT) axial view (A) demonstrates hypermetabolic circumferential wall thickening within the inferior vena cava (IVC). PET and PET/CT coronal view (B) images demonstrate heterogeneous intensely hypermetabolic huge mass with areas of central necrosis replacing the right kidney invading the IVC and reaching the right atrium. Maximum intensity projection (C) also shows the extension of tumor thrombus from the right kidney to the right atrium.

uptake according to Bek et al.⁶ Accurate diagnostic imaging should be performed preoperatively to help dictate excellent surgical approach and successful treatment.⁷ The aforementioned description supports the findings of intense FDG uptake, huge extension to the IVC, and a pathology of high-grade spindle cell sarcoma reported in our case, indicating tumor thrombus rather than other differentials.

In patients with renal spindle cell sarcoma, PET/CT scan may have added value in staging and ruling out distant metastases. In addition, both anatomic localization and pathologic behavior of any associated IVC thrombi can be determined with a sensitivity that can be equal to or more than other imaging modalities.⁸ To the best of our knowledge, this is the first case report of renal spindle cell sarcomas that shows malignant tumor thrombus which illustrates the significant value of PET/CT in distinguishing tumor thrombi and bland thrombi particularly when there is extended and intense FDG uptake.

Conflict of Interest

None.

Acknowledgment

We would like to acknowledge all the technical and supportive staff of Nuclear Medicine Department of King Hussein Cancer Center.

References

- 1 Abdelfattah A, El Wazir M, Ali YZ, Naser J, Wiley BM. Renal cell carcinoma with thrombus extension into the inferior vena cava and the right atrium: a case report. *CASE (Phila)* 2020;4(04): 274–277
- 2 Quencer KB, Friedman T, Sheth R, Oklu R. Tumor thrombus: incidence, imaging, prognosis and treatment. *Cardiovasc Diagn Ther* 2017;7(Suppl 3):S165–S177
- 3 Lai P, Bomanji JB, Mahmood S, et al. Detection of tumour thrombus by ¹⁸F-FDG-PET/CT imaging. *Eur J Cancer Prev* 2007;16(01): 90–94
- 4 Sharma P, Kumar R, Jeph S, et al. ¹⁸F-FDG PET-CT in the diagnosis of tumor thrombus: can it be differentiated from benign thrombus? *Nucl Med Commun* 2011;32(09):782–788
- 5 Rydberg JN, Sudakoff GS, Hellman RS, See WA. Positron emission tomography-computed tomography imaging characteristics of an inferior vena cava tumor thrombus with magnetic resonance imaging correlation. *J Comput Assist Tomogr* 2004;28(04): 517–519
- 6 Bek CS, Kim HW, Won KS, Song BI. Spindle cell sarcoma of the iliac vein on 18 F-FDG PET/CT. *Clin Nucl Med* 2017;42(04):293–294
- 7 Figueroa AJ, Stein JP, Lieskovsky G, Skinner DG. Adrenal cortical carcinoma associated with venous tumour thrombus extension. *Br J Urol* 1997;80(03):397–400
- 8 Nouh MA, Inui M, Kakehi Y. Renal cell carcinoma with IVC thrombi; current concepts and future perspectives. *Clin Med Oncol* 2008;2:247–256