



# Outcome after treatment for sebaceous carcinoma: A multicenter study

Eva Huis In 't Veld MD<sup>1</sup>  | Ronald Keizer MD<sup>2</sup> | Nicoline Post MD<sup>3</sup> |  
 Jeroen Versteeg MD<sup>2</sup> | Robert Verdijk MD, PhD<sup>4,5</sup> | Nicole Naus MD, PhD<sup>6</sup> |  
 Germaine Relyveld MD, PhD<sup>3</sup> | Marianne Crijns MD, PhD<sup>3</sup> |  
 Myles Smith MD, PhD<sup>7</sup> | Dirk Grünhagen MD, PhD<sup>8</sup> | Marlies Wakkee MD, PhD<sup>9</sup> |  
 Dion Paridaens MD, PhD<sup>2,6</sup> | Ioannis Zavrakidis MD, PhD<sup>10</sup> |  
 Antien Mooyaart MD, PhD<sup>4,11</sup> | Alexander van Akkooi MD, PhD<sup>1</sup> |  
 Dirk Strauss MD, PhD<sup>7</sup> | Cornelis Verhoef MD, PhD<sup>8</sup> |  
 Michel Wouters MD, PhD<sup>1</sup>  | Andrew Hayes MD, PhD<sup>7</sup> | Winan van Houdt MD, PhD<sup>1</sup>

<sup>1</sup>Department of Surgical Oncology, Netherlands Cancer Institute, Amsterdam, The Netherlands

<sup>2</sup>Department of Ocular Oncology, The Rotterdam Eye Hospital, Rotterdam, The Netherlands

<sup>3</sup>Department of Dermatology, Netherlands Cancer Institute, Amsterdam, The Netherlands

<sup>4</sup>Department of Pathology, Section Ophthalmic Pathology, Erasmus Medical Centre, Rotterdam, The Netherlands

<sup>5</sup>Department of Pathology, Leiden University Medical Center, Leiden, The Netherlands

<sup>6</sup>Department of Ophthalmology, Erasmus Medical Centre, Rotterdam, The Netherlands

<sup>7</sup>Sarcoma and Skin Unit, Department of Academic Surgery, Royal Marsden NHS Trust, London, UK

<sup>8</sup>Department of Surgical Oncology, Erasmus Medical Centre, Rotterdam, The Netherlands

<sup>9</sup>Department of Dermatology, Erasmus Medical Centre, Rotterdam, The Netherlands

<sup>10</sup>Department of Epidemiology and Biostatistics, Netherlands Cancer Institute, Amsterdam, The Netherlands

<sup>11</sup>Department of Pathology, Erasmus Medical Centre, Rotterdam, The Netherlands

## Correspondence

Eva Huis In 't Veld, Department of Surgical Oncology, Netherlands Cancer Institute, Doctor Molewaterplein 40, 3015 GD Rotterdam, The Netherlands.  
 Email: [e.huisintveld@erasmusmc.nl](mailto:e.huisintveld@erasmusmc.nl)

## Abstract

**Background:** Sebaceous carcinoma (SC) is a rare malignant tumour whereby, comprehensive long-term data are scarce. This study aimed to assess the outcome of patients treated with resection for SC.

**Methods:** Patients treated at four tertiary centres were included. Cumulative incidence curves were calculated for recurrences.

**Results:** A total of 100 patients (57 males, 57%) were included with 103 SCs. The median age was 72 (range, 15–95) years with a median follow-up of 52 (interquartile range [IQR], 24–93) months. Most SCs were located (peri)ocular (49.5%). Of all SCs, 17 locally recurred (16.5%) with a median time to recurrence of 19 (IQR, 8–29) months. The cumulative incidence probability for recurrence was statistically higher for (peri)ocular tumours ( $p = 0.005$ ), and for positive resection margins ( $p = 0.001$ ). Two patients presented with lymph node metastases and additional seven patients (8.7%) developed lymph node metastases during follow-up with a median time to metastases of 8 (IQR, 0.5–28) months. Three patients had concurrent in-transit metastases and one patient also developed liver and bone metastases during follow-up.

**Conclusion:** SC is a rare, yet locally aggressive tumour. Positive resection margins and (peri)ocular SCs are more frequently associated with local recurrence. SC infrequently presents with locoregional or distant metastases.

## KEYWORDS

rare cutaneous malignancy, sebaceous carcinoma, sebaceous gland, skin cancer

This is an open access article under the terms of the Creative Commons Attribution-NonCommercial-NoDerivs License, which permits use and distribution in any medium, provided the original work is properly cited, the use is non-commercial and no modifications or adaptations are made.

© 2022 The Authors. *Journal of Surgical Oncology* published by Wiley Periodicals LLC

## 1 | INTRODUCTION

Sebaceous carcinoma (SC) is a rare malignant tumour of the sebaceous glands and only accounts for 0.7% of all cutaneous malignancies. SC has an incidence of 2:1.000.000 compared to an incidence of 164:1.000.000 for basal cell carcinoma in 2009 in the Netherlands.<sup>1,2</sup> It can occur at any site of the body where the glands are present, but are mostly found in the (peri)ocular area. The golden standard for treatment is wide local excision with a reported local recurrence rate of 4%–28%.<sup>2–5</sup> No standardised resection margins are described. Radiotherapy as primary treatment has a higher recurrence rate and, therefore, this is only used in patients refusing excision.<sup>2</sup>

Since SC is mostly found in the periocular region, these lesions are often divided into (peri)ocular and extraocular SCs. To date, there are only (small) cases series and literature reviews analysing the outcome of this disease at all anatomical locations, all emphasising the scarcity of data, and the need for more studies.<sup>2,6</sup> The majority of these cases refer to (peri)ocular SC. Extraocular SC is associated with lower metastatic potential and consequently lower mortality in comparison to (peri)ocular SC. However, these conclusions are based on small case series and the results are contradicted by other case series.<sup>3,5,7</sup>

With an increased incidence of 3.31% annually in the US and only small cases series, or studies on (peri)ocular SC location, there is a need to better understand the prognosis and course of this disease.<sup>3</sup> Therefore, the aim of this study is to assess the rates of recurrence and metastases as well as survival and define prognostic factors for the outcome, for SC in all locations.

## 2 | MATERIALS AND METHODS

### 2.1 | Patients inclusion and data collection

A retrospective study of patients diagnosed with SC between 1990 and 2017 in four referral centres was performed. This study was approved by the Institutional review board.

The four referral centres included were the Royal Marsden Hospital, London, United Kingdom; Netherlands Cancer Institute, Amsterdam, The Netherlands; Erasmus MC, Rotterdam, The Netherlands; and The Rotterdam Eye Hospital, Rotterdam, The Netherlands.

Only those patients with confirmed SC by a pathologist of the referral center were included. Patient demographics and clinical characteristics were obtained from patient files. Radical resections were defined as clear pathological margins of >1 mm. The last clinical visit or telephone call was noted as the last follow-up date. Age was calculated from the date of diagnosis. Time to recurrence, metastases, and follow-up were calculated after the date of first treatment. The primary treatment was noted as the first treatment after pathological confirmation of SC. For the ocular SCs, some patients had a history of treatments going back multiple years, for chalazion, basal cell carcinoma, or squamous cell carcinoma, however without pathological confirmation of SC. Therefore, these treatments are not

taken into account in the analyses. Seven patients were excluded due to the lack of treatment records.

### 2.2 | Statistical analysis

IBM SPSS statistics 25 and R (R Core Team, 2019)<sup>8</sup> were used for the statistical analyses. Recurrence rates were calculated using the cumulative incidence curves (CICs) accounting for competing risks. Differences between CICs were calculated using Gray's test,<sup>9</sup> due to the small sample size multivariate analyses were not conducted. In addition, due to the small number of metastases, no statistical analysis on risk factors for metastases was conducted. Median survival was crudely derived using the Kaplan–Meier curve for descriptive purposes.

## 3 | RESULTS

A total of 100 patients were included with 103 SCs. Most patients were treated in the Rotterdam Eye Hospital ( $N = 39$ ), followed by the Erasmus MC ( $n = 30$ ), the Netherlands Cancer Institute ( $n = 18$ ), and the Royal Marsden Hospital ( $N = 16$ ). The median age was 72 years (range, 15–95) with a median follow-up of 52 months (interquartile range [IQR], 24–93). A total of 57 patients were male (57%) and most SCs were located in the periocular region (50.5%) followed by head and neck locations (32.0%). Seven patients had SCs located on the trunk (6.8%), seven on the extremities (6.8%), and two SCs were located in the genital region (1.9%).

Seven patients were proven to have Muir–Torre syndrome (7%), with a total of 9 SCs, almost all extraocular SCs ( $n = 8$ ) (Table 1). One patient aged 15 had a concurrent diagnosis of xeroderma pigmentosum. Two patients required long-term immunosuppressive drugs for kidney and heart transplantation. Three patients had a history of the hematological disease, and 17 patients had a history of other skin cancers (16%), of which three patients had a history of melanoma and one patient had a Merkel cell carcinoma.

Unfortunately, data regarding the differentiation grade ( $n = 38$ ) and thickness of the SCs ( $n = 29$ ) were only available in a minority of the patients. Fourteen (of 38) patients had a well-differentiated SC (36.8%), 8/38 a moderately differentiated (21.1%), and 16/38 patients had a poorly differentiated SC (42.1%). The median thickness was 5 mm (range, 1.2–11). The extraocular tumours were significantly larger than the ocular tumours ( $p < 0.001$ ) and showed a trend towards more male prevalence ( $p = 0.07$ ) (Table 1).

### 3.1 | Primary treatment

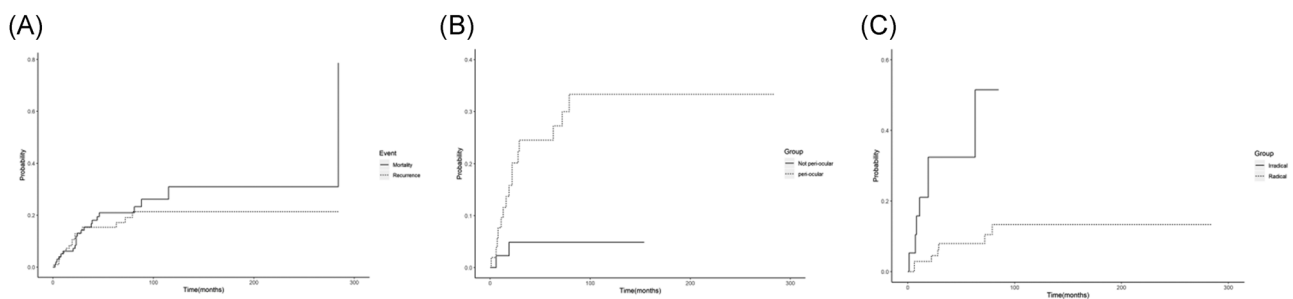
All patients underwent surgical resection of their SC: four patients with ocular SCs were first treated with mitomycin C eye drops for the conjunctival in situ component. Eight patients underwent immediate orbital exenteration of the eye. None of the extraocular

**TABLE 1** Patients, tumour, and treatment characteristics

	Total	Tumour location <sup>a</sup>		p	Metastases	
		Periocular	Nonocular		Yes	No
Gender, no (%)				0.07C		
Male	60 (58)	25 (48)	33 (67)		5 (56)	55 (59)
Female	43 (42)	27 (52)	16 (33)		4 (44)	39 (41)
Age in years at diagnosis, median (range)	72 (15–95)	74 (45–93)	72 (15–95)	0.332T	67 (62–91)	73 (15–95)
Size in mm, median (range)	14 (1–58)	9 (1–31)	22 (1–58)	<0.001T	25 (10–50)	13 (1–58)
Resection margin, no (%)				0.279C		
Radical	71 (72)	34 (67)	37 (77)		4 (44)	69 (73)
Irradical	20 (20)	13 (25)	7 (15)		4 (44)	16 (17)
Unknown	8 (8)	4 (8)	4 (8)		1 (11)	9 (10)
Recurrence?				<0.001F		
Yes	17 (16)	15 (29)	2 (4)		4 (44)	13 (14)
No	86 (84)	37 (71)	47 (96)		5 (56)	81 (86)
Differentiation grade				0.635F		
Well	14 (13)	6 (11)	8 (16)		0 (0)	14 (15)
Moderate	8 (8)	5 (9)	3 (6)		1 (11)	7 (7)
Poorly	16 (16)	10 (19)	6 (14)		2 (22)	14 (15)
Unknown	66 (63)	32 (60)	32 (64)		6 (67)	59 (63)
Muir–Torre				0.014F		
Yes	9 (9)	1 (2)	8 (14)		0 (0)	9 (10)
No	92 (91)	41 (98)	51 (86)		9 (100)	85 (90)

Abbreviations: C,  $\chi^2$  test; F, Fisher exact test; T, independent sample T-test.

<sup>a</sup>For two patients, the tumour location was unknown.

**FIGURE 1** Cumulative incidence curves

SCs were preoperatively treated. A total of 19.4% of the excisional specimens had positive microscopic margins (R1 resections) ( $n = 20$ ). Four patients with incompletely excised SCs received postoperative radiotherapy, and eight patients were postoperatively treated with mitomycin C eye drops to treat the remaining conjunctival in situ growth. Five patients had pathological margins less than 1 mm and were defined as R1 resections but did not receive postoperative treatment.

### 3.2 | Recurrence

Of all SCs, 17 locally recurred (16.5%): Half of these patients had a previous R1 resection. The median time to recurrence was 19 months (IQR, 8–29). The cumulative incidence probability for recurrence was significantly higher for (peri)ocular tumours compared to extraocular tumours ( $p = 0.005$ ), and for positive resection margins compared to clear resection margins ( $p = 0.001$ ) (Figure 1). The cumulative

incidence probability for recurrence was not influenced by the size of the primary tumour ( $p=0.57$ ). Interestingly, none of the immunosuppressed patients or patients with Muir-Torre developed a recurrence.

Fifteen patients were treated surgically of which seven patients with (peri)ocular SC underwent an orbital exenteration. Lokal chemotherapy for the recurrent disease was used in three patients for ocular SC: mitomycin C eye drops ( $n=2$ ) and interferon eye drops ( $n=1$ ). Postoperative radiotherapy for recurrence was used in two patients. Two patients did not want any further treatment for their recurrent disease, due to age and comorbidities. The 5- and 10-year cumulative incidence for recurrence was 15.3% and 21.3%, respectively.

### 3.3 | Metastases

Nine patients (8.7%) developed regional and/or distant metastasis during follow-up with a median age of 69 years (range, 53–93) and a median time to metastasis of 8 months (IQR, 0.5–28) (Table 2). Two patients had metastases at presentation and additional seven patients developed metastases during follow-up. Five of these patients had ocular SC and four patients had extraocular SC, all located in the head and neck region. All patients had regional lymph node metastases with three patients also having in-transit metastases. One of these three patients developed liver and bone metastases during follow-up 2 months after the primary treatment. None of the patients underwent sentinel lymph node biopsy. None of the well-differentiated tumours, or tumours <10 mm metastasised. In addition, none of the immunosuppressed patients or patients with Muir-Torre developed metastases.

Five patients also had local recurrent disease (56%), which is higher than the recurrence rate of 17% for all SCs.

Most of the patients with lymph node metastases were treated with lymph node dissections ( $n=8$ ), followed by postoperative radiotherapy in seven patients (Table 2). The patient with liver and bone metastases was treated with the best supportive care. Six of the patients with metastases died during follow-up, of which only two patients died of disease. The median time from onset of metastases to death was 11 months (IQR, 2–73).

## 4 | DISCUSSION

This multicentre study of 103 SCs described the outcome after treatment for SC. Risk factors for local recurrence were positive resection margins and (peri)ocular tumour location. A total of nine patients developed metastases, all with tumour >1 cm.

All primary SCs were treated with excision which is in line with the published literature defining surgery as the golden standard wherein a surgical margin of at least 5 mm is advised for the ocular SCs.<sup>10–12</sup> SC is thought to occasionally display skip areas histologically, and because the Mohs technique relies on contiguous growth,

TABLE 2 Characteristics of patients with metastases

Age	Location	Sex	Size in mm	Resection margin	Differentiation grade	Age at metastases	Recurrence	Time to metastases	Location metastases	Treatment metastases	Muir-Torre	Status	Time from metastases to death or end of follow-up
62	Eyelid	F		R0		53	Yes	24	Lymph nodes	Surgery + PORT	No	DND	131
65	Eyelid	M			Poorly	69	Yes	45	Lymph nodes	Surgery + PORT	No	DND	14
66	Forehead	M	25	R0	Moderate	67	Yes	8	Lymph nodes, in-transit	Surgery + PORT	No	Alive	100
84	Neck	F	41	R0		86	No	28	Lymph nodes	Surgery + PORT	No	DOD <sup>a</sup>	2
70	Eyelid	M	10	R1	Poorly	70	No	1	Lymph nodes, in-transit, liver, bone	Best supportive care	No	DOD	2
62	Orbital	M	18	R1		64	No	28	Lymph nodes	Surgery + PORT	No	DND	11
67	Eyelid	F	50	R1	Moderate	68	No	0	Lymph nodes, in-transit	Surgery + PORT	No	Alive	47
91	Eyelid	M	15	R0		91	Yes	6	Lymph nodes	Surgery	No	DND	6
91	Retroauricular	F	36	R1		91	No	0	Lymph nodes, parotid	Surgery + PORT	No	DND	24

Abbreviations: DND, death not related to disease; DOD, death of disease; F, female; M, male; PORT, postoperative radiotherapy.

<sup>a</sup>This patient died of rapid progressive locoregional relapse, no therapeutic options were available and the patient went home with the best supportive care.

theoretically, wide excision with 5- to 6-mm margins in all cases might provide a higher cure rate.<sup>13</sup> However, wide surgical margins conflict with the aim to preserve a functional eye. At present, no guidelines or recommendations for the width of the surgical margin for extraocular SC are available.<sup>10–12</sup>

Our results support higher local recurrence rates after positive resection margins and for (peri)ocular SCs. All published literature on risk factors for recurrences is based on ocular SCs. Haber et al.<sup>14</sup> found a recurrence rate of 16.6% for extraocular SC without analysing risk factors for recurrence. In the ocular region, a higher tumour stage, intraepithelial neoplasia, and an initial (benign) misdiagnosis are described as risk factors for recurrences.<sup>15,16</sup>

This study observed a total metastasis rate of 8.7%, all involving the regional lymph nodes. The metastasis rate in most recent literature varies from 2.4% to 12%.<sup>3,5,6</sup> Tryggvason et al.<sup>7</sup> found a higher metastatic rate (regional or distant) in ocular SCs (4.4%) compared to extraocular sites (1.4%) only focusing on head and neck locations. In contrast, two publications including all SCs, based on the SEER database, suggest a higher prevalence of metastases in ocular SC, but a better overall survival for ocular SC.<sup>3,5</sup> Other studies showed that metastasis rates are associated with poor differentiation, larger tumour size, and increased tumour depth.<sup>7,17,18</sup> In this study, none of the well-differentiated tumours metastasised, although the differentiation state of many patients was unknown. Furthermore, not a single SC <10 mm in size metastasised, which is in line with the study by Lam et al.<sup>11</sup> who also did not find any metastases in tumours <10 mm in the ocular region.

In literature to date, only 30 cases of metastatic extraocular SC have been described. The most common site of metastasis including all locations were lymph nodes only (40%), lymph nodes and visceral organ (20%), visceral organs only (16%), and local spread (12%).<sup>10,19,20</sup> In this series, the one patient with bone and liver metastases was treated with the best supportive care, all other lymph node metastases were treated with lymph node dissection. Due to the lack of literature on metastatic SC, optimal treatment has not been firmly established. Literature on lymph node involvement for SC recommends adjuvant radiotherapy after lymph node dissection.<sup>6,21</sup> Evidence for the treatment with systemic chemotherapy or chemoradiation is confined to case reports whereby the treatment regimens are based on other types of head and neck cancers and consist of 5-fluorouracil or cisplatin-based chemotherapy.<sup>2,22</sup> On the basis of the assumption that cases associated with Muir-Torre and microsatellite instability are likely to respond to immunotherapy. Domingo-Misbay et al.<sup>23</sup> published a case report of pembrolizumab in metastatic SC with a durable ongoing response. In addition, Kodali et al.<sup>24</sup> also report a case with the inoperable recurrent disease with lymph node involvement, treated with carboplatin with pembrolizumab showing complete response with 15 months follow-up. As sporadic SC also have recurrent acquired somatic DNA mismatch repair (MMR) gene mutations, immunotherapy may also hold promise for these patients. Loss of function of MMR genes can easily be examined in individual cases by immunohistochemical methods.

For the follow-up of SC, no standard guidelines are available. One recent guideline recommends follow-up every 6 months for the

first 3 years and thereafter yearly consultations.<sup>25</sup> In our study, no patients had lung metastases and in the literature on extraocular SC only five patients developed lung metastases, making routine chest imaging redundant.<sup>10,19,20</sup> In this study, the median time to development of metastatic disease was 8 months, with the development of metastases documented up to 45 months after the primary SC. In literature metastases, up to 11 years after primary SC are described.<sup>6</sup> Therefore long-term clinical follow-up seems indicated.

A baseline ultrasound of the locoregional lymph nodes could be considered in poorly differentiated tumours, tumours >10 mm, or recurrent disease.

In this study, seven patients with SC had Muir-Torre syndrome, of which most (eight of nine) SCs were extraocularly located. Occasionally patients with Muir-Torre have developed (peri)ocular SC,<sup>26</sup> but Muir-Torre is more associated with extraocular SC.<sup>10</sup> Muir-Torre is a variant of the Lynch syndrome, causing patients to develop different malignancies and the presence of at least one sebaceous neoplasm or keratoacanthoma.<sup>27</sup> Adan et al.<sup>27</sup> found a 12-fold increased risk of developing squamous cell carcinoma and SC in patients with Lynch syndrome and therefore advise a consultation with a dermatologist as soon as a germline mutation is noted. Further dermatological follow-up should be recommended as soon as a malignant skin tumour is detected.<sup>27</sup> Patients with SC, especially in the extraocular region with or without visceral malignancies should be suspected of Muir-Torre syndrome. A relatively simple immunohistochemical test can be used for initial screening in such cases.<sup>28</sup> An article by North et al.<sup>29</sup> illustrates that SC can arise from different mutational mechanisms, whereby the UV damaged group has more poorly differentiated SCs in comparison to the Muir-Torre group.

Due to the retrospective nature of this study, caution should be taken in interpreting these results. As with any retrospective study, the investigator depends on the availability and accuracy of the medical record. This study includes patients referred to tertiary hospitals including an eye hospital which can cause a bias in the prevalence per tumour location. However, when compared to the literature, (peri)ocular tumour location is also described as the most prevalent anatomic region for SC. Only including tertiary centres in the analysis could potentially bias your results. Given that most rare cancer will be referred to tertiary centres, it is plausible that this bias is less significant for SC. Although this is a large series in the field, caution should also be exercised regarding the conclusions drawn, due to the relatively small patient population in this study. On the other hand, this is one of the first and largest studies describing the natural history and metastatic pattern of SC and risk factors for recurrence.

## 5 | CONCLUSION

Altogether, SC is a very rare, yet locally aggressive tumour in the elderly patient population. Patients with positive resection margins and (peri)ocular tumour location are more frequently associated with a local recurrence. Patients with SC infrequently present with locoregional or distant metastases, resulting in a good overall survival.

## CONFLICT OF INTERESTS

The authors declare that there are no conflict of interests.

## ETHICS STATEMENT

The study was performed in accordance with the Declaration of Helsinki.

## DATA AVAILABILITY STATEMENT

None of the data were made publically available.

## ORCID

Eva Huis In 't Veld  <http://orcid.org/0000-0002-5390-3719>

Michel Wouters  <http://orcid.org/0000-0001-6173-0662>

## REFERENCES

- Flohil SC, Seubring I, van Rossum MM, Coebergh JW, de Vries E, Nijsten T. Trends in basal cell carcinoma incidence rates: a 37-year Dutch observational study. *J Invest Dermatol*. 2013;133(4):913-918.
- Knackstedt T, Samie FH. Sebaceous carcinoma: a review of the scientific literature. *Curr Treat Options Oncol*. 2017;18(8):47.
- Tripathi R, Chen Z, Li L, Bordeaux JS. Incidence and survival of sebaceous carcinoma in the United States. *J Am Acad Dermatol*. 2016;75(6):1210-1215.
- Tai P, Stern RS, Robinson JK, eds. Sebaceous carcinoma, UpToDate; 2018.
- Dasgupta T, Wilson LD, Yu JB. A retrospective review of 1349 cases of sebaceous carcinoma. *Cancer*. 2009;115(1):158-165.
- Kyllo RL, Brady KL, Hurst EA. Sebaceous carcinoma: review of the literature. *Dermatol Surg*. 2015;41(1):1-15.
- Tryggvason G, Bayon R, Pagedar NA. Epidemiology of sebaceous carcinoma of the head and neck: implications for lymph node management. *Head Neck*. 2012;34(12):1765-1768.
- R Core Team. *R: a language and environment for statistical computing*. R Foundation for Statistical Computing, Vienna, Austria; 2019.
- Gray RJ. A class of K-sample tests for comparing the cumulative incidence of a competing risk. *Annals Stat*. 1988;16:1141-1154.
- Chang AY, Miller CJ, Elenitsas R, Newman JG, Sobanko JF. Management considerations in extraocular sebaceous carcinoma. *Dermatol Surg*. 2016;42(Suppl 1):S57-S65.
- Lam SC, Li EYM, Yuen HKL. 14-year case series of eyelid sebaceous gland carcinoma in Chinese patients and review of management. *Br J Ophthalmol*. 2018;102(12):1723-1727.
- Lam TC, Hsieh F, Boyages J. The effects of postmastectomy adjuvant radiotherapy on immediate two-stage prosthetic breast reconstruction: a systematic review. *Plast Reconstr Surg*. 2013;132(3):511-518.
- Spencer JM, Nossa R, Tse DT, Sequeira M. Sebaceous carcinoma of the eyelid treated with Mohs micrographic surgery. *J Am Acad Dermatol*. 2001;44(6):1004-1009.
- Haber R, Battistella M, Pages C, Bagot M, Lebbe C, Basset-Seguín N. Sebaceous carcinomas of the skin: 24 cases and a literature review. *Acta Derm-Venereol*. 2017;97(8):959-961.
- Takahashi Y, Takahashi E, Nakakura S, Kitaguchi Y, Mupas-Uy J, Kakizaki H. Risk factors for local recurrence or metastasis of eyelid sebaceous gland carcinoma after wide excision with paraffin section control. *Am J Ophthalmol*. 2016;171:67-74.
- Sa HS, Rubin ML, Xu S, et al. Prognostic factors for local recurrence, metastasis and survival for sebaceous carcinoma of the eyelid: observations in 100 patients. *Br J Ophthalmol*. 2019;103:980-984.
- Kaliki S, Ayyar A, Dave TV, Ali MJ, Mishra DK, Naik MN. Sebaceous gland carcinoma of the eyelid: clinicopathological features and outcome in Asian Indians. *Eye*. 2015;29(7):958-963.
- Cicinelli MV, Kaliki S. Ocular sebaceous gland carcinoma: an update of the literature. *Int Ophthalmol*. 2018;39:1187-1197.
- Sawyer AR, McGoldrick RB, Mackey S, Powell B, Pohl M. Should extraocular sebaceous carcinoma be investigated using sentinel node biopsy? *Dermatologic Surg*. 2009;35(4):704-708.
- Bolm I, Babaryka G, Moergel M, Al-Nawas B, Kammerer PW. Multifocal metastasizing extra-ocular facial sebaceous carcinoma as diagnostic challenge: case report and systematic review. *J Maxillofacial Oral Surg*. 2015;14(Suppl 1):331-337.
- Nelson BR, Hamlet KR, Gillard M, Railan D, Johnson TM. Sebaceous carcinoma. *J Am Acad Dermatol*. 1995;33(1):1-15.
- Kumar V, Xu Y. Unusual presentation of metastatic sebaceous carcinoma and its response to chemotherapy: is genotyping a right answer for guiding chemotherapy in rare tumours? *Current Oncol*. 2015;22(4):e316-e319.
- Domingo-Musibay E, Murugan P, Giubellino A, et al. Near complete response to Pembrolizumab in microsatellite-stable metastatic sebaceous carcinoma. *J Immunother Cancer*. 2018;6(1):58.
- Kodali S, Tipirneni E, Gibson PC, Cook D, Verschraegen C, Lane KA. Carboplatin and pembrolizumab chemoimmunotherapy achieves remission in recurrent, metastatic sebaceous carcinoma. *Ophthalmol Plast Reconstr Surg*. 2018;34(5):e149-e151.
- Owen JL, Kibbi N, Worley B, et al. Sebaceous carcinoma: evidence-based clinical practice guidelines. *Lancet Oncol*. 2019;20(12):e699-e714.
- Shields JA, Demirci H, Marr BP, Eagle RC Jr., Shields CL. Sebaceous carcinoma of the ocular region: a review. *Surv Ophthalmol*. 2005;50(2):103-122.
- Adan F, Crijns MB, Zandstra WSE, et al. Cumulative risk of skin tumours in patients with Lynch syndrome. *The Br J Dermatol*. 2018;179(2):522-523.
- John AM, Schwartz RA. Muir-Torre syndrome (MTS): an update and approach to diagnosis and management. *J Am Acad Dermatol*. 2016;74(3):558-566.
- North JP, Golovato J, Vaske CJ, et al. Cell of origin and mutation pattern define three clinically distinct classes of sebaceous carcinoma. *Nat Commun*. 2018;9(1):1894.

**How to cite this article:** In 't Veld EH, Keizer R, Post N, et al. Outcome after treatment for sebaceous carcinoma: a multicenter study. *J Surg Oncol*. 2022;125:730-735. doi:10.1002/jso.26774