

Treatment of Mooren's ulcer coexisting with a pterygium using an intrastromal lenticule obtained from small-incision lenticule extraction: case report and literature review

Journal of International Medical Research

49(6) 1–8

© The Author(s) 2021

Article reuse guidelines:

sagepub.com/journals-permissions

DOI: 10.1177/03000605211020246

journals.sagepub.com/home/imrNa He^{1,#} , Wei Song^{2,#} and Ying Gao¹

Abstract

The coexistence of Mooren's ulcer and a pterygium is an extremely rare ocular condition that has been infrequently reported in the literature to date. We herein present the first case of treatment of Mooren's ulcer coexisting with a pterygium using a lenticule obtained by myopic small-incision lenticule extraction (SMILE). A 61-year-old woman presented with a 3-month history of recurrent ocular pain and red eye caused by Mooren's ulcer coexisting with a pterygium. She received topical immunosuppressive and anti-infection treatments for almost 3 months. However, her ocular symptoms and signs did not substantially improve. Therefore, we performed lamellar keratoplasty with a corneal lenticule obtained by SMILE, followed by pterygium excision combined with conjunctival autografting. The patient recovered well with no complications or recurrence 1 year postoperatively. Our success suggests that combined surgery may be an effective management for coexistence of Mooren's ulcer and a pterygium if conservative treatments fail. A corneal lenticule obtained by SMILE can be used as the lamellar keratoplasty graft in such patients.

Keywords

Mooren's ulcer, pterygium, lamellar keratoplasty, small-incision lenticule extraction, case report, conjunctival autograft

Date received: 16 January 2021; accepted: 30 April 2021

[#]These authors contributed equally to this work.

Corresponding author:

Ying Gao, Department of Ophthalmology, Affiliated Jinhua Hospital, Zhejiang University School of Medicine, No. 365 Renmin Dong Road, Wucheng District, Jinhua, Zhejiang Province 321000, P.R. China.
Email: gaoy59@126.com

¹Department of Ophthalmology, Affiliated Jinhua Hospital, Zhejiang University School of Medicine, Jinhua, China

²Department of Ophthalmology, Jiaying Hospital of Traditional Chinese Medicine, Jiaying, China



Introduction

Mooren's ulcer is an idiopathic, painful, and aggressive type of peripheral ulcerative keratitis.¹ Reported risk factors include eye surgery, corneal trauma, and infections.^{2,3} The coexistence of Mooren's ulcer and a pterygium is an extremely rare clinical condition; only two single case reports have been published to date.^{4,5} We herein describe a 61-year-old Chinese woman who was diagnosed with Mooren's ulcer coexisting with a pterygium. Her crescent-shaped peripheral corneal ulcer developed along with the head of the pre-existent pterygium, which had been misdiagnosed as coexistence of bacterial keratitis by a local practitioner. After failure of conservative treatment, we used a corneal lenticule obtained by small-incision lenticule extraction (SMILE) as a corneal graft in lamellar keratoplasty (LKP) to maintain the corneal structure and prevent disease progression. This is the first reported case of the coexistence of Mooren's ulcer and a pterygium in mainland China to date. This disease is relatively rare and can easily be missed or misdiagnosed in the clinical setting.

Case report

Institutional review board approval was obtained from Affiliated Jinhua Hospital, Zhejiang University School of Medicine (ethics approval no. 2018-163-001). The research followed the tenets of the Declaration of Helsinki, and written informed consent was obtained from the patient. The reporting of this study conformed to the CARE guidelines.⁶

A 61-year-old Chinese woman was referred to the ophthalmic clinic of our hospital with a 3-month history of recurrent ocular pain, redness, eye irritation, and foreign body sensation in her right eye. She had been diagnosed with a pterygium in the right eye 1 year previously. Three

months before presentation, systemic and topical anti-infection treatments were initiated because her condition had been misdiagnosed as coexistence of bacterial keratitis by a local practitioner at that time. The best-corrected visual acuity of the right eye was 0.8 (0.1 in LogMAR scale). Slit-lamp examination revealed a pterygium in the nasal interpalpebral zone and a crescent-shaped peripheral corneal ulcer with an infiltrated and overhanging edge along the head of the pterygium (Figure 1(a)). Laboratory tests for systemic autoimmune diseases (including the erythrocyte sedimentation rate, antistreptolysin O titer, human leukocyte antigen B27 concentration, rheumatoid factor concentration, anti-nuclear antibody titer, anti-neutrophil cytoplasmic antibody titer, and anti-SSA and -SSB antibody titers) were all negative. Thus, she was diagnosed with Mooren's ulcer coexisting with a pterygium based on the morphological findings as well as her clinical symptoms and signs.

Topical administration of tobramycin/dexamethasone eye drops (TobraDex; Alcon Laboratories, Geneva, Switzerland) and levofloxacin eye drops (Cravit; Santen Pharmaceutical, Osaka, Japan) was initiated four times a day in her right eye immediately after the diagnosis was made. She was followed up every 3 weeks thereafter. After 3 months of immunosuppressive and anti-infection treatments, her ocular pain and redness were partly resolved, but she still complained of foreign body sensation. Additionally, the depth of the corneal stroma had not substantially increased. Therefore, with the patient's consent, we decided to perform pterygium excision and conjunctival autografting combined with LKP in her right eye. A SMILE-derived corneal lenticule was applied in LKP.

The surgery was performed after administration of subconjunctival anesthesia with 2% lidocaine. The pterygium was cut at the limbus with Wescott scissors; the head of

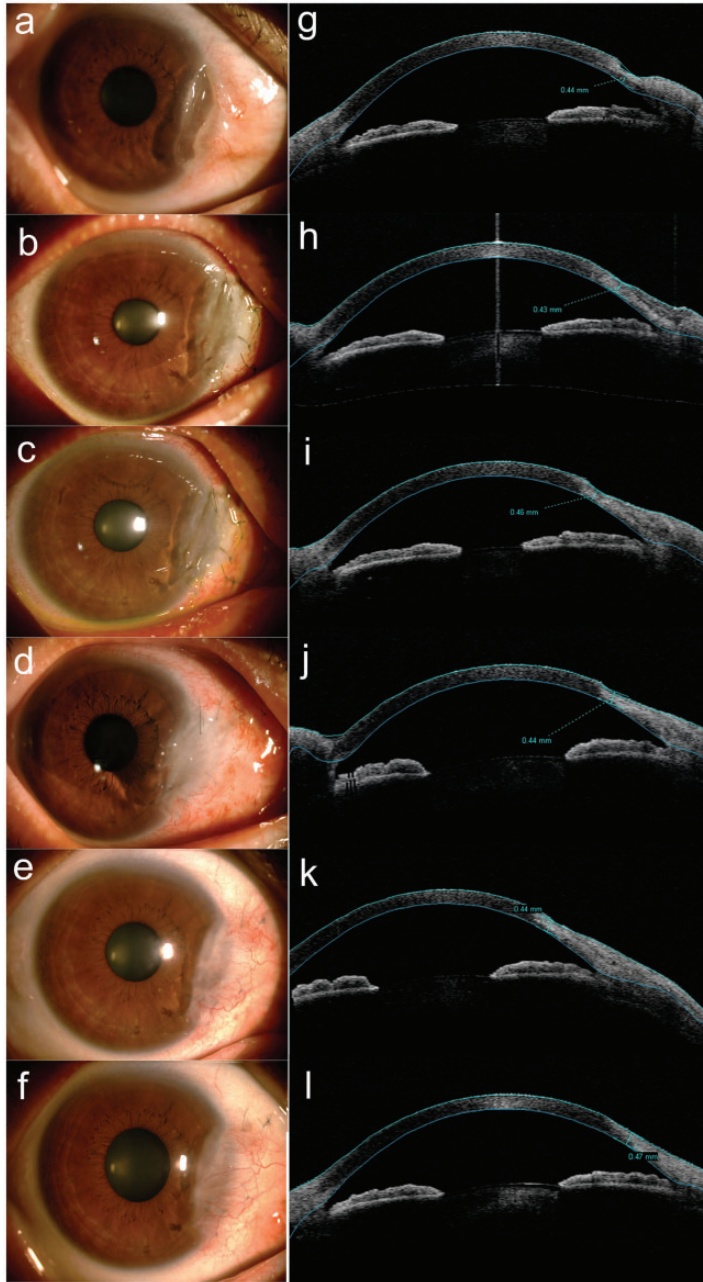


Figure 1. Preoperative and postoperative slit-lamp ocular images and anterior segment optical coherence tomography images at (a, g) baseline and (b, h) 1 day, (c, i) 1 week, (d, j) 1 month, (e, k) 3 months, and (f, l) 12 months postoperatively. The graft showed complete re-epithelialization and the beginning of neovascularization at 1 week postoperatively. Vascularity remained at 12 months postoperatively. The edema of the graft gradually vanished at 1 month, and the cornea exhibited a smooth anterior curve at 12 months as shown by anterior segment optical coherence tomography

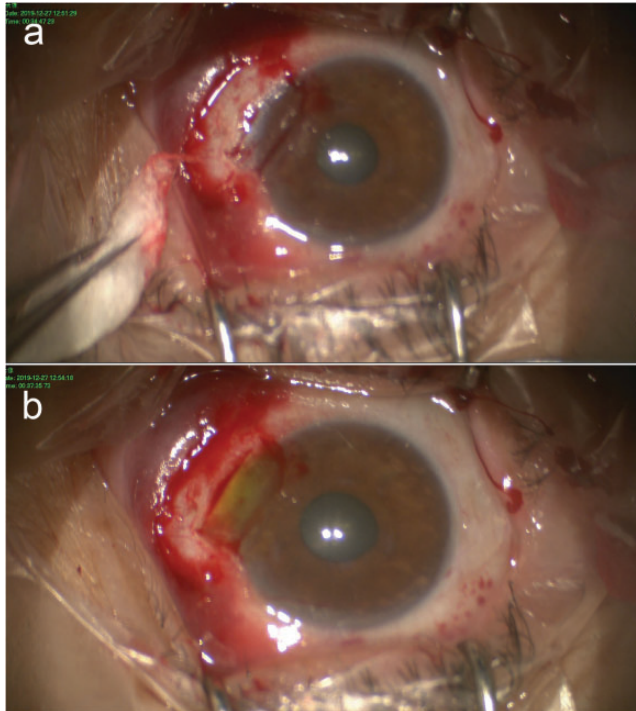


Figure 2. Main surgical steps. (a) Recipient bed after removal of the ulcer and episcleral tissue. (b) The lenticule was folded into two layers and fixed to the recipient corneal bed

the pterygium was detached from the surface of the cornea, followed by complete removal of the subconjunctival fibrous tissue. Redundant abnormal fibrous tissues were removed from the corneal surface with a No. 15 blade. The ulcer was extensively excised 0.25 mm from the lateral edge. The corneal infiltrate and episclera were also removed to establish the recipient bed (Figure 2(a)).

The lenticule (diameter of 6.5 mm and thickness of 130 μm) was selected from the eye bank in our eye center. It was obtained from a myopic patient with a refractive correction spherical equivalent of -7.50 diopters (D) during an elective SMILE procedure performed using the VisuMax femtosecond laser (Carl Zeiss Meditec AG, Jena, Germany). The patient was negative for hepatitis, human

immunodeficiency virus, syphilis, infection, malignancy, and corneal disease. The cryopreserved corneal lenticule was hydrated in a balanced salt solution for 10 minutes at room temperature. The lenticule was folded into two layers to create a thicker patch graft to match the stromal defect, which was more easily performed than superimposing two lenticules, and then trimmed to a crescent-shaped graft (Figure 2(b)). The graft was fixed to the recipient corneal bed with interrupted 10-0 nylon sutures. A free and thin conjunctival graft from the supratemporal conjunctiva was taken to cover the nasal conjunctival defect using interrupted 10-0 nylon sutures. Levofloxacin eye drops (Cravit; Santen Pharmaceutical) were applied four times a day postoperatively. Tobramycin/dexamethasone eye drops (TobraDex; Alcon Laboratories)

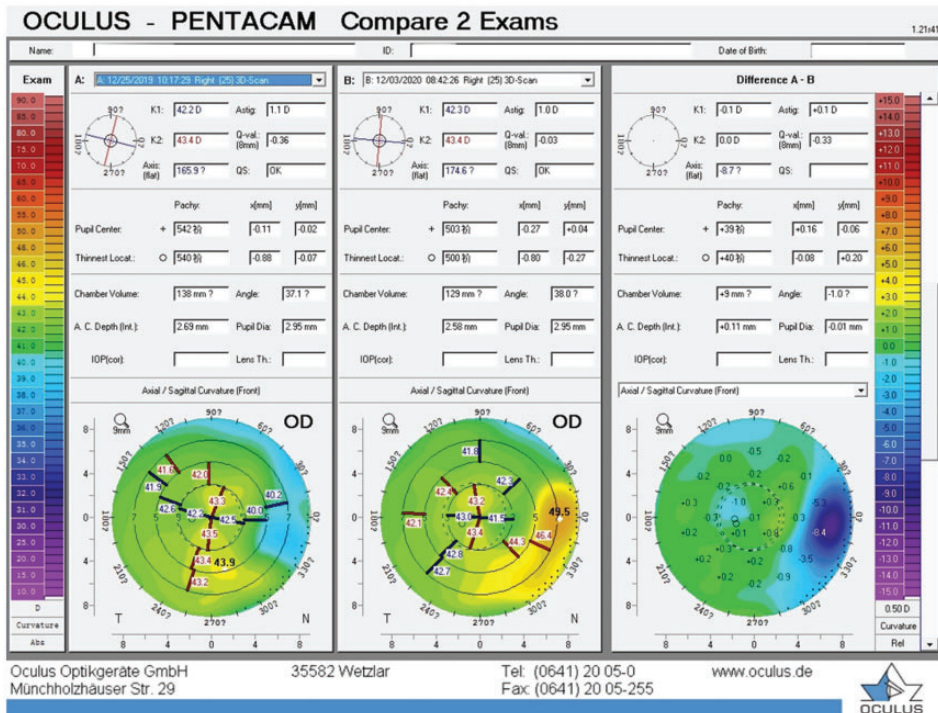


Figure 3. Differential maps of Scheimpflug-based corneal topography before and 1 year after surgery

were applied four times a day for 1 month followed by fluorometholone eye drops (Cravite; Santen Pharmaceutical) four times a day. The dosage of topical medication was gradually tapered and finally stopped 4 months after surgery.

Hematoxylin–eosin staining of the excised tissues showed hyperplasia of fibrovascular tissue under the epithelium. Therefore, the pathological findings confirmed that the conjunctival hyperplastic lesion was a pterygium. As shown in Figure 1, the graft was semitransparent and epithelized 1 week postoperatively (Figure 1(c)), became obscure 1 month postoperatively (Figure 1(d)), and finally became opaque almost 3 months postoperatively (Figure 1(f)), suggesting that the SMILE-derived lenticule gradually integrated with the recipient corneal stroma. The graft had completely re-epithelialized

with invasive neovascularization by 1 week postoperatively. The vascularity persisted for 1 year. Conjunctival congestion of the surgical area continued for 1 month after surgery (Figure 1(b)–(d)), recovered significantly 3 months postoperatively (Figure 1(e)), and had almost vanished 6 months postoperatively. Anterior segment optical coherence tomography was performed to evaluate the integration of the graft and the restoration of the peripheral cornea (Figure 1(g)–(l)). The edema of the graft gradually vanished 1 month postoperatively (Figure 1(j)), and the cornea exhibited a smooth anterior curve 1 year postoperatively (Figure 1(l)). The patient recovered well with no complications or recurrence, and the best-corrected visual acuity of the right eye remained 0.8 (0.1 in LogMAR scale) during the 1-year follow-up. Differential maps of

Scheimpflug-based corneal topography (Pentacam; Oculus Optikgeräte GmbH, Wetzlar, Germany) 1 year after surgery are shown in Figure 3. The front corneal central power increased by 0.1 D and 0.0 D at the flat and steep axis, respectively. The corneal astigmatism decreased by 0.1 D (from 1.1 D preoperatively to 1.0 D at 1 year postoperatively).

Discussion

Mooren's ulcer is an idiopathic, painful, and destructive type of peripheral ulcerative keratitis characterized by corneal stromal loss.¹ The incidence, clinical characteristics, and severity vary among different ethnicities and regions.⁷ This disease is rare worldwide, with a low incidence in the northern hemisphere and a relatively higher incidence in southern Africa and India.^{8,9} The incidence in China is about 0.03%,² and approximately one-third of cases developed bilaterally. The average age at onset is about 50 years.¹⁰ Mooren's ulcer is thought to be an organ-specific autoimmune disease because a cornea-associated antigen is found in patients' corneal stroma. However, the etiopathogenesis remains unclear.^{1,10} Previous research has indicated that the risk factors for Mooren's ulcer include corneal infection, trauma, and surgery.¹⁰ The ulcerations can develop unilaterally or bilaterally with a pseudo-ptyerygium or at the donor site after pterygium surgery.⁷

The coexistence of Mooren's ulcer and a pterygium is extremely rare; only two cases have been reported to date.^{4,5} The present case may be the third documented case of this condition worldwide. In our patient, Mooren's ulcer developed together with the pterygium, which had been misdiagnosed as coincident bacterial keratitis by a local practitioner.⁴

Therapies for Mooren's ulcer include conservative medications and surgeries.

The purpose of treatment is mainly to promote epithelialization, control inflammation, and prevent progression. Medical treatments include topical and systemic immunosuppressants. Systemic immunosuppression plays an important role in disease control, especially for recurrent cases. However, after rigorous immunosuppression, 11% to 36% of patients still progress to corneal perforation.⁷ In addition, with a recurrence rate of 25.5% to 44.2%, recurrence of Mooren's ulcer remains a clinical challenge.^{2,10} The risk factors for recurrence might include malignant ulcers, corneal infection, and corneal perforation.

The cause of the coexistence of Mooren's ulcer and a pterygium remains unclear, and the available literature does not provide much information regarding treatment. Touge et al.⁴ described a 51-year-old man with Mooren's ulcer occurring in the same area as a pre-existing pterygium; the patient had been referred to the authors because of corneal perforation. The corneal perforation healed after conjunctival excision and multilayered transplantation of the amniotic membrane. Histopathologic staining of the excised tissues revealed mast cells in both the pterygium and ulcer site.⁴ The authors considered that the head of a pterygium might induce a chronic inflammatory response to the cornea and the development of Mooren's ulcer.

Conservative medications were ineffective in our patient. We considered two possible reasons for this treatment failure. First, the corneal ulcer failed to recover completely because of the persistent stimulation produced by the coexisting pterygium. Second, the irregular apophysis of the pterygium induced the patient's symptoms, including eye irritation and foreign body sensation. Therefore, combined surgery was considered in this case. We performed LKP plus pterygium excision combined with conjunctival autografting in her right eye. The shortage of donor corneal grafts

limits corneal transplantation worldwide. In previous studies, SMILE-derived cornea lenticules have been successfully applied in therapeutic keratoplasty for several diseases, including corneal perforation,¹¹ pellucid marginal corneal degeneration,¹² corneal dermoid,¹³ and corneal ectasia.¹⁴ Therefore, we decided to use a corneal lenticule obtained by SMILE as the transplant graft in LKP. It took 1 week for the lenticule graft to completely re-epithelialize after the surgery, and the thickness of the marginal corneal stroma also returned to a normal level at that time. The grafted lenticule had little effect on the corneal astigmatism. No severe complications or recurrence were observed after a 1-year follow-up.

In conclusion, our case shows that Mooren's ulcer coexisting with a pterygium is an extremely rare ocular condition that is easily misdiagnosed or missed, resulting in inappropriate treatment. Combined surgery may be an effective therapeutic approach to maintain the corneal structure and prevent disease progression. A corneal lenticule obtained by SMILE can be used as the graft in LKP during the combined surgery.

Declaration of conflicting interest

The authors declare that there is no conflict of interest.

Funding

The author(s) disclosed receipt of the following financial support for the research, authorship, and/or publication of this article: This study was supported by the Zhejiang Province Public Welfare Technology Application Research Project (No. LGF20H120004) and the Jinhua Science and Technology Bureau (No. 2018-3-013). No author has a financial or proprietary interest in any material or method mentioned.

ORCID iD

Na He  <https://orcid.org/0000-0003-1066-0478>

References

1. Alhassan MB, Rabiou M and Agbabiaka IO. Interventions for Mooren's ulcer. *Cochrane Database Syst Rev* 2014; 22: CD006131.
2. Chen J, Xie H and Wang Z, et al. Mooren's ulcer in China: a study of clinical characteristics and treatment. *Br J Ophthalmol* 2000; 84: 1244–1249.
3. Dong Y, Zhang Y, Xie L, et al. Risk factors, clinical features, and treatment outcomes of recurrent Mooren ulcers in china. *Cornea* 2017; 36: 202–209.
4. Touge C, Mihara E, Funakoshi T, et al. A case of Mooren's ulcer associated with a pterygium. *Jpn J Ophthalmol* 2005; 49: 543–545.
5. el-Mofty A. Bilateral simultaneous Mooren's ulcers with binasal and bitemporal pterygia. A possible aetiological and pathological correlation. *Bull Ophthalmol Soc Egypt* 1976; 69: 165–176.
6. Gagnier JJ, Kienle G, Altman DG, et al. The CARE guidelines: consensus-based clinical case reporting guideline development. *Headache* 2013; 53: 1541–1547.
7. Kim EC, Jun AS, Kim MS, et al. Mooren ulcer occurring at donor site after contralateral conjunctivolimbal autograft for recurrent pterygium. *Cornea* 2012; 31: 1357–1358.
8. Kim DH, Kim MK, Wee WR, et al. Mooren's ulcer in a cornea referral practice in Korea. *Ocul Immunol Inflamm* 2016; 24: 55–59.
9. Srinivasan M, Zegans ME, Zelefsky JR, et al. Clinical characteristics of Mooren's ulcer in South India. *Br J Ophthalmol* 2007; 91: 570–575.
10. Yang L, Xiao J, Wang J, et al. Clinical characteristics and risk factors of recurrent Mooren's ulcer. *J Ophthalmol* 2017; 2017: 8978527.
11. Wu F, Jin X, Xu Y, et al. Treatment of corneal perforation with lenticules from small incision lenticule extraction surgery: a preliminary study of 6 patients. *Cornea* 2015; 34: 658–663.
12. Kalinnikov Y, Leontyeva G, Zinovyeva A, et al. Simultaneous implantation of refractive lenticule and intracorneal ring segment in the management of pellucid marginal

- degeneration. *J Refract Surg* 2019; 35: 606–609.
13. Wan Q, Tang J, Han Y, et al. Surgical treatment of corneal dermoid by using intrastromal lenticule obtained from small-incision lenticule extraction. *Int Ophthalmol* 2020; 40: 43–49.
 14. Xue C, Xia Y, Chen Y, et al. [Treatment of large corneal perforations with acellular multilayer of corneal stromal lenticules harvested from femtosecond laser lenticule extraction]. *Zhonghua Yan Ke Za Zhi* 2015; 51: 655–659.