



The Effect of Nail Lacquer on Taxane-Induced Nail Changes in Women With Breast Cancer

Osama Alshari¹ , Abdelwahab Aleshawi², Ahmed H Al Sharie³ , Ala'a Msameh², Isra Al-Omari³, Renad Msameh³, Abdallah Almegdadi³ and Dima Albals⁴

¹Department of Internal Medicine, Division of Oncology, Faculty of Medicine, Jordan University of Science & Technology, Irbid, Jordan. ²King Abdullah University Hospital, Irbid, Jordan. ³Faculty of Medicine, Jordan University of Science & Technology, Irbid, Jordan. ⁴Department of Pharmaceutical Sciences, Faculty of Pharmacy, Yarmouk University, Irbid, Jordan.

Breast Cancer: Basic and Clinical Research
Volume 14: 1–4
© The Author(s) 2020
Article reuse guidelines:
sagepub.com/journals-permissions
DOI: 10.1177/1178223420929702



ABSTRACT

OBJECTIVE: Taxane-induced nail changes are considered as an important cosmetic manifestation with an incidence that reaches up to 44% of patients treated with taxane-included therapeutic regimens. In this article, we represent a clinical observational study to evaluate the effect of cosmetic nail lacquer on taxane-induced nail changes in female patients diagnosed with breast cancer.

METHODS: Prospectively, we identified those women who were diagnosed with breast cancer, scheduled to have AC-Taxol protocol. Any female with previous dermatological or systemic disorders that affect nails was excluded from the study. Patients were categorized into 2 groups based on the utilization of nail lacquer. The first group includes women who started to use the nail lacquer after development of nail changes. The second group comprises those women who did not use the nail lacquer at any occasion.

RESULTS: A total of 59 female patients were included in the study; 46 (78%) of them developed nail changes and the main change was nail discoloration. The first group which has used nail lacquer (17, 28.8%) showed an improvement among 15 (78.9%) patients, whereas 2 (7.4%) of them continued to have worsening symptoms. On the contrary, most of the second group (25, 92.9%) did not show any improvement in nail changes. A statistical significance between the tested groups was observed ($P = .000$). There is no statistical association between the progression of nail changes and the age of patients.

CONCLUSIONS: Taxane-induced nail changes are considered as an important clinical, cosmetic, and psychological complication, especially for female patients with cancer. This article suggests that nail lacquer may have an effect in the improvement of nail changes, especially nail discoloration. Further investigations are recommended to prove the efficacy of nail lacquer.

KEYWORDS: Paclitaxel, breast cancer, nail changes, nail lacquer

RECEIVED: February 5, 2020. **ACCEPTED:** May 5, 2020.

TYPE: Original Research

FUNDING: The author(s) received no financial support for the research, authorship, and/or publication of this article.

DECLARATION OF CONFLICTING INTERESTS: The author(s) declared no potential conflicts of interest with respect to the research, authorship, and/or publication of this article.

CORRESPONDING AUTHOR: Osama Alshari, Department of Internal Medicine, Division of Oncology, Faculty of Medicine, Jordan University of Science & Technology, P. O. Box: 3030, Irbid 22110, Jordan. Email: osamaalshari@yahoo.com

Introduction

Chemotherapeutic agents–induced nail changes are diverse and have a wide spectrum of clinical presentations. Most of them resolve automatically after the end of chemotherapeutic sessions but during the treatment course, nail changes can transfer from a tolerable morphological and structural changes into painful lesions which can impair several functionalities, the mechanism in which chemotherapeutic agents affect nails is not well understood or studied.¹ Hyperpigmentation of nails toward black or brown indicates melanonychia, whereas a greenish discoloration suggests a *Pseudomonas* infection. On the contrary, subungual hemorrhage can change the color of nails into red, brown, or orange; all these changes could be associated with drug intake.^{1,2} Beau's lines are another observed nail changes identified as a depressed horizontal lines with partial or full nail involvement.³ Adding to this, nail bed separation (onycholysis) is a painful manifestation that can be associated with hemorrhagic bullae and subungual hematoma.^{4,5} Other changes such

as acute paronychia, onychomadesis, hypopigmentation, and subungual hyperkeratosis or abscess formation were noticed.^{6,7}

There are no specific treatments for such nail changes as their existence is directly linked to chemotherapy. A prevention plan should be optimized which includes the avoidance of water, chemicals, or any nail cosmetic products that can exaggerate the changes; the use of emulsions is also endorsed.¹ During therapy period, patients are advised to apply topical antiseptic solutions to prevent microbial growth over nails; sometimes, nail polish is recommended to prevent ultraviolet light A from causing photo-onycholysis.⁸ Hydroxypropyl chitosan has been proved to protect nails from dermatophyte infections which can be helpful in such situations.⁹ In the case of brittle nails, oral biotin supplements cause a dramatic improvement by 25% increase in nail thickness.¹⁰ The use of corticosteroids to reduce the inflammatory process or drug dose adjustments are also discussed.⁸ In a case series, chemotherapy-induced paronychia was treated successfully using topical povidone-iodine.¹¹ Therapeutic regimes



Creative Commons Non Commercial CC BY-NC: This article is distributed under the terms of the Creative Commons Attribution-NonCommercial 4.0 License (<https://creativecommons.org/licenses/by-nc/4.0/>) which permits non-commercial use, reproduction and distribution of the work without further permission provided the original work is attributed as specified on the SAGE and Open Access pages (<https://us.sagepub.com/en-us/nam/open-access-at-sage>).

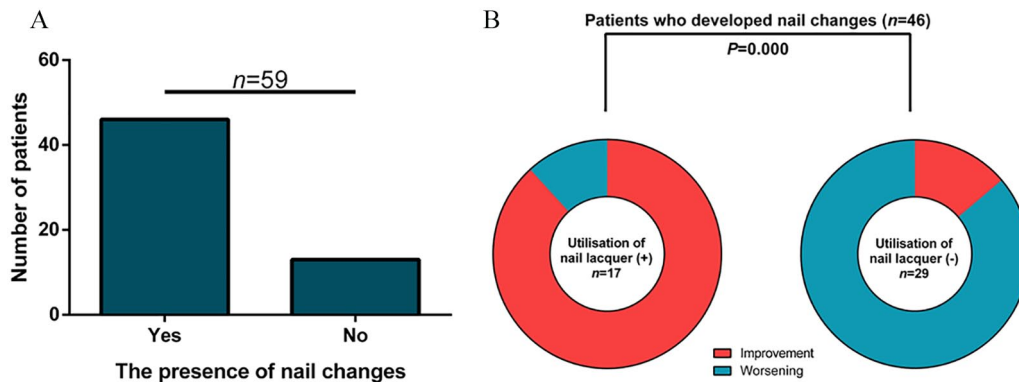


Figure 1. (A) The number of patients who developed nail changes among 59 female patients included in this study. (B) Donut plots describing the percentage of patients who developed nail changes improvement and resolution in each group compared to non-improving ones.

for nail changes vary according to the pathological setting and should be personalized.

Taxanes have gained a wide popularity among oncologist due to their unique efficacy against solid tumors including lung, breast, and ovarian cancer.¹² Many side effects such as cardiotoxicity, nail toxicity, peripheral neuropathy, fluid retention syndrome, arthralgia, myelosuppression, and skin reactions caused by taxanes have been identified.¹³⁻¹⁶ In the literature, several case reports described the effect of taxanes on nails which includes onycholysis, melanonychia, subungual hemorrhage, subungual hyperkeratosis, Beau's lines, and nail dystrophy.^{4,6,17-19} In this work, we represent a clinical observational study to evaluate the effect of cosmetic nail lacquer on taxane-induced nail changes in female patients diagnosed with breast cancer.

Methods

This study was conducted at King Abdullah University Hospital (KAUH), a tertiary care center that is affiliated with Jordan University of Science and Technology (JUST), located in northern Jordan. After obtaining the Institutional Review Board approval, we prospectively identified those women who were scheduled to have taxane-base chemotherapeutic regimens for breast cancer between January 2017 and December 2018. The following information were obtained: demographics, type of malignancy, chemotherapeutic protocol, associated nail changes, utilization of nail lacquer, progression of nail changes, and any associated dermatological or systemic disorders.

The included group comprised women who were diagnosed with breast cancer, scheduled to undergo AC-Taxol protocol which includes adriamycin and cyclophosphamide, followed by treatment with paclitaxel. Any female patient with previous dermatological or systemic disorders that affect nails was excluded from the study. Serious nail changes that need interventional management such as acute paronychia and onycholysis were excluded.

The patients were categorized into 2 groups based on the utilization of nail lacquer. The first group includes women who started to use the nail lacquer after development of nail changes. The second group comprises those women who did not use the

nail lacquer at any occasion. The patients were divided according to the treating oncologist. The patients were treated under the supervision of 2 consultant oncologists who follow the same guidelines. One of them prescribes the nail lacquer for any woman who is scheduled to have taxane-based chemotherapy sessions and started to develop nail changes. The other consultant did not provide the nail lacquer for his patients.

Patients were investigated for their nail changes and followed by 3 independent blinded expert doctors. After that, data were entered into a spreadsheet. Statistical analysis was performed using IBM SPSS statistics for Windows v.21 (Armonk, NY, USA). Data were presented as frequency distributions for categorical variables and mean \pm standard error of the mean (SEM) for continuous variables. Statistical significance was considered when $P < .05$. Pearson χ^2 test was used to investigate the significance of association between categorical variables, whereas Student t test and 1-way analysis of variance were applied to examine the significance level for continuous variables.

Results

According to the selection criteria, 59 female patients were included in the study. The mean age for the patients is 47.2 years. Among them, 46 (78%) patients developed nail changes, mainly nail discoloration (Figure 1A). The patients who developed nail changes were subdivided into 2 groups based on the utilization of nail lacquer. The first group which has used nail lacquer (17, 28.8%) showed an improvement among 15 (78.9%) patients, whereas 2 (7.4%) of them continued to have worsening symptoms (Figure 1B). On contrary, most of the second group (25, 92.9%) did not show any improvement in nail changes (Figure 1B). A statistical significance between the tested groups was observed ($P = .000$). There is no statistical association between the progression of nail changes and patient's age.

Discussion

It is well known than nail changes are not a common side effect for the administration of chemical therapeutic agents but it

holds many important cosmetic manifestations especially to patients with chronic illnesses and maladies.⁷ It has been reported that several agents can cause such nail changes as hormones, antimalarial agents, antimicrobials, diuretics, cathartics, and cytotoxic chemotherapeutic drugs.²⁰ One of the most profound agents to cause this phenomenon are taxanes which are potent chemotherapeutic agents with an outstanding potency and efficacy against a panel of solid tumors.¹² The use of taxanes has increased dramatically over time; this can be explained by their efficacy along with the increase in cancer incidence worldwide.²¹ Such catchy and potent pharmacological activity is linked to a wide spectrum of side effects which include neuropathies, skin reactions, water retention, nail changes, myelosuppression, myalgias, and many others.^{14,22} So as cancer has been linked to many psychological disorders that can manifest during the therapeutic period including depression and anxiety, the medical team should try their best to relieve such stress providing a suitable tool to limit the side effects of these drugs.²³ In this observational study, we provide a comprehensive and systematic study of the use of nail polish solution to prevent taxane-induced nail changes in female patients with breast cancer.

Taxane-induced nail changes are considered as an important cosmetic manifestation with an incidence that reaches up to 44% of patients treated with taxane-included therapeutic regimens.⁵ The mechanism of which taxanes exhibit their nail effects is not well studied or understood but several mechanisms have been suggested. Taxanes can cause vascular abnormalities along with thrombocytopenia which can lead to hemorrhagic onycholysis associated with subungual hematoma.⁴ A neurogenic mechanism has been also proposed in which a denervation of neurofibers of several sizes could be the cause of these nail changes.²⁴ By thinking outside the box, Cremophor EL or Tween 80 which are a well-known paclitaxel drug vehicles that have been proved to cause nail changes, this has been proposed due to decrease in the incidence of such changes when using albumin-bound paclitaxel.^{25,26} Nail changes associated with taxanes could be also caused by their anti-angiogenic activity. But the most prominent theory is the direct paclitaxel-induced nail bed damage as previously described.²⁷

The National Cancer Institute (NCI) has graded the effect of chemotherapeutic agents on nails into 3 grades in which grade 1 represents nail discoloration associated with pitting or ridging of nails, whereas grade 2 represents a total or partial loss of nail, but when there is a complete or partial loss of nail accompanied with pain that interferes with the normal nail functionalities, it is considered as grade 3.²⁸

According to the literature, several case reports have discussed the effect of taxanes on nails.^{5,11,29} Ghafoor and Chetiyawardana²⁸ have described nail changes associated with docetaxel intake in a 66-year-old patient with lung cancer. A 72-year-old patient with prostate cancer had developed

many painful nail changes due to docetaxel intake as reported by Amorim et al.³⁰ In a case series presented by Minisini et al,⁴ 7 cases of taxane-induced nail changes were reported in a variety of neoplastic growths and ages which include nail discoloration, hemorrhagic onycholysis, Beau's lines, hemorrhagic bullae, and subungual suppuration. Adding to this, in a clinical study performed to evaluate the incidence of taxane-induced nail changes in the Mexican population, it is revealed that the paclitaxel group has a higher rate of nail pathologies compared with the control group.³¹ Pigmentary nail changes were observed in patients with gastric and breast cancer in which paclitaxel group possesses a 35.7% incidence of nail changes.³² A variety of nail changes were noticed in patients on a postoperative dose of paclitaxel and cisplatin as reported by Yang et al.¹⁸

As an initial step, nail changes should be prevented by the avoidance of any corrosive materials, water contact, or any traumatic injury. The use of nail polish or petroleum jelly aids the prevention of water loss from nails which could have a beneficial effect.¹ Recently, the use of cryotherapy has been proposed for the prevention of taxane-induced nail changes as represented by a clinical study performed among 200 patients; it was found that frozen gloves do not impact the incidence of nail changes but delay its occurrence.^{33,34} Antiseptic solutions should be applied to prevent the complications of nail changes including nail infections or abscess formation.⁸ A variety of therapeutic and surgical solutions have been discussed to treat drug-induced nail changes as previously described.¹

As the molecular absorption or penetration through nails with good nail integrity is hard, the chemical constituents of nail polish could not cause the observed protective effects.³⁵ We propose that the positive significant results obtained in this work is due photo-onycholysis which is a phototoxic effect initiated when nails are exposed to natural or artificial light while patients are using therapeutic chemical agents.³⁶ Photo-onycholysis tends to spare thumbs with several digits involved; it could be the result of a toxic mechanism or allergic reaction to drugs, and these changes will disappear automatically with drug withdrawal.²⁰ A previous study had shown that prolonged use of paclitaxel has caused an increase in the incidence of nail changes associated with light exposure.³⁷ A study conducted on 91 patients revealed that taxanes' use had caused onycholytic changes in patients taking more than 6 courses of paclitaxel per week. All of the patients who developed these changes had their treatment during summer; this observational fact aided the correlation between light exposure and taxane-induced nail changes.³⁸ So patients are advised to avoid light exposure to slow the progression of these changes.⁸

Conclusions

Taxane-induced nail changes are a major medical, cosmetic, and psychological manifestations especially for female patients

with cancer. In this study, we present a clinical systematic and comprehensive observational study discussing the use of nail polish to prevent the progression of taxane-induced nail changes in patients with breast cancer. The results have suggested that nail lacquer may have an effect in the improvement of nail changes, particularly nail discoloration. Further clinical trials and investigations are recommended to prove the efficacy of nail lacquer.

Author Contributions

All authors contributed significantly and in agreement with the content of the article. All authors were involved in project design, data collection, analysis, statistical analysis, data interpretation and writing the manuscript. All authors presented substantial contributions to the article and participated of correction and final approval of the version to be submitted.

Data Availability


The data sets generated and analyzed during this study are available upon request.

Ethical Approval and Patient Consent

Written informed consents were obtained from the patients. Institutional approval was obtained from the Institutional Review Board (IRB) at Jordan University of Science and Technology (JUST). This study was conducted in accordance with the Declaration of Helsinki.

ORCID iDs

Osama Alshari  <https://orcid.org/0000-0002-5400-5160>

Ahmed H Al Sharie  <https://orcid.org/0000-0003-1311-806X>

REFERENCES

- Robert C, Sibaud V, Mateus C, et al. Nail toxicities induced by systemic anticancer treatments. *Lancet Oncol*. 2015;16:e181-e189.
- Gupta A, Parakh A, Dubey AP. Chemotherapy induced nail changes. *Indian J Dermatol*. 2008;53:204-205.
- Huang T-C, Chao T-Y. Mees lines and Beau lines after chemotherapy. *CMAJ*. 2010;182:149-149.
- Minisini AM, Tosti A, Sobrero AF, et al. Taxane-induced nail changes: incidence, clinical presentation and outcome. *Ann Oncol*. 2003;14:333-337.
- Roh MR, Cho JY, Lew W. Docetaxel-induced onycholysis: the role of subungual hemorrhage and suppuration. *Yonsei Med J*. 2007;48:124-126.
- Alexandrescu DT, Vaillant J, Wiernik PH. Trastuzumab/docetaxel-induced nail dystrophy. *Int J Dermatol*. 2006;45:1334-1336.
- Gilbar P, Hain A, Peereboom V-M. Nail toxicity induced by cancer chemotherapy. *J Oncol Pharm Pract*. 2009;15:143-155.
- Patel S, Tosti A. An overview of management of drug-induced hair and nail disorders. *Clin Pract*. 2014;11:327-339.
- Ghannoum M, Long L, Isham N, et al. Ability of hydroxypropyl chitosan (HPCH) nail solution to protect against dermatophyte nail infection. *Antimicrob Agents Chemother*. 2014;59:1844-1848.
- Colombo VE, Gerber F, Bronhofer M, Floersheim GL. Treatment of brittle fingernails and onychoschizia with biotin: scanning electron microscopy. *J Am Acad Dermatol*. 1990;23:1127-1132.
- Capriotti K, Capriotti J, Pelletier J, Stewart K. Chemotherapy-associated paronychia treated with 2% povidone-iodine: a series of cases. *Cancer Manag Res*. 2017;9:225-228.
- Markman M. Managing taxane toxicities. *Support Care Cancer*. 2003;11:144-147.
- Vaishampayan U, Parchment RE, Jasti BR, Hussain M. Taxanes: an overview of the pharmacokinetics and pharmacodynamics. *Urology*. 1999;54:22-29.
- Cella D, Peterman A, Hudgens S, Webster K, Socinski MA. Measuring the side effects of taxane therapy in oncology. *Cancer*. 2003;98:822-831.
- Chiu N, Chiu L, Chow R, et al. Taxane-induced arthralgia and myalgia: a literature review. *J Oncol Pharm Pract*. 2017;23:56-67.
- Huang K-L, Lin K-Y, Huang T-W, et al. Prophylactic management for taxane-induced nail toxicity: a systematic review and meta-analysis. *Eur J Cancer Care (Engl)*. 2019;28:e13118.
- Alessandrini A, Starace M, Cerè G, Brandi N, Piraccini BM. Management and outcome of taxane-induced nail side effects: experience of 79 patients from a single centre. *Skin Appendage Disord*. 2019;5:276-282.
- Yang S-T, Cheng M, Lee N-R, Chang W-H, Lee Y-L, Wang P-H. Paclitaxel-related nail toxicity. *Taiwan J Obstet Gynecol*. 2019;58:709-711.
- Ghetti E, Piraccini B, Tosti A. Onycholysis and subungual haemorrhages secondary to systemic chemotherapy (paclitaxel). *J Eur Acad Dermatol Venereol*. 2003;17:459-460.
- Piraccini BM, Tosti A. Drug-induced nail disorders. *Drug Safety*. 1999;21:187-201.
- Bray F, Ferlay J, Soerjomataram I, Siegel RL, Torre LA, Jemal A. Global cancer statistics 2018: GLOBOCAN estimates of incidence and mortality worldwide for 36 cancers in 185 countries. *CA Cancer J Clin*. 2018;68:394-424.
- Ho MY, Mackey JR. Presentation and management of docetaxel-related adverse effects in patients with breast cancer. *Cancer Manag Res*. 2014;6:253-259.
- Sun F-K, Hung C-M, Yao Y, Fu C-F, Tsai P-J, Chiang C-Y. The effects of logotherapy on distress, depression, and demoralization in breast cancer and gynecological cancer patients: a preliminary study [published online ahead of print August 28, 2019]. *Cancer Nurs*. doi:10.1097/NCC.0000000000000740.
- Wasner G, Hilpert F, Schattschneider J, Binder A, Pfisterer J, Baron R. Docetaxel-induced nail changes—a neurogenic mechanism: a case report. *J Neurooncol*. 2002;58:167-174.
- De Giorgi U, Rosti G, Monti M, Frassinetti GL, Marangolo M. Onycholysis secondary to multiple paclitaxel 1-hour infusions: possible role for its vehicle (Cremophor EL). *Ann Oncol*. 2003;14:1588-1589.
- Schepisi G, Conteduca V, Lolli C, Medri M, De Giorgi U. Taxane-related nail toxicity. *Lancet Oncol*. 2015;16:e310-e311.
- Jin W, Jung J, Ro K, Shim S, Kim M, Cinn Y. A case of taxane-induced onycholysis and subungual abscesses. *Ann Dermatol*. 2007;19:28-30.
- Ghafoor G, Chetiyawardana A. Nail changes secondary to docetaxel chemotherapy: a case report. *J Med Case Rep*. 2008;2:24.
- Doleschal B, Petzer A, Aichberger KJ. Taxan-associated nail toxicity. *BMJ Case Rep*. 2017;2017:bcr2016218980.
- Amorim G, Dlv A, Amorim G, Rm A-f. Nail changes due to docetaxel therapy: case report. *J Clin Res Dermatol*. 2017;4:1-3.
- Calderón L, Tirado A, Lázaro-León J, Ponce-Oliviera RM, Bonifaz A. Frequency of nail alterations due to taxane agents in Mexican patients. *Dermatol Rev Mexicana*. 2015;59:493-503.
- Yorulmaz A, Dogan M, Artuz F, Zengin N. Comparison of pigmentary side effects of taxanes and anthracyclines: an onychoscopic evaluation. *Cutan Ocul Toxicol*. 2017;36:135-139.
- Can G, Aydinler A, Cavdar I. Taxane-induced nail changes: predictors and efficacy of the use of frozen gloves and socks in the prevention of nail toxicity. *Eur J Oncol Nurs*. 2012;16:270-275.
- Rosenthal ET. Frozen glove therapy for docetaxel-induced hand problems may not fit all. *Oncol Times*. 2005;27:24-25.
- Chiu WS, Belsey NA, Garrett NL, Moger J, Delgado-Charro MB, Guy RH. Molecular diffusion in the human nail measured by stimulated Raman scattering microscopy. *Proc Natl Acad Sci USA*. 2015;112:7725-7730.
- Al-Kathiri L, Al-Asmaili A. Diclofenac-induced photo-onycholysis. *Oman Med J*. 2016;31:65-68.
- Hussain S, Anderson DN, Salvatti ME, Adamson B, McManus M, Braverman AS. Onycholysis as a complication of systemic chemotherapy. *Cancer*. 2000;88:2367-2371.
- Hussain S, Anderson DN, Salvatti ME, Adamson B, McManus M, Braverman AS. Onycholysis as a complication of systemic chemotherapy: report of five cases associated with prolonged weekly paclitaxel therapy and review of the literature. *Cancer*. 2000;88:2367-2371.