



Available online at www.sciencedirect.com

ScienceDirect

journal homepage: <http://ees.elsevier.com/jot>



ORIGINAL ARTICLE

Intra-articular injection of an antioxidant formulation did not improve structural degeneration in a rat model of post-traumatic osteoarthritis



Yau-Chuk Cheuk ^{a,b}, Sai-Chuen Fu ^{a,b}, Sze-Wing Mok ^{a,b},
Kevin Ki-Wai Ho ^{a,b}, Leung-Kim Hung ^{a,b}, Kai-Ming Chan ^{a,b,*}

^a Department of Orthopaedics and Traumatology, Faculty of Medicine, The Chinese University of Hong Kong, Hong Kong Special Administrative Region

^b Lui Che Woo Institute of Innovative Medicine, Faculty of Medicine, The Chinese University of Hong Kong, Hong Kong Special Administrative Region

Received 26 May 2016; received in revised form 22 July 2016; accepted 10 August 2016
Available online 8 September 2016

KEYWORDS

antioxidant;
deferoxamine;
osteoarthritis;
oxidative stress;
quercetin;
vitamin C

Summary *Background/objective:* Oxidative stress plays an important role in osteoarthritis (OA), causing inflammation and matrix degradation in joints. Previous studies have shown that antioxidants such as quercetin and vitamin C are potential candidates for treating OA. We aimed to determine whether a formulation of quercetin and vitamin C, together with an iron chelator, could retard OA progression in a post-traumatic OA rat model.

Methods: Twelve rats received anterior cruciate ligament transection for OA induction. At 20 weeks postoperation, weekly intra-articular injection of 50 μ L of either saline or a formulation of quercetin dehydrate, sodium-L-ascorbate, and deferoxamine mesylate was given consecutively for 4 weeks ($n = 5$). Gait analysis was performed at pretreatment, and at 1 week and 5 weeks post-treatment. Microcomputed tomography scanning and histological scoring were performed at 5 weeks post-treatment.

Results: Gait analysis showed that intra-articular injections of antioxidant formulation did not improve pain-associated Limb Idleness Index over time ($p = 0.449$, Friedman test). However, at 5 weeks post-treatment, the treatment group exhibited a significantly lower Limb Idleness Index than the control group ($p = 0.047$, Mann–Whitney U test). At 5 weeks post-treatment, microcomputed tomography analysis revealed that there was no difference in any parameter between the treatment and control groups ($p > 0.05$, Student t test). Severe OA histopathological changes were found in both groups. The Osteoarthritis Research Society International

* Corresponding author. Department of Orthopaedics and Traumatology, Faculty of Medicine, The Chinese University of Hong Kong, Prince of Wales Hospital, 30-32 Ngan Shing Street, Shatin, New Territories, Hong Kong Special Administrative Region.
E-mail address: kaimingchan@cuhk.edu.hk (K.-M. Chan).

scores of the treatment and control groups were 20 (range, 20–26) and 20 (range, 9–26), respectively ($p = 0.382$, Mann–Whitney U test).

Conclusion: Intra-articular injection of an antioxidant formulation containing quercetin, vitamin C, and deferoxamine did not retard OA progression in advanced-stage OA. Future studies should aim to determine whether giving antioxidants in early OA, with prolonged drug retention, would be effective in retarding OA progression.

© 2016 The Authors. Published by Elsevier (Singapore) Pte Ltd on behalf of Chinese Speaking Orthopaedic Society. This is an open access article under the CC BY-NC-ND license (<http://creativecommons.org/licenses/by-nc-nd/4.0/>).

Introduction

Osteoarthritis (OA), a degenerative joint disease, affects the whole joint, causing pain, deformity, and loss of function. According to the World Health Organization, it is estimated that 9.6% of men and 18.0% of women aged over 60 years have symptomatic OA (<http://www.who.int/chp/topics/rheumatic/en/>). Currently, there is no promising treatment for OA. Increasing evidence showed that oxidative stress resulting from excessive production of reactive oxygen species (ROS) plays a role in the pathogenesis of OA [1]. Clinical studies demonstrated that oxidative stress was present in OA patients, where an abnormal antioxidant level was observed in the synovial fluid and serum of patients with primary and secondary OA [2,3]. Oxidative stress triggers inflammatory responses [4], induces extracellular matrix degradation, and inhibits matrix synthesis [5], and eventually leads to OA changes. ROS pathways are becoming one of the new treatment targets for OA [6]. To counteract the elevated oxidative stress, antioxidant therapy has been developed to reinforce the cellular antioxidant status. These include antioxidant supplements, dietary polyphenols, free radical scavengers, nicotinamide adenine dinucleotide phosphate (NADPH) oxidase inhibitors, and inducible nitric oxide synthase (iNOS) inhibitors [7]. Combining multiple antioxidants that have different actions may be a better approach to tackle oxidative stress in OA. Of these, quercetin (Que) and vitamin C are two well-known antioxidants that possess potential beneficial effects on OA.

Que, a polyphenolic bioflavonoid found ubiquitously in food of plant origin, exhibits a wide range of effects on biological systems, particularly on anti-inflammation and antioxidation [8]. *In vivo* studies demonstrated that Que reduced the expression of inflammatory markers, restored antioxidant defence, subsided OA clinical signs, and delayed arthritis in rats with adjuvant arthritis [9,10]. The elevated inflammation in post-traumatic OA rats had also been reversed with Que treatment [11]. Furthermore, clinical studies on a dietary supplement consisting of Que had also shown favourable effects on OA-associated symptoms [12,13].

Another potent antioxidant, vitamin C (ascorbic acid), has a broad spectrum of antioxidative activities, owing to its ability to scavenge numerous ROS [14]. It also acts as a cofactor for numerous biochemical reactions and is essential for collagen biosynthesis [15]. A preclinical study on surgically induced OA in guinea pigs [16] and an

epidemiological study on OA patients [17], both suggested that high dietary intake of vitamin C reduced the risk of cartilage loss and delayed disease progression. In addition, vitamin C level in joint fluids was significantly lower in patients with severe OA [3].

However, vitamin C can exhibit pro-oxidant activities, particularly in the presence of iron [18,19]. Iron level in the serum [20] and synovial fluid [21] of patients with OA was found to be elevated. It has been proposed that the high level of iron increases ROS, which leads to an upregulation of matrix metalloproteinases, thereby causing cartilage damage after joint trauma [22]. Iron chelators, such as deferoxamine (also known as desferrioxamine; DFO) and deferiprone, are commonly used chelating agents for removing excess iron from the body [23]. It can relieve oxidative stress in arthritic joint by inhibiting the iron-catalysed formation of destructive oxygen metabolites [24]. An animal study had also demonstrated that intra-articular (IA) injections of DFO reduce blood-induced knee joint damage [25].

Since Que, vitamin C, and DFO exhibit different mechanisms, we proposed to inject them as a formulation to treat OA knee in a post-traumatic rat model. In a previous pilot study on repeated IA injections of this formulation in OA rats, we observed a reduction in pain-associated limb idleness and less severe histopathological changes at 4 months post OA induction (Supplementary materials). These suggested that this antioxidant formulation may possess both symptom and disease-modifying potential. In this study, the same formulation was investigated to further prove its effectiveness in pain modulation and delaying degenerative changes in both the articular cartilage and the subchondral bone at a late stage OA in the knee.

Materials and methods

Anterior cruciate ligament transection for induction of post-traumatic OA

Animal experiments were approved by the Animal Experimentation Ethics Committee in The Chinese University of Hong Kong (Ref. no.: 11/008/DRG). Twelve female Sprague-Dawley rats at 12 weeks of age (average body weight 229.1 ± 13.2 g) underwent unilateral anterior cruciate ligament transection of the right knee for OA induction [26]. Under general anaesthesia, a medial parapatellar incision

was made and the patella was dislocated to expose the knee joint; the anterior cruciate ligament was transected with microscissors. An anterior drawer test was performed to ensure successful transection. After patella relocation, joint capsule and skin were closed sequentially. Rats were allowed free cage activity after the operation.

IA injection of Que formulation

At Week 20 postoperation, IA injections were given once a week, for 4 consecutive weeks. Antioxidant formulation containing 30 mg/mL sodium-L-ascorbate (Cat no.: A4034; Sigma-Aldrich, St. Louis, MO, USA), 1 mg/mL Que dihydrate (Cat no.: Q0125; Sigma-Aldrich), and 200 µg/mL deferoxamine mesylate (Cat no.: D9533; Sigma-Aldrich) was freshly prepared in sterile distilled water as a suspension. Under general anaesthesia and with the knee flexed, 50 µL antioxidant formulation or 0.9% saline was injected slowly into the operated knee of the rats through the transpatellar tendon approach using a 50 µL syringe with a 26G removable needle (Hamilton Company, Reno, NV, USA).

Functional assessment by gait analysis

At pretreatment (20 weeks postoperation), and 1 week and 5 weeks post-treatment, gait analysis was performed using Catwalk XT 9.0 system (Noldus Information Technology, Wageningen, The Netherlands). Rats were allowed to walk voluntarily back and forth along a glass walkway. Runs with <30% variation in the speed were recorded as compliant runs and were used for analysis. Gait parameters, including Limb Idleness Index (LII), to detect OA-associated pain were calculated [26].

Microcomputed tomography analysis

At 5 weeks post-treatment, rats were sacrificed by an overdose of pentobarbital. The whole knee joint segment was harvested for microcomputed tomography (µCT) scanning (VivaCT40; Scanco Medical AG, Brüttisellen, Switzerland) at a resolution of 35 µm. Analysis was performed by the built-in software as described previously [26]. In brief, a rectangular volume of interest with dimensions of 2 mm (L) × 1 mm (W) × 0.5 mm (D) was put in the subchondral bone at the medial and lateral tibial epiphysis, where OA-related bone alterations were found previously [6]. Trabecular indices including bone volume/tissue volume, connectivity density, trabecular thickness, trabecular number, and trabecular separation were determined.

Histological scoring

Knee samples were fixed in 10% buffered formalin solution overnight, decalcified in 9% formic acid for 4 weeks, and paraffin embedded. Five micron frontal sections were prepared for routine hematoxylin and eosin staining, and toluidine blue staining. The Osteoarthritis Research Society International (OARSI) Osteoarthritis Cartilage Histopathology Assessment System (OOCHAS system) was used to

evaluate the severity of OA in the samples as a combined score of six grades of severity × four stages (extent of affected regions) by two raters (YC Cheuk and SW Mok) [27].

Statistical analysis

Statistical analysis was performed using SPSS (version 20.0 SPSS Inc., Chicago, IL, USA). All parametric tests were performed after checking for normal distribution with Kolmogorov–Smirnov test; otherwise, a nonparametric equivalence was used. Friedman test was used to compare gait data with respect to temporal changes. To compare µCT data, and histological scoring between the control and treatment groups, Student *t* test or Mann–Whitney *U* test was performed according to the normality and the nature of the data (continuous vs. ordinal data). Inter-rater reliability of histological scoring between two raters was evaluated by calculation of the intraclass correlation coefficient. All statistical significance was determined at $p < 0.05$.

Results

Among the 12 rats, the foot of a rat was trapped in the cage at 10 weeks postoperation and only gait data at preoperation were collected. In the treatment group, one rat died at Week 27 postoperation (4 weeks after the 4th IA injection) of unknown reasons. These two rats were excluded from data analysis. The total number of rats that were used for data analysis was 5 in each group.

Gait analysis for pain detection

Repeated IA injections of the antioxidant formulation did not lead to improvement in pain-associated LII ($p = 0.449$, Friedman test). At 5 weeks post-treatment, the treatment group exhibited a significantly lower LII than the control group ($p = 0.047$, Mann–Whitney *U* test). However, at 1 week post-treatment, no significant difference was detected between the control and treatment groups (Figure 1).

Micro-CT analysis for microarchitectural changes in subchondral bone

At 5 weeks post-treatment (28 weeks postoperation), within the region of interest (ROI) in the tibia epiphysis, at either medial or lateral compartment, there was no significant difference in all µCT parameters between the control and treatment groups ($p > 0.05$, Student *t* test) (Table 1). However, in the treatment group, there was a significantly higher trabecular thickness and bone mineral density in the medial compartment as compared with the lateral compartment ($p = 0.019$ and $p = 0.010$, respectively; paired *t* test). No significant difference was observed within the control group.

Histological scoring

The intraclass correlation coefficient of histological scores between two raters was 0.975, indicating good inter-rater

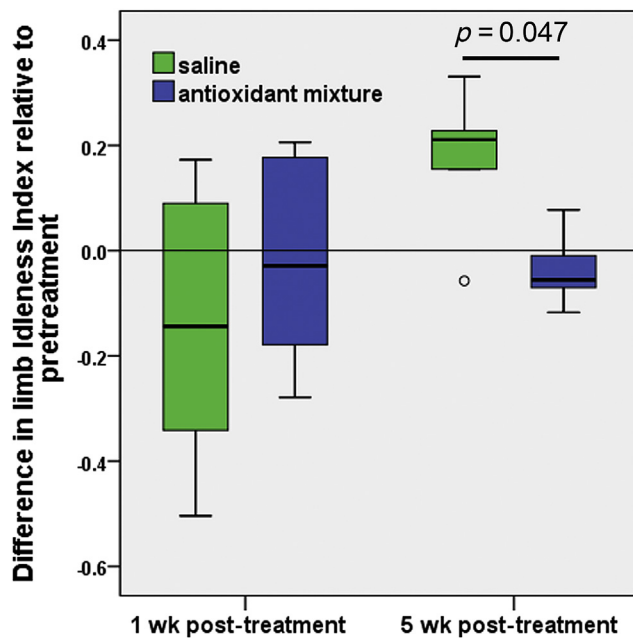


Figure 1 Gait analysis of ACLT rats at pretreatment, and 1 week and 5 weeks post-treatment with either saline or an antioxidant formulation. The values are presented as the difference in LII compared with the pretreatment level. An increase in the LII indicates pain-associated gait changes. No significant difference was detected after antioxidant treatment ($p = 0.449$, Friedman test). At 5 weeks post-treatment, the treatment group exhibited a significantly lower LII than the control group ($p = 0.047$, Mann–Whitney U test). ACLT = anterior cruciate ligament transection; LII = Limb Idleness Index.

reliability. The median maximum Osteoarthritis Research Society International (OARSI) scores of the operated knee in the treatment and control groups were 20 (range 20–26) and 20 (range 9–26), respectively ($p = 0.382$,

Mann–Whitney U test). The most pathological site in both groups was the medial tibia. Regardless of treatments, at 28 weeks postoperation (5 weeks post-treatment), the rat knees showed complete cartilage erosion accompanied by subchondral bone remodelling in the posterior compartment of medial tibial plateau (Figure 2).

Discussion

The major limitation of the current study is its small sample size with a large within-group variation in the key outcome measures, which largely affects the detectable effect size. For structural assessments such as μ CT measurement and OARSI scores, the between-group differences were too small to have a practical significance, with the exception of connectivity density, which was shown to increase with OA development [26]. The observed effect size (based on t test) of antioxidant treatment on the connectivity density is 0.6045, with an observed power of 13%. It implies that 50 rats per group will be needed to detect this difference with a power of 85%, which is not possible for most animal studies. By contrast, the observed between-group difference in LII was statistically significant with an effect size of 1.82 and an observed power of 72%. It still indicates the potential of the current antioxidant formulation to treat OA even with a small-scale study. These preliminary findings may support further investigation with a larger sample size and encourage studies on dose response, drug formulation, or mechanisms of the treatment effects. Other limitations include a lack of treatment groups with individual drugs and a lack of a positive drug group. Moreover, the serum or tissue level of oxidative stress was not measured.

Apart from conservative therapy, pharmacological therapy includes oral nonsteroidal anti-inflammatory drugs and Food and Drug Administration-approved IA injectables such as analgesics, corticosteroids, and hyaluronates [28]. Systematic reviews suggested that some

Table 1 Results of μ CT measurements and OARSI scores in ACL transected rat knees at 5 weeks post-treatment (i.e., 28 weeks postoperation).

Parameter (unit)	Side	Saline group ($n = 5$)	Antioxidant formulation group ($n = 5$)	p
Bone mineral density (mg HA/ccm)	Medial	815.90 \pm 21.31	828.41 \pm 29.45	0.464
	Lateral	791.92 \pm 24.09	793.94 \pm 34.62	0.917
Bone volume/tissue volume (1)	Medial	0.52 \pm 0.10	0.51 \pm 0.10	0.894
	Lateral	0.42 \pm 0.08	0.48 \pm 0.13	0.416
Trabecular number (1/mm)	Medial	8.14 \pm 0.47	8.02 \pm 0.27	0.639
	Lateral	8.44 \pm 0.39	8.19 \pm 0.39	0.340
Trabecular thickness (mm)	Medial	0.11 \pm 0.01	0.12 \pm 0.03	0.418
	Lateral	0.09 \pm 0.01	0.10 \pm 0.02	0.518
Trabecular separation (mm)	Medial	0.13 \pm 0.02	0.13 \pm 0.01	0.927
	Lateral	0.14 \pm 0.01	0.13 \pm 0.02	0.278
Connectivity density (1/mm ³)	Medial	60.86 \pm 11.84	47.75 \pm 28.29	0.367
	Lateral	82.70 \pm 17.89	78.39 \pm 20.52	0.733
Maximum OARSI score	Operated	20 (9–26)	20 (20–26)	0.382

Data are presented as mean \pm SD for μ CT data and median (range) for OARSI score. The p values from Student t test are shown for the μ CT measurement, while those from Mann–Whitney test are shown for OARSI scores.

ACL = anterior cruciate ligament; μ CT = microcomputed tomography; OARSI = Osteoarthritis Research Society International; SD = standard deviation.

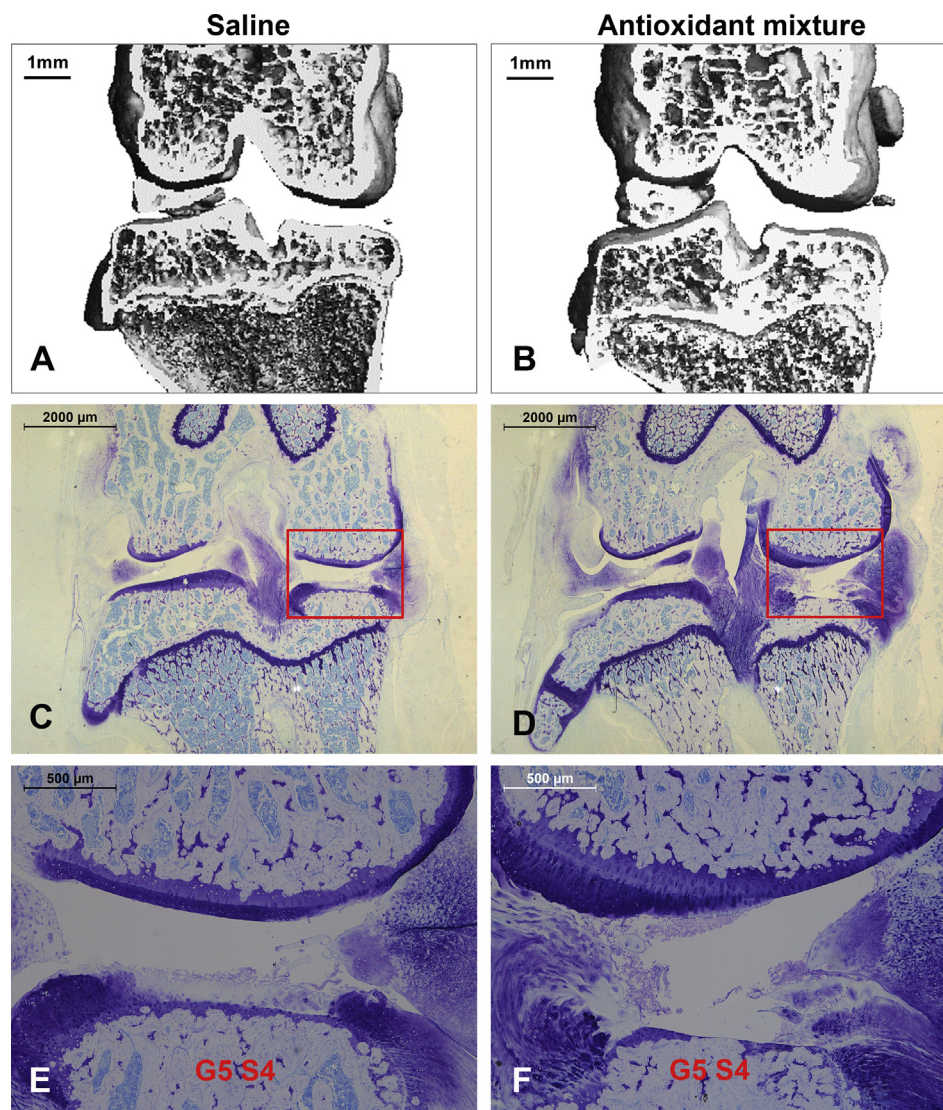


Figure 2 Bone microarchitecture and histology of rat knees at 5 weeks post-treatment with either (A, C, and E) saline or (B, D, and F) antioxidant formulation. (A and B) Coronal view of μ CT scanned rat knees. (C–F) Coronal view of toluidine blue-stained rat knees at optical magnifications (C and D) $12.5\times$ and (E and F) $50\times$. Figures 2E and 2F represent high-power images of the region of interest marked in Figures 2C and 2D. Representative image from each treatment group was selected from the sample with a group median of the maximum OARSI scores. The OA grade and stage of the sample is marked in Figures 2E and 2F in the most pathological compartment. In both groups, severe osteoarthritic changes with cartilage erosion and reparative fibrocartilage were present in the medial tibial plateau, with an extent of $>50\%$ of cartilage surface. μ CT = microcomputed tomography; OA = osteoarthritis; OARSI = Osteoarthritis Research Society International.

pharmaceuticals, particularly those administered intra-articularly, are efficacious in reducing pain but associated with side effects. Currently, there is still a lack of evidence supporting that any of the clinically used treatments can achieve promising disease-modifying effects [29,30]. Our antioxidant formulation aimed to counteract oxidative stress with naturally occurring antioxidants, which possess fewer side effects.

Our results showed that repeated IA injections (started from Week 20 postoperation) of the antioxidant formulation containing Que, vitamin C, and DFO did not lead to improvement in pain-associated LII ($p = 0.449$, Friedman test), OARSI score ($p = 0.382$, Mann–Whitney U test), and

various μ CT measurements. However, a significant difference in LII between the antioxidant formulation treatment and saline control was observed at 5 weeks after treatment. This suggests that an antioxidant formulation treatment may slow down OA progression towards asymmetric gait, although the current data did not show any symptom-modifying (gait) or disease-modifying (histology) effects. In our pilot study (Supplementary data), the antioxidant formulation was given at an earlier time point (Week 16 postoperation), which was able to reduce limb idleness at Week 28 significantly with less severe histopathological changes. It is possible that this antioxidant treatment was effective in retarding the development of OA only at early

stages (Week 16 postoperation), but not at an advanced stage (week 20 postoperation).

In our pilot study, we also tested the effects of antioxidant formulation in the sham control in order to check whether the treatment effect was specific to OA. We observed the potential treatment effects on anterior cruciate ligament transection rats only; thus, the antioxidant formulation was not likely to target only the surgical wound, which may also affect the measurement of pain-associated walking gait. As repeated injections may cause irritations to the knee and hence affect the gait analysis, larger variations in LII were observed at 1 week after treatment. It is thus difficult to evaluate the immediate pain relief. In the present study, severe cartilage degeneration was observed in both the control and the treatment group, but an increase in gait asymmetry after treatment was observed only in the control group. It suggested that an antioxidant formulation could not reverse existing osteoarthritic changes, but it might modulate nociceptive stimuli associated with advanced OA. Previous studies showed that antioxidants exerted chondroprotective effects with respect to biochemical or histological outcome measures [7], but assessments on painful responses were seldom included. In addition, most of these studies administered antioxidant treatments at an early stage of OA in the animal model [11,16]. It implies that antioxidants may work only as a dietary supplement to retard OA progression at early stages, when symptoms and signs are not overt to call for medication. The negative results of the present study also support that antioxidant treatment at advanced stage of OA may not be effective. Clinical use of antioxidant treatment for OA patients is thus limited.

Apart from the time of application, the duration and frequency of treatment will also affect the treatment outcomes. IA injections of other Que formulation were reported to show beneficial effects with more frequent injections (2 injections per week for 4 weeks) [31]. Due to a high clearance rate of biomolecules in the IA joint [32], repeated and frequent injections are necessary. The negative results observed in the current study may be owing to the insufficient drug delivery to the joint, with the four weekly injections. However, more IA injections will cause repeated trauma to joints, which is not favourable for examining the treatment effects. Thus, the use of controlled delivery systems would help reduce the number of injections and sustain the bioavailability of antioxidants in osteoarthritic joints, which will be a future direction for antioxidant treatment for OA.

Conflicts of interest

All authors declare no conflicts of interest.

Funding/support

This study was supported by Direct Grant for Research (Reference No.: 2041666) from The Chinese University of Hong Kong and General Research Fund (Reference No.: CUHK14106014) from Research Grants Council of the Hong Kong SAR.

Appendix A. Supplementary data

Supplementary data related to this article can be found at <http://dx.doi.org/10.1016/j.jot.2016.08.001>.

References

- [1] Kaiki G, Tsuji H, Yonezawa T, Sekido H, Takano T, Yamashita S, et al. Osteoarthritis induced by intraarticular hydrogen-peroxide injection and running load. *J Orthop Res* 1990;8: 731–40.
- [2] Ostalowska A, Birkner E, Wiecha M, Kasperczyk S, Kasperczyk A, Kapolka D, et al. Lipid peroxidation and antioxidant enzymes in synovial fluid of patients with primary and secondary osteoarthritis of the knee joint. *Osteoarthritis Cartilage* 2006;14:139–45.
- [3] Regan EA, Bowler RP, Crapo JD. Joint fluid antioxidants are decreased in osteoarthritic joints compared to joints with macroscopically intact cartilage and subacute injury. *Osteoarthritis Cartilage* 2008;16:515–21.
- [4] Marcu KB, Otero M, Olivetto E, Borzi RM, Goldring MB. NF-kappaB signaling: multiple angles to target OA. *Curr Drug Targets* 2010;11:599–613.
- [5] Henrotin Y, Kurz B, Aigner T. Oxygen and reactive oxygen species in cartilage degradation: friends or foes? *Osteoarthritis Cartilage* 2005;13:643–54.
- [6] Goldring MB, Berenbaum F. Emerging targets in osteoarthritis therapy. *Curr Opin Pharmacol* 2015;22:51–63.
- [7] Lepetos P, Papavassiliou AG. ROS/oxidative stress signaling in osteoarthritis. *Biochim Biophys Acta* 2016;1862:576–91.
- [8] Li Y, Yao J, Han C, Yang J, Chaudhry MT, Wang S, et al. Quercetin, inflammation and immunity. *Nutrients* 2016;8: 167–81.
- [9] Mamani-Matsuda M, Kauss T, Al-Kharrat A, Rambert J, Fawaz F, Thiolat D, et al. Therapeutic and preventive properties of quercetin in experimental arthritis correlate with decreased macrophage inflammatory mediators. *Biochem Pharmacol* 2006;72:1304–10.
- [10] Gardi C, Bauerova K, Stringa B, Kuncirova V, Slovak L, Ponist S, et al. Quercetin reduced inflammation and increased antioxidant defense in rat adjuvant arthritis. *Arch Biochem Biophys* 2015;583:150–7.
- [11] Chen YJ, Tsai KS, Chiu CY, Yang TH, Lin TH, Fu WM, et al. EGb761 inhibits inflammatory responses in human chondrocytes and shows chondroprotection in osteoarthritic rat knee. *J Orthop Res* 2013;31:1032–8.
- [12] Kanzaki N, Saito K, Maeda A, Kitagawa Y, Kiso Y, Watanabe K, et al. Effect of a dietary supplement containing glucosamine hydrochloride, chondroitin sulfate and quercetin glycosides on symptomatic knee osteoarthritis: a randomized, double-blind, placebo-controlled study. *J Sci Food Agric* 2012;92: 862–9.
- [13] Kanzaki N, Ono Y, Shibata H, Moritani T. Glucosamine-containing supplement improves locomotor functions in subjects with knee pain: a randomized, double-blind, placebo-controlled study. *Clin Interv Aging* 2015;10:1743–53.
- [14] Frei B. Reactive oxygen species and antioxidant vitamins—mechanisms of action. *Am J Med* 1994;97:5–13.
- [15] Sharma G, Saxena RK, Mishra P. Regeneration of static-load-degenerated articular cartilage extracellular matrix by vitamin C supplementation. *Cell Tissue Res* 2008;334:111–20.
- [16] Schwartz ER, Oh WH, Leveille CR. Experimentally induced osteoarthritis in guinea-pigs—metabolic responses in articular-cartilage to developing pathology. *Arthritis Rheum* 1981;24:1345–55.

- [17] McAlindon TE, Jacques P, Zhang YQ, Hannan MT, Aliabadi P, Weissman B, et al. Do antioxidant micronutrients protect against the development and progression of knee osteoarthritis? *Arthritis Rheum* 1996;39:648–56.
- [18] Satoh K, Sakagami H. Effect of metal ions on radical intensity and cytotoxic activity of ascorbate. *Anticancer Res* 1997;17:1125–9.
- [19] Rehman A, Collis CS, Yang M, Kelly M, Diplock AT, Halliwell B, et al. The effects of iron and vitamin C co-supplementation on oxidative damage to DNA in healthy volunteers. *Biochem Biophys Res Commun* 1998;246:293–8.
- [20] Kennish L, Attur M, Oh C, Krasnokutsky S, Samuels J, Greenberg JD, et al. Age-dependent ferritin elevations and HFE C282Y mutation as risk factors for symptomatic knee osteoarthritis in males: a longitudinal cohort study. *BMC Musculoskelet Disord* 2014;15:1–9.
- [21] Yazar M, Sarban S, Kocyigit A, Isikan UE. Synovial fluid and plasma selenium, copper, zinc, and iron concentrations in patients with rheumatoid arthritis and osteoarthritis. *Biol Trace Elem Res* 2005;106:123–32.
- [22] Camacho A, Simao M, Ea HK, Cohen-Solal M, Richette P, Branco J, et al. Iron overload in a murine model of hereditary hemochromatosis is associated with accelerated progression of osteoarthritis under mechanical stress. *Osteoarthritis Cartilage* 2016;24:494–s502.
- [23] Hatcher HC, Singh RN, Torti FM, Torti SV. Synthetic and natural iron chelators: therapeutic potential and clinical use. *Future Med Chem* 2009;1:1643–70.
- [24] Naughton DP. Iron(III)-mediated intra-articular crystal deposition in arthritis: a therapeutic role for iron chelators. *Med Hypotheses* 2001;57:120–2.
- [25] Kocaoglu B, Akgun U, Erol B, Karahan M, Yalcin S. Preventing blood-induced joint damage with the use of intra-articular iron chelators: an experimental study in rabbits. *Arch Orthop Trauma Surg* 2009;129:1571–5.
- [26] Fu SC, Cheuk YC, Hung LK, Chan KM. Limb Idleness Index (LII): a novel measurement of pain in a rat model of osteoarthritis. *Osteoarthritis Cartilage* 2012;20:1409–16.
- [27] Pritzker KPH, Gay S, Jimenez SA, Ostergaard K, Pelletier JP, Revell PA, et al. Osteoarthritis cartilage histopathology: grading and staging. *Osteoarthritis Cartilage* 2006;14:13–29.
- [28] McAlindon TE, Bannuru RR, Sullivan MC, Arden NK, Berenbaum F, Bierma-Zeinstra SM, et al. OARSI guidelines for the non-surgical management of knee osteoarthritis. *Osteoarthritis Cartilage* 2014;22:363–88.
- [29] Zhang W, Nuki G, Moskowitz RW, Abramson S, Altman RD, Arden NK, et al. OARSI recommendations for the management of hip and knee osteoarthritis Part III: changes in evidence following systematic cumulative update of research published through January 2009. *Osteoarthritis Cartilage* 2010;18:476–99.
- [30] Bannuru RR, Schmid CH, Kent DM, Vaysbrot EE, Wong JB, McAlindon TE. Comparative effectiveness of pharmacologic interventions for knee osteoarthritis: a systematic review and network meta-analysis. *Ann Intern Med* 2015;162:46–54.
- [31] Fujita S, Arai Y, Nakagawa S, Takahashi KA, Terauchi R, Inoue A, et al. Combined microwave irradiation and intra-articular glutamine administration-induced HSP70 expression therapy prevents cartilage degradation in a rat osteoarthritis model. *J Orthop Res* 2012;30:401–7.
- [32] Larsen C, Ostergaard J, Larsen SW, Jensen H, Jacobsen S, Lindgaard C, et al. Intra-Articular depot formulation principles: role in the management of postoperative pain and arthritic disorders. *J Pharm Sci* 2008;97:4622–54.