



# Magnetic flexible endoscope: a novel platform for diagnostic and therapeutic colonoscopy

Claire A. Landewee, BS,<sup>1</sup> Conchúbhair Winters, MBChB,<sup>2</sup> James Martin, PhD,<sup>3</sup> Joseph Norton, PhD,<sup>3</sup> Simone Calo, PhD,<sup>3</sup> Bruno Scaglioni, PhD,<sup>3</sup> Tamaryn Townley, MEng,<sup>3</sup> Jun Wai Kow, PhD,<sup>3</sup> Pietro Valdastrì, PhD,<sup>3</sup> Venkataraman Subramanian, MD, DM,<sup>2</sup> Keith L. Obstein, MD, MPH<sup>1,4</sup>

Nashville, Tennessee, USA; Leeds, United Kingdom

Colonoscopy is widely performed for direct visualization and therapeutic intervention in the colon. Although colonoscopy is a relatively safe procedure, there are several limitations because of the unintuitive drive mechanism and mechanical design of current conventional colonoscopes (CCs). These include sedation-related events, patient discomfort because of looping, perforation and colonic trauma, long learning curve and training time, variable quality, and endoscopist injury because of poor ergonomics. To overcome these limitations, endoscopy as currently practiced would require a dramatic transformation in both endoscope design and technique used for actuation.

The magnetic flexible endoscope (MFE) was developed to address these limitations as a highly flexible, single-use, robot-assisted, magnetically manipulated endoscope. The MFE is composed of a handheld controller (thumb-operated 4-directional joystick with hydraulic controls for insufflation, irrigation, camera cleaning, and suction and a depressible button for forward motion control added to the chassis), a robot manipulator (Kuka, LBR Med-14 R820, Augsburg, Germany; commercially available and certified for use in clinical settings International Electrotechnical Commission [IEC] 60601-1, IEC 60601-2, and IEC 62304) with a magnetic end effector, and a magnetic flexible endoscope to maintain the functionality of a CC (Fig. 1).

The robotic arm is unlike the CC, which is pushed for advancement; the MFE is driven by magnetic coupling to enable a “front-pull” actuation mechanism (Fig. 2). The forward-drive mechanism prevents buckling of the insertion tube, looping, and colonic wall stress, reducing the risk of perforation and pain during the procedure. The positioning of the robotic arm is the result of a complex 3-dimensional model of the magnetic fields generated by the 2 magnets and their interaction. A patented algorithm allows for the localization of the endoscope and consequently computes the desired robot motion. Therefore, the robotic arm does not need to be positioned directly in line with the desired direction to move the endoscope tip, making it possible to move the tip in all directions by moving and rotating the arm around the patient.

Although the arm is generally above the patient, it is possible to tilt the endoscope tip away from the magnet if needed, by taking advantage of the magnetic repulsion. To avoid constant pulling of the magnets with respect to one another, the magnets are in a relative configuration such that the external magnet north pole is directed toward the endoscope tip, whereas the internal magnet is orientated in the opposite direction. With this arrangement, rotations on the external magnet cause opposite rotations on the endoscope tip, and therefore the endoscope is stabilized by active control of the magnetic link with the robotic arm.


With the integration of robotic assistance and autonomous function, the challenging task of endoscope navigation becomes simplified. In vivo validation of colonic navigation for diagnostic and therapeutic colonoscopy is now tested.

## METHODS

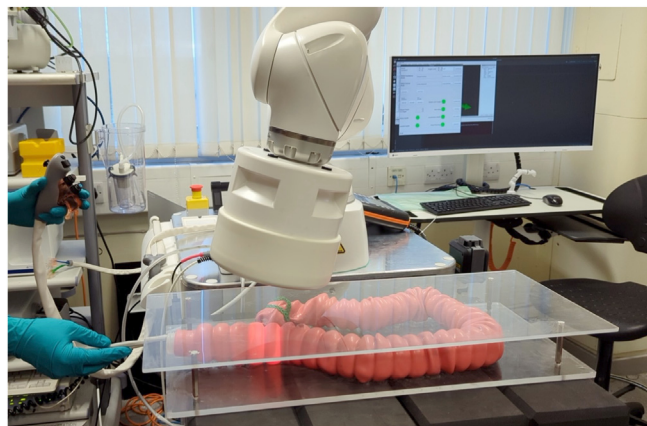The MFE was tested in vivo using two 37-kg female, Danish Duroc, large white-Landrace cross-swine to evaluate system safety, core functionality, navigation, and capacity for therapeutic intervention. The primary outcome measure was safety (trauma or premature demise). The MFE was navigated through the colon and withdrawn 5 times. Autonomous navigation and endoscopic maneuvers, retroflexion, biopsy sampling, and EMR were performed (Fig. 3).

## RESULTS

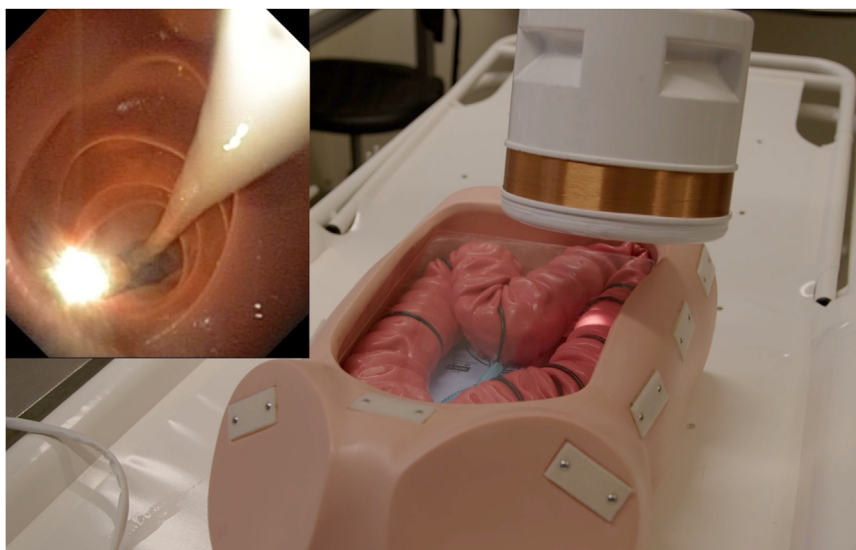The MFE successfully and safely navigated the swine colon with good visibility and without gross colonic trauma. Autonomous navigation of the MFE was successful at autonomously detecting the lumen center and orienting the endoscope for biopsy sampling (Figs. 4 and 5). The detection algorithm tracked the target location, whereas the motion control software aligned the endoscope tip with the biopsy forceps for tissue acquisition (Fig. 6). During all EMR trials, the MFE system maintained hardware integrity and camera visualization, without submucosal trauma or perforation (Fig. 7).



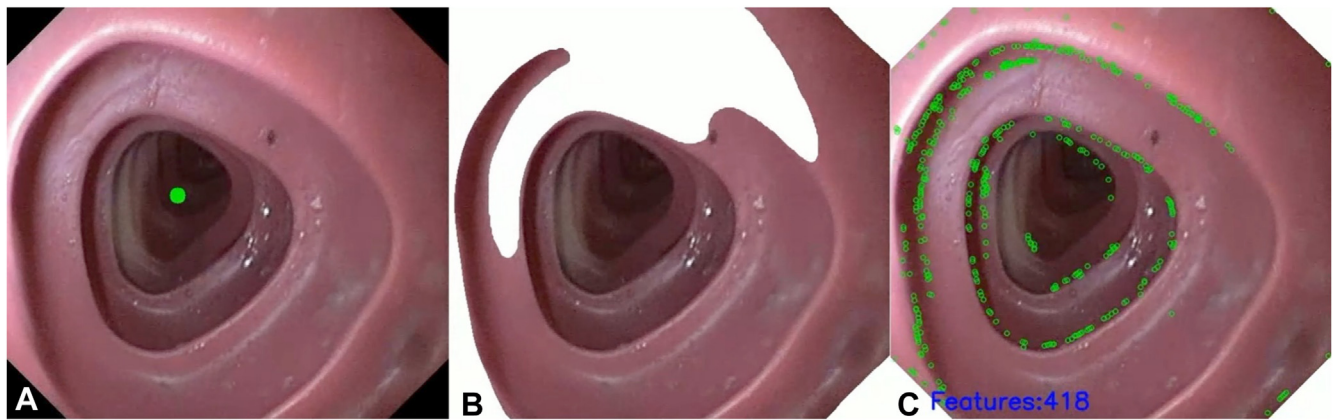
**Figure 1.** The magnetic flexible endoscope (MFE) maintains the same functionality as a conventional colonoscope with camera, illumination, insufflation and lens cleaning, therapeutic working channel, and irrigation; additionally, the MFE has an embedded permanent magnet at the head (*yellow arrow*).



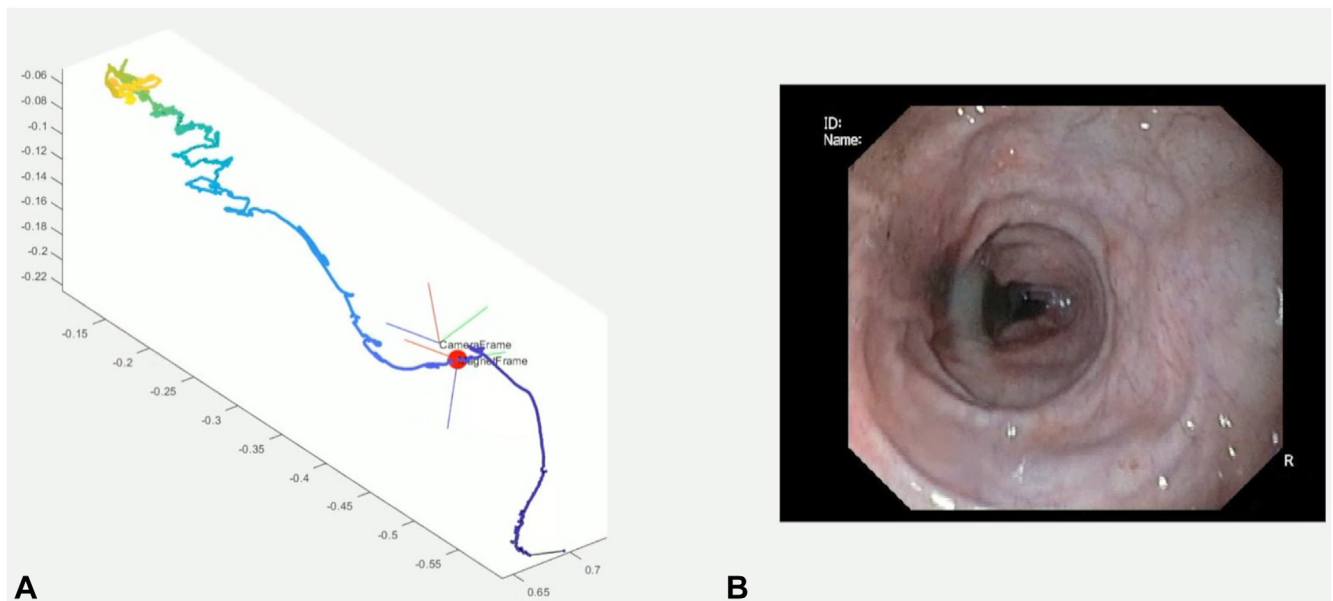
**Figure 2.** The magnetic flexible endoscope is driven by magnetic coupling of the endoscope head to an external permanent magnet held by a robotic arm. This enables a “front-pull” actuation mechanism that eliminates the need to push a semirigid insertion tube for colonoscope advancement.



**Figure 3.** Through extensive benchtop evaluation, the magnetic flexible endoscope has demonstrated robust reliability of system hardware and software, allowing for intuitive drive and easy navigation, including achievement of autonomous retroflexion in a colon phantom (Kyoto Kagaku M40, Kyoto, Japan).



**Figure 4.** The magnetic flexible endoscope has successfully performed autonomous navigation using artificial intelligence in a colon phantom using (A) lumen tracking, (B) an image segmentation algorithm, and (C) colonic feature detection.



**Figure 5. A,** The magnetic flexible endoscope platform actively controls the endoscope tip through 3-dimensional magnetic field sensing and manipulation. **B,** The pathway traveled can then be graphed to allow for the creation of a colon map with image reconstruction.

Three-dimensional magnetic field sensing and manipulation were also successful (Video 1).

## DISCUSSION

The MFE is a novel platform capable of diagnostic and therapeutic colonoscopy, as demonstrated through bench-top evaluation and in vivo swine trials. No gross trauma, perforation, or adverse events occurred. The MFE platform functioned well, and preparations for first-in-human in vivo trials are underway.

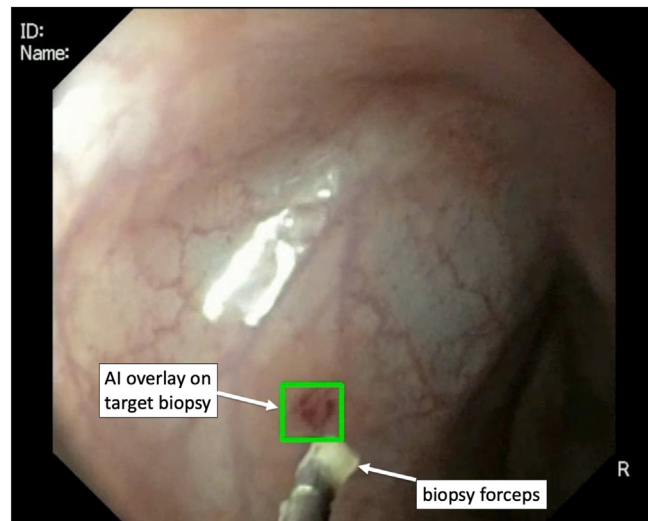
## DISCLOSURE

The following authors disclosed financial relationships: J. Norton, B. Scaglioni, P. Valdastrì: Research support from Atlas Endoscopy. K. L. Obstein: Consultant for Atlas Endoscopy. All other authors disclosed no financial relationships.

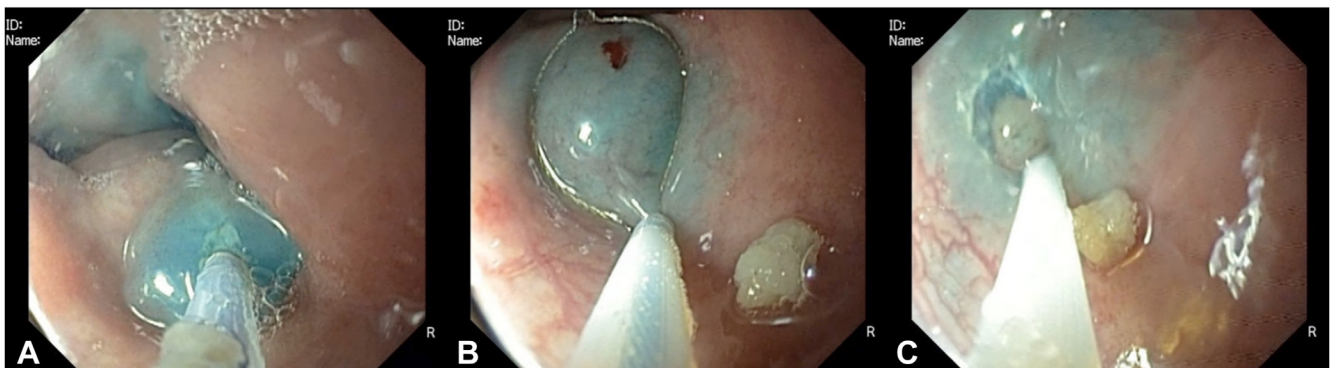
## ACKNOWLEDGMENTS

Research support for this study was provided by the National Institute of Biomedical Imaging and Bioengineering of the National Institutes of Health (award no. 2R01EB018992)





**Figure 6.** To demonstrate biopsy sampling using the magnetic flexible endoscope (MFE), a suction mark was created on the lumen wall, and the MFE was able to successfully take biopsy samples with cold forceps. Additionally, this maneuver was conducted semi-autonomously and with an AI overlay (*green box*) that follows the biopsy target. The detection algorithm tracks target location, whereas motion control software “locks-in” on the lesion and steers the endoscope tip to align with the predicted path of the biopsy forceps. Once the operator is satisfied that the endoscope tip is aligned, the forceps is introduced and a biopsy sample taken. *AI*, Artificial intelligence.



**Figure 7.** During in vivo swine trials, 6 EMRs were successfully performed using the magnetic flexible endoscope (MFE). **A**, After marking the site, the lesion was lifted with a submucosal injectable composition. **B**, A snare was inserted. **C**, Snare cautery was used to remove the lesion. Throughout all EMR trials, the MFE system maintained hardware integrity with intact camera visualization and no adverse events.

and by Cancer Research UK Early Detection and Diagnosis Research Committee (grant no. 27744).

*Abbreviations: CC, conventional colonoscopy; IEC, International Electrotechnical Commission; MFE, magnetic flexible endoscope.*

© 2023 American Society for Gastrointestinal Endoscopy. Published by Elsevier Inc. This is an open access article under the CC BY-NC-ND license (<http://creativecommons.org/licenses/by-nc-nd/4.0/>).

<https://doi.org/10.1016/j.igie.2023.11.011>

Received September 9, 2023. Accepted November 26, 2023.

Current affiliations: STORM Lab USA, Vanderbilt Institute for Surgery and Engineering, Vanderbilt University, Nashville, Tennessee, USA (1), Division of Gastroenterology, Leeds Teaching Hospitals NHS Trust, St James’s University Hospital, Leeds, UK (2), STORM Lab UK, School of Electronic and Electrical Engineering, University of Leeds, Leeds, UK (3), Division of Gastroenterology, Vanderbilt University Medical Center, Nashville, Tennessee, USA (4).

Reprint requests: Keith Obstein, MD, MPH, FASGE, Vanderbilt University Medical Center, 1301 Medical Center Dr, Ste 1660, The Vanderbilt Clinic, Nashville, TN 37232.