

Received: 2018.06.26
Accepted: 2018.08.17
Published: 2018.11.12

Chronic Hyponatremia Due to the Syndrome of Inappropriate Antidiuresis (SIAD) in an Adult Woman with Corpus Callosum Agenesis (CCA)

Authors' Contribution:
Study Design A
Data Collection B
Statistical Analysis C
Data Interpretation D
Manuscript Preparation E
Literature Search F
Funds Collection G

ABE **Marcelo Augusto Duarte Silveira**
EF **Antônio Carlos Seguro**
BE **Jukelson Barbosa da Silva**
E **Marcia Fernanda Arantes de Oliveira**
F **Victor Faria Seabra**
E **Bernardo Vergara Reichert**
F **Camila Eleutério Rodrigues**
EF **Lucia Andrade**

Department of Nephrology, University of São Paulo, School of Medicine, São Paulo, SP Brazil

Corresponding Author: Marcelo Augusto Duarte Silveira, e-mail: marceloadsilveira@gmail.com
Conflict of interest: None declared

Patient: Female, 41
Final Diagnosis: Syndrome of inappropriate antidiuresis
Symptoms: Gait disturbance
Medication: —
Clinical Procedure: Treatment of chronic hyponatremia
Specialty: Nephrology

Objective: Rare co-existence of disease or pathology


Background: Corpus callosum agenesis (CCA) is one of the most common congenital brain abnormalities, and is associated with neurodevelopmental and neuropsychiatric disorders. In CCA, defects in osmoregulation have been reported. This report presents a rare case of chronic hyponatremia associated with the syndrome of inappropriate antidiuresis (SIAD) in a woman with CCA.

Case Report: A 41-year-old woman presented to the renal unit with symptomatic hyponatremia. In her past medical history, she had a four-year history of systemic arterial hypertension and Sjögren's syndrome, and a three-year history of systemic lupus erythematosus (SLE), which was treated with cyclophosphamide. She had CCA but with irregular neurological follow-up. During the previous eight years, her plasma sodium levels ranged from between 118–134 mEq/L. On this hospital admission, she had plasma hypo-osmolality, measured in milli-osmoles per kilogram of H₂O (mOsm/kg H₂O), of 251 mOsm/Kg H₂O, and a urinary hyper-osmolality of 545 mOsm/Kg H₂O, and increased level of plasma antidiuretic hormone (ADH) (1.8 pg/ml). Bone densitometry was consistent with osteoporosis. The patient remained asymptomatic during her hospital stay. Chronic hyponatremia associated with the SIAD was diagnosed. Water restriction and increased protein intake resulted in a partial improvement in the serum sodium level (128–134 mEq/L). The patient was discharged from the hospital with outpatient follow-up.

Conclusions: A rare case of chronic hyponatremia due to the SIAD associated with CCA is reported that demonstrates the importance of correct diagnosis, management, and clinical follow-up of the SIAD, including bone densitometry.

MeSH Keywords: Agenesis of Corpus Callosum • Hyponatremia • Inappropriate ADH Syndrome

Full-text PDF: <https://www.amjcaserep.com/abstract/index/idArt/911810>

 1622

 1

 2

 24



Background

The corpus callosum is the largest cerebral commissure and one of the major connective pathways of the interhemispheric white matter in the central nervous system (CNS). Corpus callosum agenesis (CCA) is one of the most common congenital brain abnormalities and is a disorder of prosencephalic midline development [1,2]. CCA may have few presenting symptoms but can be associated with retarded neurodevelopment and with visual, endocrine disorders, and with several neuropsychological disorders [3].

In patients with CCA, there have been previous reports of abnormal CNS osmoregulation, including hypernatremia due to central diabetes insipidus [4,5]. However, there have been few reported cases of hyponatremia due to the syndrome of inappropriate antidiuresis (SIAD) in patients with CCA, and no previous case has been described in an adult [6–8].

In clinical practice, hyponatremia is a commonly diagnosed electrolyte disturbance that is associated with a change in the water balance of body, or hypo-osmolality, and if untreated can result in patient morbidity and mortality [9–11]. Chronic hyponatremia may be associated with neurological symptoms, including attention deficit, impaired mobility with an increased risk of falls, cognitive deficit, sarcopenia, and reduction in bone mass with increased risk of bone fracture [12–14].

The syndrome of inappropriate antidiuresis (SIAD) is one of the most frequent causes of hyponatremia, with a reported prevalence in hospital patients of up to 35% of cases [11]. The diagnosis of hyponatremia can be made by laboratory investigations, but can be associated with a variety of clinical features including hyponatremia with associated normovolemia, plasma hypo-osmolality with associated urinary dilution deficit (or urinary hyper-osmolality) in the absence of renal disease, and possible elevated levels of antidiuretic hormone (ADH), which can be measured in the plasma [10].

The purpose of this report is to demonstrate a rare combination of chronic hyponatremia secondary to the SIAD in an adult patient with CCA who, due to the chronicity of the clinical history, was also associated with osteopenia. Hyponatremia was accompanied by plasma hypo-osmolality, euvoolemia, a reduced urinary dilution capacity, and increased plasma levels of ADH. This report demonstrates the importance of correct diagnosis, management, and clinical follow-up of patients with the SIAD, including bone densitometry.

Case Report

In January 2018, a 41-year-old woman presented with paresthesia in her right hand and was admitted to hospital

for further investigations. In her past medical history, she had a four-year history of systemic arterial hypertension and Sjögren's syndrome, and a three-year history of systemic lupus erythematosus (SLE), which was treated with cyclophosphamide until June 2017 (cumulative dose, 13.5 g). During the previous eight years (since 2010), her plasma sodium levels ranged from between 118–134 mEq/L. The patient was previously diagnosed with corpus callosum agenesis (CCA) but had undergone irregular clinical neurology follow-up. Her CCA was associated with some difficulty in mobility, including a gait disorder, but with no other apparent neurological deficits. Her regular medications included enalapril, but she had never been treated with hydrochlorothiazide.

Before the diagnosis of Sjögren's syndrome, bone density testing resulted in a T-test of L1/L4 and the femoral neck of between –1.1 to –2.4, indicating osteopenia (T-test: –1 and above, normal; between –1 and –2.5, osteopenia; –2.5 and below, osteoporosis). Following corticosteroid (prednisone) treatment for Sjögren's syndrome, her bone densitometry T-test was less than –2.5, indicating osteoporosis.

On this hospital admission, there was no evidence of infectious disease, no underlying malignancy was suspected, and radiography and computed tomography (CT) imaging of the thorax were normal. Skull tomography and magnetic resonance imaging (MRI) showed that there was no evidence of neurological injury or ischemic events, and while in hospital, her symptoms resolved. Her blood pressure was normal and there were no signs of hypovolemia. However, initial laboratory investigations showed hyponatremia, and she was referred to the Department of Nephrology, University of São Paulo School of Medicine, where hydration was commenced with 0.9% sodium chloride, but without improvement of her hyponatremia.

On the current hospital admission, further laboratory results were as follows: plasma sodium (pNa^+), 117 mEq/L; urinary sodium, (uNa^+) 122 mEq/L; plasma potassium (pK^+); urinary potassium (uK^+), 31 mEq/L; urea, 23 mg/dl; creatinine, 59 mg/dl; uric acid, 2.2 mg/dl; glucose, 96 mg/dl; thyroid stimulating hormone (TSH), 1.06 μ U/ml; cortisol, 10.5 μ g/dl; plasma osmolality ($Posm$), 251 mOsm/kg H_2O ; urine osmolality ($Uosm$), 545 mOsm/kg H_2O ; antidiuretic hormone (ADH), 1.8 pg/ml; 25-hydroxy-vitamin D, 17 ng/ml; free water clearance, 1,170 ml/day (according to the formula: $Cl\ H_2O=V [1 - Uosm/Posm]$, where 'V' is the urinary volume, which was 1,000 ml on the day of the evaluation); electrolyte-free water clearance, 308 ml/day (according to the formula: $eCl\ H_2O=V [1 - uNa^+ + uK^+/pNa^+]$, where 'V' is the urinary volume, which was 1,000 ml on the day of the evaluation); and the fractional excretion of sodium ($FENa^+$), 1.2% (according to the formula: $FENa^+=(uNa^+/pNa^+/uCr/pCr)\times 100$ (Table 1).

Table 1. Results of laboratory investigations in a 41-year old woman with corpus callosum agenesis (CCA) and the syndrome of inappropriate antidiuresis (SIAD).

Blood	Laboratory values (normal range)		Urinary characteristics	Value
Creatinine, mg/dl	0.7	(0.5–0.9)	Urinary volume, ml/day	1000
Urea, mg/dl	23	(10–50)	Osmolality, mOsm/kg H ₂ O	545
Sodium, mEq/L	117	(135–145)	Sodium, mEq/L	122
Potassium, mEq/L	3.8	(3.5–5.0)	Potassium, mEq/L	31
Uric acid, mg/dl	2.2	(2.4–5.7)	Creatinine, mg/dl	59
Glucose, mg/dl	113	(70–99)	Free water clearance, ml/day	–1170
Total calcium, mg/dl	8.3	(8.4–10.2)	eFree water clearance, ml/day	–308
Phosphorus, mg/dl	3.0	(2.7–4.5)	FENa+, %	1.2
Albumin, g/dl	3.5	(3.2–4.5)		
25(OH)D, ng/ml	17	(25–86.5)		
PTH, pg/ml	38	(15–65)		
TSH, µU/ml	1.06	(0.27–4.20)		
Cortisol, µg/dl	10.5	(6.7–22.6)		
Osmolality, mOsm/kg H ₂ O	251	(275–295)		
ADH, pg/ml	1.8	(1.0–13.3)		

ADH – antidiuretic hormone; eFree – electrolyte-free; FENa⁺ – fractional excretion of sodium; PTH – parathyroid hormone; TSH – thyroid stimulating hormone; 25(OH)D – 5-hydroxy-vitamin D.

The patient remained asymptomatic throughout the hospital stay. After water restriction and increased protein intake, there was a partial improvement in serum sodium levels (between 128–134 mEq/L), and the patient was discharged for outpatient follow-up. She continues to be followed-up as an outpatient. A palatable form of oral urea ('Brussels Champagne') was added once a day to maintain sodium levels between 131–136 mEq/L. The ADH levels in this patient and MRI imaging of the CCA are shown in Figures 1 and 2, respectively.

Discussion

The syndrome of inappropriate antidiuresis (SIAD) is one of the leading causes of hyponatremia, but the association with corpus callosum agenesis (CCA) has been rarely reported [11]. SIAD is a diagnosis of exclusion and presents with clinical features that include clinical euvoemia, plasma hyponatremia, and urinary hyponatremia in the absence of identified renal disease [10]. These clinical features were present in this report of a woman with the SIAD associated with CCA.

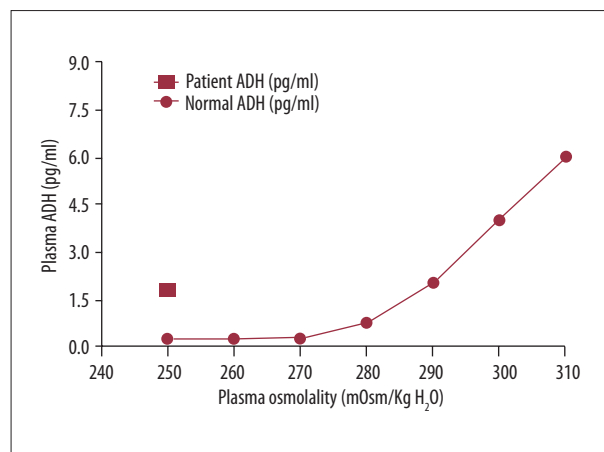


Figure 1. Normal antidiuretic hormone (ADH) levels compared with the ADH levels in a 41-year old woman with corpus callosum agenesis (CCA) and the syndrome of inappropriate antidiuresis (SIAD) during her clinical course. Modified from Robertson et al. [24].

Alterations in the central osmoregulatory system have been described in patients with CCA, but not in cases of polyuria and hyponatremia [4]. The patient described in this case had

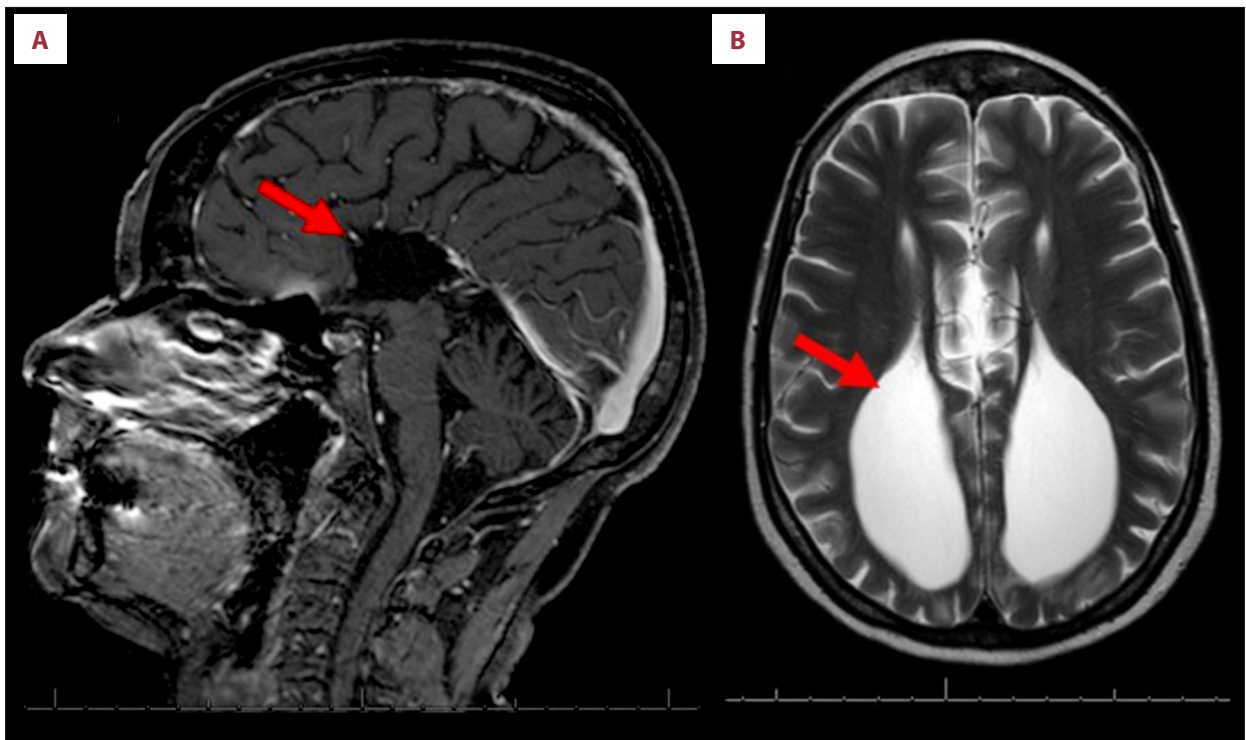


Figure 2. Magnetic resonance imaging (MRI) showing corpus callosum agenesis (CCA) in a 41-year old woman. (A) The absence of a corpus callosum (arrow) demonstrated on sagittal magnetic resonance imaging (MRI). (B) Hydrocephalus with colpocephaly (congenital enlargement of the posterior lateral ventricles or occipital horns, because the posterior cerebral white matter has failed to develop) (arrow) demonstrated on coronal MRI.

an unusual presentation that might be explained by a change in the central osmoregulatory system, with an abnormally low osmotic threshold following the release of antidiuretic hormone (ADH), as this patient presented with serum hypo-osmolality and a considerably increased plasma level of ADH.

Due to alterations in the central nervous system (CNS) in CCA, one of the differential diagnoses of the SIAD is salt wasting, which is associated with hypovolemia and can respond to saline infusion [15]. However, in this case, the patient did not respond to saline infusion. The patient's history of Sjögren's syndrome and past use of prednisone could have resulted in adrenal insufficiency, but she did not present with hyperkalemia, hypotension, or reduced levels of cortisol [11].

This patient also had a three-year history of systemic lupus erythematosus (SLE), which was treated with cyclophosphamide, which is an alkylating agent used in the treatment of malignant and autoimmune disease. Hyponatremia due to the SIAD has previously been reported as an adverse effect of cyclophosphamide treatment [16]. However, before the patient received cyclophosphamide treatment, she already had hyponatremia. The use of medications potentially related to the SIAD may be contributing factors to the chronicity of hyponatremia and should be identified, if possible.

Varying degrees of neurological changes accompany CCA, ranging from attention deficit, gait disturbances, and language disorders to neuro-psychomotor developmental disorders and epilepsy [3,17]. Chronic hyponatremia is also associated with a variety of clinical complications and is associated with increased mortality [12–14]. It is likely that the association with CCA and the SIAD in this case were aggravating factors.

Chronic hyponatremia may lead to a reduction in bone mass. ADH receptors are expressed in both osteoclasts and osteoblasts [18,19]. It has previously been shown that ADH plays a role in the remodeling of bone tissue by influencing the suppression of bone formation and stimulating of the reabsorption of bone tissue [19]. The present case described a young woman who had not yet entered menopause and who presented with osteopenia. She had hypovitaminosis D and a history of corticosteroid treatment, which are factors that also aggravate bone disease, which may explain the presence of osteoporosis in subsequent bone densitometry.

Several strategies exist for the treatment of chronic hyponatremia. In general, the initial treatment for chronic asymptomatic cases involves the restriction of water, based on urinary volume [10,20,21]. For patients who are chronically affected by the SIAD, most have an intact thirst center and naturally

already have reduced water intake. However, as not all patients can regulate their fluid intake, laboratory investigations and monitoring should be performed for all patients with the SIAD.

Increased protein intake and the administration of oral urea can be effective and increase the elimination of free water in the urine [21–23]. However, the use of oral urea is unpalatable and can be poorly tolerated by patients. Consequently, urea is sometimes administered using a formulation called ‘Brussels Champagne,’ which consisting of the following: urea, 10 g; sodium bicarbonate, 2 g; citric acid, 1.5 g; and sucrose, 200 mg [9]. This palatable form of oral urea can be diluted in 50–100 ml of water and administered between one to three times per day, as clinically indicated.

Following modification of water intake and restriction and an increase in protein intake, the patient in this report showed partial improvement in sodium levels during hospitalization and was subsequently discharged from hospital. The patient

continues to be followed-up and to maintain her sodium levels between 131–136 mEq/L.

Conclusions

Chronic hyponatremia associated with corpus callosum agenesis (CCA) is a rare condition, and the association with the syndrome of inappropriate antidiuresis (SIAD) is even rarer. Chronic hyponatremia results in harmful clinical consequences, including osteopenia and osteoporosis. Correct identification and clinical follow-up, including bone densitometry, and correction of hyponatremia are essential to minimize the clinical complications.

Conflicts of interest

None.

References:

1. Paul LK, Brown WS, Adolphs R et al: Agenesis of the corpus callosum: Genetic, developmental and functional aspects of connectivity. *Nat Rev Neurosci*, 2007; 8(4): 287–99
2. Glass HC, Shaw GM, Ma C, Sherr EH: Agenesis of the corpus callosum in California 1983–2003: A population-based study. *Am J Med Genet A*, 2008; 146A(19): 2495–500
3. Palmer EE, Mowat D: Agenesis of the corpus callosum: A clinical approach to diagnosis. *Am J Med Genet C Semin Med Genet*, 2014; 166C(2): 184–97
4. Masera N, Grant DB, Stanhope R, Preece MA: Diabetes insipidus with impaired osmotic regulation in septo-optic dysplasia and agenesis of the corpus callosum. *Arch Dis Child*, 1994; 70(1): 51–53
5. Raisingani M, Palliyil Gopi R, Shah B: Use of chlorothiazide in the management of central diabetes insipidus in early infancy. *Case Rep Pediatr*, 2017; 2017: 2407028
6. Cizmeci MN, Kanburuglu MK, Akelma AZ et al: Syndrome of inappropriate antidiuretic hormone secretion refractory to treatment in a newborn with alobar holoprosencephaly. *Genet Couns*, 2013; 24(3): 313–18
7. Bannister P, Sheridan P, Penney MD: Chronic reset osmoreceptor response, agenesis of the corpus callosum, and hypothalamic cyst. *J Pediatr*, 1984; 104(1): 97–99
8. Gupta P, Mick G, Fong CT et al: Hyponatremia secondary to reset osmostat in a child with a central nervous system midline defect and a chromosomal abnormality. *J Pediatr Endocrinol Metab*, 2000; 13(9): 1637–41
9. Berl T: Vasopressin antagonists. *N Engl J Med*, 2015; 372: 2207–16
10. Ellison DH, Berl T: Clinical practice. The syndrome of inappropriate antidiuresis. *N Engl J Med*, 2007; 356(20): 2064–72
11. Esposito P, Piotti G, Bianzina S et al: The syndrome of inappropriate antidiuresis: Pathophysiology, clinical management and new therapeutic options. *Nephron Clin Pract*. 2011; 119(1): c62–73
12. Usala RL, Fernandez SJ, Mete M et al: Hyponatremia is associated with increased osteoporosis and bone fractures in a large US health system population. *J Clin Endocrinol Metab*, 2015; 100(8): 3021–31
13. Barsony J, Manigrasso MB, Xu Q et al: Chronic hyponatremia exacerbates multiple manifestations of senescence in male rats. *Age (Dordr)*, 2013; 35(2): 271–88
14. Fujisawa H, Sugimura Y, Takagi H et al: Chronic hyponatremia causes neurologic and psychologic impairments. *J Am Soc Nephrol*, 2016; 27(3): 766–80
15. Rivkees SA: Differentiating appropriate antidiuretic hormone secretion, inappropriate antidiuretic hormone secretion and cerebral salt wasting: The common, uncommon, and misnamed. *Curr Opin Pediatr*, 2008; 20(4): 448–52
16. Esposito P, Domenech MV, Serpieri N et al: Severe cyclophosphamide-related hyponatremia in a patient with acute glomerulonephritis. *World J Nephrol*, 2017; 6(4): 217–20
17. D’Antonio F, Pagani G, Familiari A et al: Outcomes associated with isolated agenesis of the corpus callosum: A meta-analysis. *Pediatrics*, 2016; 138(3): pii: e20160445
18. Verbalis JG, Barsony J, Sugimura Y et al: Hyponatremia-induced osteoporosis. *J Bone Miner Res*, 2010; 25(3): 554–63
19. Tamma R, Sun L, Cuscito C et al: Regulation of bone remodeling by vasopressin explains the bone loss in hyponatremia. *Proc Natl Acad Sci USA*, 2013; 110(46): 18644–49
20. Thurman JM, Halterman TJ, Berl T: Therapy of dysnatremic disorders. In: Brady HR, Wilcox CS (eds.), *Therapy in nephrology and hypertension: A companion to Brenner & Rector’s The Kidney*. 2nd ed. London: Saunders, 2003; 335–48
21. Moritz ML, Ayus JC: Management of hyponatremia in various clinical situations. *Curr Treat Options Neurol*, 2014; 16: 310
22. Berl T: Impact of solute intake on urine flow and water excretion. *J Am Soc Nephrol*, 2008; 19(6): 1076–78
23. Soupart A, Coffernils M, Couturier B et al: Efficacy and tolerance of urea compared with vaptans for long-term treatment of patients with SIADH. *Clin J Am Soc Nephrol*, 2012; 7(5): 742–47
24. Robertson GL, Aycinena P, Zerbe RL: Neurogenic disorders of osmoregulation. *Am J Med*, 1982; 72: 339