

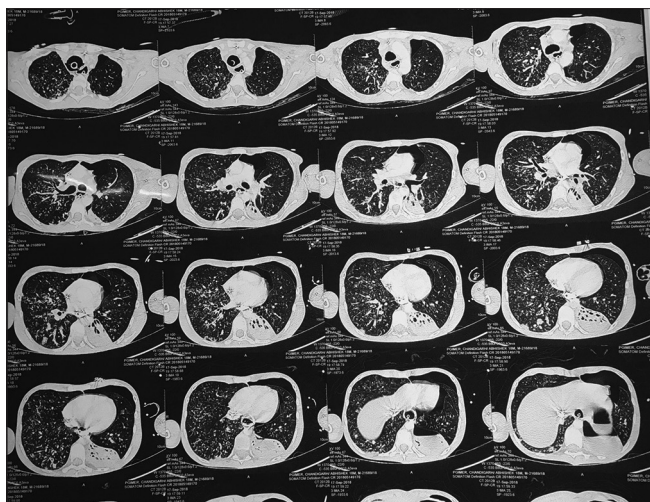## A rare case of tracheoesophageal fistula and pneumothorax occurring simultaneously in a patient following percutaneous dilatational tracheostomy

Dear Editor,

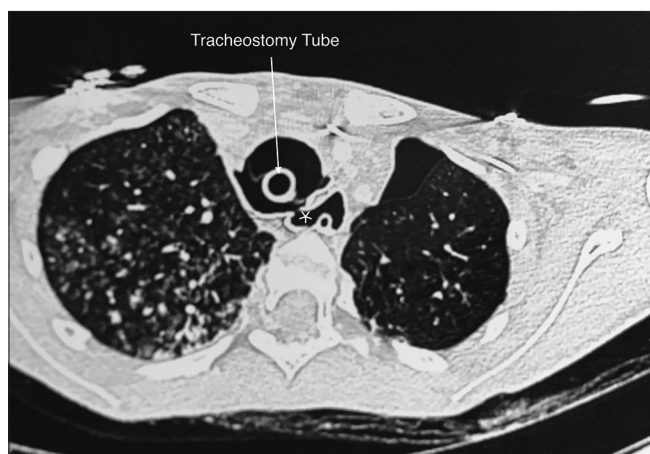We report a case of refractory status epilepticus who developed bilateral pneumothorax and tracheoesophageal fistula following percutaneous dilatational tracheostomy (PDT). This report highlights the hazards of a procedure that is conducted worldwide and considered safe.

A 16-year-old patient, with history of refractory status epilepticus on multiple intravenous antiepileptics, was admitted to our ICU for control of seizures and elective mechanical ventilation. Anticipating prolonged mechanical ventilation, on day 9 of ICU stay, decision to do a percutaneous dilatational technique (PDT) was taken after written and informed consent. Griggs technique of PDT under bronchoscopic guidance was planned. After adequate muscle relaxation and analgesia, bronchoscope of size 5.5 (Olympus medical systems, Tokyo, Japan) was inserted through the 7.0 mm ID endotracheal tube (ETT) and ETT was withdrawn upto the level of the vocal cords. After skin incision, blunt dissection of subcutaneous tissue was done till trachea could be palpated.

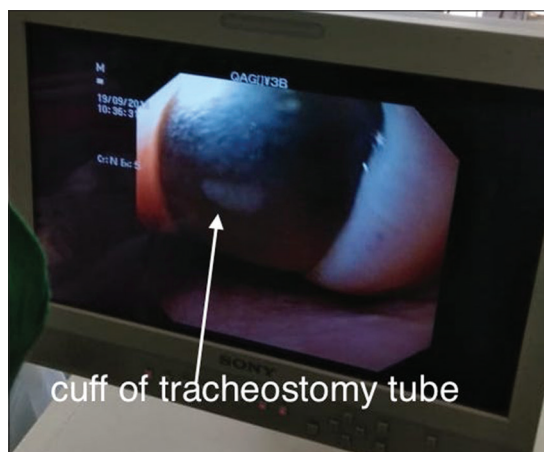
Introducer needle with a plastic sheath of the PORTEX® GRIGGS® percutaneous dilatation tracheostomy kit (Smiths Medical, Minneapolis, Minnesota) was introduced into the trachea under direct bronchoscopic vision. Metal guidewire was threaded into the trachea through the plastic sheath, which was then removed. The Griggs guidewire dilating forceps was introduced through the metal guidewire and the trachea was dilated in two perpendicular directions. During the dilatation, bleeding into the trachea was encountered. The bronchoscopic view was completely obliterated by the bleed from the tracheal mucosa. As a stoma had been formed, a 7.0 mm cuffed tracheostomy tube (TT) was threaded over the guidewire and secured with tape. Endotracheal suction and bronchoscopy confirmed position of tracheostomy tube. Thereafter, the oxygen requirement and peak airway pressures increased. Urgent bedside chest X-ray and ultrasound revealed a right pneumothorax. An intercostal drain was inserted and ventilatory parameters improved. Appropriate care of the TT including 8 hourly cuff pressure monitoring, 2 hourly cuff deflation was undertaken. However, on day 4 of PDT, gastric contents were noted in TT, followed by an increase in peak airway pressures, decrease in PaO<sub>2</sub>/FiO<sub>2</sub> ratio. Chest X-ray (CXR) revealed features of aspiration pneumonia. CT scan of the neck and thorax showed a tracheoesophageal fistula (TEF) just underneath the cuff of TT and pneumothorax on the left side [Figures 1 and 2] which was missed on the immediate post PDT supine CXR because of the anterior and apical location of the trapped air. Esophagoscopy revealed a 4 cm long linear tear in the posterior tracheal wall with free communication between the esophagus and trachea [Figure 3]. An esophageal stent placement was



**Figure 1:** Axial CT scan image of the thorax showing pneumothorax



**Figure 2:** Axial CT image of the thorax showing the presence of a communication between trachea and esophagus (marked\*)



**Figure 3:** Trachea-Esophageal fistula seen on esophagoscopy

planned. However, the patient succumbed to severe ARDS secondary to aspiration pneumonia.

PDT is a technique of choice for tracheostomy in ICU.<sup>[1]</sup> Mortality from PDT is extremely rare. In the

largest systematic review of death after PDT, the mortality rate was found to be 2.18%. The major cause of death was hemorrhage (38%) followed by airway complication (29%) like dislocation of the tracheal cannula, lost airway during procedure. Pneumothorax caused death in only 4 cases out of 24,307 PDT conducted. No incidence of tracheoesophageal fistula (TEF) was reported.<sup>[2]</sup> Dennis *et al.*<sup>[3]</sup> reported no case of tracheoesophageal fistula among 3,162 bedside PDTs using the Blue Rhino™ technique (Cook Medical, Bloomington, Indiana). Karimpour *et al.*<sup>[4]</sup> found an incidence of 1.2% of tracheoesophageal fistula using Griggs technique.

The modified Seldinger technique of PDT under bronchoscopic guidance reduces complication due to blind placement of tracheostomy tube. A study comparing PDT with or without bronchoscopy showed that bronchoscopy decreased incidence of complications.<sup>[5]</sup> In our case, bronchoscope was used but excessive bleeding obscured the view when trachea was dilated using Grigg's forceps, causing damage to the posterior tracheal wall, resulting in pneumothorax and tracheoesophageal fistula.

Amount of force applied for tracheal dilation is ambiguous. Harayan *et al.* reported 2 cases of tracheal rupture where authors suspected excessive force during tracheal dilatation caused the catastrophe.<sup>[6]</sup> Low placement of tracheostomy stoma may also have contributed to the creation of pneumothorax and TEF in our patient.

Though rate of complications following PDT is low, clinician must use all safety measures. Avoiding blind manipulation of the airway, refraining from the use of excessive force while dilating the trachea, use of bronchoscope are some of the ways to avoid catastrophic outcomes during PDT. If a complication is suspected, prompt and detailed radiological and endoscopic evaluation is mandatory.

### Declaration of patient consent

The authors certify that they have obtained all appropriate patient consent forms. In the form, the guardian has given his consent for patient's images and other clinical information to be reported in the journal. The guardian understands that patient's names and initials will not be published and due efforts will be made to conceal identity, but anonymity cannot be guaranteed.

### Financial support and sponsorship

Nil.

### Conflicts of interest

There are no conflicts of interest.

**Karan Singla, Kamal Kajal, Neha Chauhan,  
Sunita Kajal<sup>1</sup>, Vikas Saini**

Department of Anesthesia and Intensive Care, PGIMER, Chandigarh,  
<sup>1</sup>Sri Guru Harkrishan Sahib Hospital, Sohana, Punjab, India

**Address for correspondence:** Dr. Kamal Kajal,  
Department of Anesthesia and Intensive Care,  
PGIMER, Chandigarh, India.  
E-mail: kamal.kajal@gmail.com

## References

1. Freeman BD, Morris PE. Tracheostomy practice in adults with acute respiratory failure. *Crit Care Med* 2012;40:2890-96.
2. Simon M, Metschke M, Braune SA, Puschel K, Kluge S. Death after percutaneous dilatational tracheostomy: A systematic review and analysis of risk factors. *Critical Care* 2013;17:R258.
3. Dennis BM, Eckert MJ, Gunter OL, Morris JA, May AK. Safety of bedside percutaneous tracheostomy in the critically ill: Evaluation of more than 3,000 procedures. *J Am Coll Surg* 2013;216:858-67.
4. Karimpour HA, Vafali K, Chalechale M, Mohammadi S, Kaviannezhad R. Percutaneous dilatational tracheostomy via Griggs technique. *Arch Iran Med* 2017;20:49-54.
5. Kost KM. Endoscopic percutaneous dilational tracheostomy: A prospective evaluation of 500 consecutive cases. *Laryngoscope* 2005;115:1-30.

6. Hayaran N, Tanwar S, Singh R, Sardana R. *J Clin Anesth* 2019;52:51-2.

This is an open access journal, and articles are distributed under the terms of the Creative Commons Attribution-NonCommercial-ShareAlike 4.0 License, which allows others to remix, tweak, and build upon the work non-commercially, as long as appropriate credit is given and the new creations are licensed under the identical terms.

Access this article online	
<b>Quick Response Code:</b>	<b>Website:</b> www.joacp.org
	<b>DOI:</b> 10.4103/joacp.JOACP_98_19

**How to cite this article:** Singla K, Kajal K, Chauhan N, Kajal S, Saini V. A rare case of tracheoesophageal fistula and pneumothorax occurring simultaneously in a patient following percutaneous dilatational tracheostomy. *J Anaesthesiol Clin Pharmacol* 2021;37:127-9.

**Submitted:** 08-Apr-2019 **Revised:** 30-Oct-2019

**Accepted:** 20-Dec-2019 **Published:** 10-Apr-2021

© 2021 Journal of Anaesthesiology Clinical Pharmacology | Published by Wolters Kluwer - Medknow