



## Case report

## A different clinical presentation of Heiner syndrome: The case of diffuse alveolar hemorrhage causing massive hemoptysis and hematemesis

Ayse Selcan Koc<sup>a,\*</sup>, Asena Sucu<sup>b</sup>, Umit Celik<sup>b</sup><sup>a</sup> Department of Radiology, University of Health Sciences, Adana Health Practices and Research Center, Adana, Turkey<sup>b</sup> Department of Pediatric, University of Health Sciences, Adana Health Practices and Research Center, Adana, Turkey

## ARTICLE INFO

## Keywords:

Heiner syndrome

Diffuse alveolar hemorrhage

Hemoptysis

Hematemesis

## ABSTRACT

Heiner syndrome is a non-IgE-mediated hypersensitivity to cow's milk, which often causes pulmonary disease in infants and young children. Patients often have symptoms of chronic or recurrent upper or lower respiratory tract infection. It has been reported that the Heiner's syndrome can cause recurrent pulmonary hemorrhage, and it is difficult to differentiate from the entity of idiopathic pulmonary hemosiderosis, another disease with recurrent pulmonary hemorrhage of unknown etiology usually occurring in the older children. Acute respiration is a rare problem in Heiner syndrome, which usually has symptoms and signs of chronic respiratory disease. In this case report, we present a 6-month-old patient who was admitted to our hospital with massive hemoptysis, hematemesis, and deep anemia.

## 1. Introduction

Heiner syndrome is a non-IgE-mediated hypersensitivity syndrome due to cow's milk, which often causes pulmonary disease in infants and young children, often misdiagnosed as chronic bronchopneumonia [1]. This causes the patients to be followed for a long time accidentally for chronic lung disease, and the diagnosis of Heiner syndrome may be delayed. However, when the disease is diagnosed, it can be treated and reverse the effects of disease by stopping cow's milk consumption [2]. Acute breathing problems are rare in Heiner syndrome, which usually has symptoms and signs of chronic respiratory disease [3]. In this report, we present a 6-month-old case who was admitted to our pediatric emergency department with massive hemoptysis, hematemesis, and deep anemia and treated for bronchopneumonia for 4-times, was diagnosed with Heiner's syndrome with clinical and laboratory findings.

## 2. Case presentation

A 6-month-old girl who had a history of 4 times hospitalization due to bronchopneumonia, presented to the pediatric emergency department with general condition disorder, hemoptysis and hematemesis. Her history revealed that she was born 3500 g at term and was hospitalized for 22-days in the neonatal intensive care unit. In her physical examination, her general status was moderate, and she had tachypnea, retractions, diffuse rales and rhonchi. The patient was admitted to the

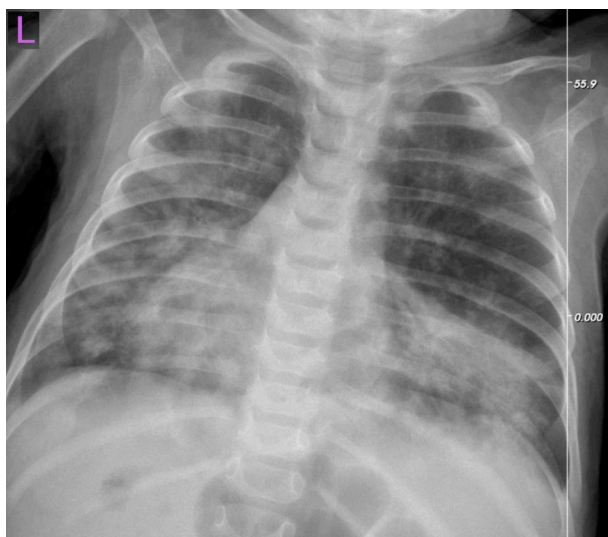emergency with Hb: 6.7 mg/dL and supported with erythrocyte suspension. Chest X-ray revealed nodular opacities and diffuse infiltration in both lungs (Fig. 1). Computed thorax tomography (CT) revealed diffuse and occasional patch-like consolidation areas that are more prominent in lower lobes and 7–8 mm sized irregularly limited nodularities were observed in both lung parenchyma, in axial (Fig. 2a) and coronal (Fig. 2b) sections. When the radiological findings were evaluated together with the clinical findings, diffuse alveolar hemorrhage was considered. Peripheral blood smear of the patient had 48% lymphocytes, 8% monocytes, 4% eosinophils and 40% PNL, platelet count was sufficient and there was no evidence of hemolysis. Hemosiderin-laden macrophages were seen in the patient's fasting stomach fluid examination. She was diagnosed with Heiner's syndrome with the present findings. The patient was offered hydrolyzed formulas, and the mother was started a diet for cow's milk protein allergy. Post-treatment chest X-ray revealed a regression in the findings of both lung parenchyma (Fig. 3). The patient's oral intake improved and the patient was discharged with recommendations of a diet with breast milk and hydrolyzed formulas as supplementary food and mother was recommended to continue her diet.

## 3. Discussion

The diagnosis of Heiner syndrome is difficult because the symptoms and findings are similar to many respiratory diseases. Therefore, the

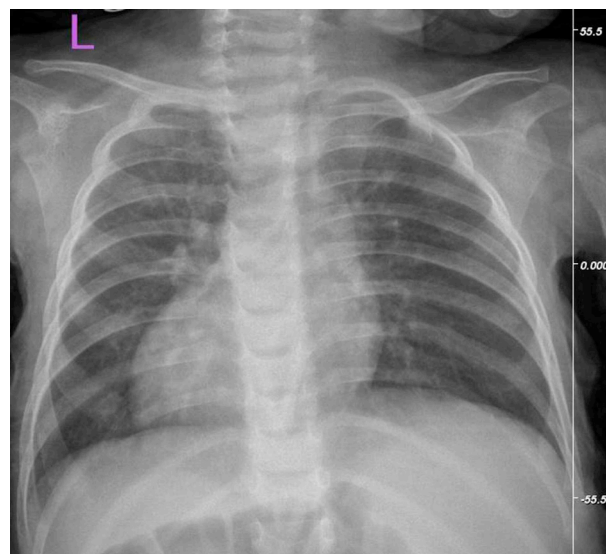
\* Corresponding author. Tel.: +90 506 242 59 88; fax: +90 322 455 90 00.

E-mail addresses: [draysesclankoc@gmail.com](mailto:draysesclankoc@gmail.com) (A.S. Koc), [asenaunal@yahoo.com](mailto:asenaunal@yahoo.com) (A. Sucu), [ucelik32@gmail.com](mailto:ucelik32@gmail.com) (U. Celik).



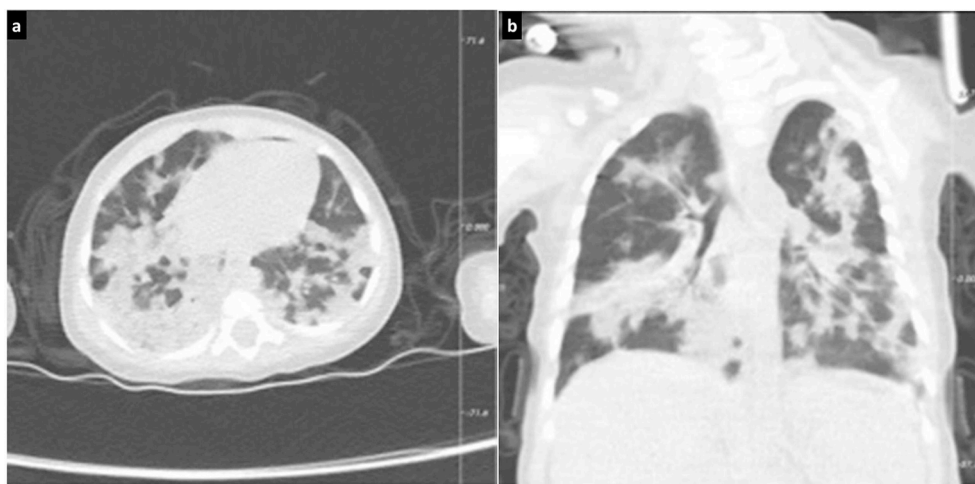**Fig. 1.** PA chest radiography revealed diffuse patch-like infiltrations and nodular opacities in both lungs.

disease is usually diagnosed late. The most important thing for diagnosing is to keep the disease in mind, to know the clinic well and to exclude the diseases in the differential diagnosis. The dramatic improvement of respiratory symptoms and findings after cessation of cow's milk intake is the most important support for diagnosis. There is no specific test to diagnose the disease. In the differential diagnosis of Heiner syndrome, aspiration pneumonia, acute and chronic lower respiratory tract infections including fungal infections, immunodeficiencies, cystic fibrosis, tuberculosis, and hypersensitivity pneumonia should come to mind. The symptoms and findings associated with recurrent pulmonary infiltration are defined by Heiner et al. [4] in 7-patients; reported chronic cough, recurrent fever, tachypnea, wheezing, rales, failure to thrive, and family history of allergy. In addition, it was reported that 4 cases presented with hemoptysis and anemia clinic and the diagnosis was made by showing iron-laden macrophage in bronchial aspirate or fasting gastric fluid. In a series of 8 cases published by Moissidis et al. [3], it has been reported that patients may present with chronic rhinitis, recurrent otitis media, gastrointestinal symptoms and eosinophilia. In the same article, two out of 8-cases reported hemoptysis. Iron-laden macrophage is positive in the



**Fig. 3.** After the treatment, it was observed that the findings of both lung parenchyma were found to be regressed on the chest X-ray.

patient with hemoptysis. A case similar to our case was presented by Moissidis et al. [3] who had episodic hemoptysis and mild wheezing persisting for 5-months in a 29-month-old girl who had been followed up for recurrent pneumonia. Findings of chest radiography and CT were similar but not as diffuse as our patient. The most important difference of our patient in this case is being the first presented a case with Heiner syndrome with hematemesis clinic and acute diffuse alveolar hemorrhage. However, in the previous case of Moissidis et al. alveolar hemorrhage was diagnosed with biopsy, but no biopsy was performed in our case. In addition to the clinics and symptoms, for the diagnosis, it is also important that there are patchy and fleeting opacities or infiltrations in the chest X-ray and CT and that there are varying degrees of eosinophilia and iron deficiency anemia. CT is especially important in the diagnosis of alveolar hemorrhage and pulmonary hemosiderosis. Another important test is the demonstration of iron-laden macrophage in bronchial or gastric aspirate. Although this finding is frequent, it may not be detected in all patients. In our patient, it was thought that she might have Heiner syndrome with a history of recurrent bronchopneumonia and all the auxiliary diagnostic methods mentioned.



**Fig. 2.** Computed thorax tomography (CT) revealed irregularly limited nodular views with a size of 7–8 mm on the axial (a) and coronal (b) sections, with common patch-like consolidation areas, more prominent in the lower lobes of both lung parenchyma.

Similar to the cases in the literature, our diagnosis became absolute with clinical healing and stopping recurrences after cessation of cow's milk intake. However, the case was different from the previous case series in the literature due to the acute and dramatic nature of the case and the presence of hematemesis. Also, it's different by having diffuse infiltrative and alveolar hemorrhagic regions in whole lung in thorax CT scan.

#### 4. Conclusion

As a result of the limited number of cases in the literature and the results obtained in our case, Heiner syndrome due to cow's milk may also be seen with acute and chronic exacerbation and serious hemoptysis and hematemesis in addition to bronchopneumonia clinic. Therefore, one of the differential diagnoses in patients with massive hemoptysis and hematemesis who have diffuse infiltrations on the chest radiograph should be Heiner syndrome. It should be kept in mind that diagnosis is more likely in patients with a history of bronchopneumonia many times before the emergency admission.

#### Declaration of interests

No.

#### Appendix A. Supplementary data

Supplementary data to this article can be found online at <https://doi.org/10.1016/j.rmcr.2019.01.019>.

#### References

- [1] D.C. Heiner, J.W. Sears, W.T. Kniker, Multiple precipitins to cow's milk in chronic respiratory disease. A syndrome including poor growth, gastrointestinal symptoms, evidence of allergy, iron deficiency anemia and pulmonary hemosiderosis, *Am. J. Dis. Child.* 103 (1962) 634–654.
- [2] I. Moissidis, D. Chaidaroon, P. Vichyanond, S.L. Bahna, Milk-induced pulmonary disease in infants (Heiner syndrome), *Pediatr. Allergy Immunol.* 16 (2005) 545–552.
- [3] I. Moissidis, D. Chaidaroon, P. Vichyanond, S.L. Bahna, Milk-induced pulmonary disease in infants (Heiner syndrome), *Pediatr. Allergy Immunol.* 16 (2005) 545–552.
- [4] D.C. Heiner, J.W. Sears, Chronic respiratory disease associated with multiple circulating precipitins to cow's milk, *Am. J. Dis. Child.* 100 (1960) 500–502.