



Case report

Successful intravenous immunoglobulin treatment in severe COVID-19 pneumonia

Maurizia Lanza^{a,*}, Giorgio Emanuele Polistina^a, Pasquale Imitazione^a, Anna Annunziata^a, Valentina Di Spirito^a, Carannante Novella^b, Giuseppe Fiorentino^a

^a Unit of Respiratory Physiopathology, Monaldi Hospital, Naples, Italy

^b First Division Infectious Diseases, Cotugno Hospital, Naples, Italy

ARTICLE INFO

Article history:

Received 3 May 2020

Received in revised form 4 May 2020

Accepted 4 May 2020

Keywords:

COVID 19

Immunoglobulin

Pandemia

Respiratory failure

Pneumoniae

ABSTRACT

We describe a 42-year old woman, admitted to our Department after 15 days of persistence of respiratory failure and treated with infusion of intravenous immunoglobulin with a successful outcome.

© 2020 The Author(s). Published by Elsevier Ltd. This is an open access article under the CC BY-NC-ND license (<http://creativecommons.org/licenses/by-nc-nd/4.0/>).

Introduction

Since December 2019, an illness caused by the severe acute respiratory syndrome coronavirus 2 (SARS-CoV-2) which emerged in Wuhan, Hubei, China, and subsequently, has caused a global pandemic of coronavirus disease 2019 (COVID-19) [1]. COVID-19 patients often develop mild symptoms such as fever, cough, muscle pain and fatigue with usually good prognosis. However, some of those infected, especially among older men with underlying diseases can develop severe life-threatening complications [2]. The World Health Organization has announced that the risk assessment of the COVID-19 is very high at the global level. Currently there is no specific vaccine or drugs for human coronavirus. Several potential therapies, including supportive interventions, immunomodulatory agents, antiviral therapy and transfusion of convalescent plasma, have been provisionally applied in clinical settings [3]. Some of these therapies have provided some benefits in the treatment of patients with COVID-19 infection. Most effective measures remain early detection and quarantine of new sources of infection, as well as early detection and support treatments for confirmed patients. Given the absence of specific antiviral therapy for SARS-CoV-2, in addition of conventional treatment some options are under investigation. Intravenous immunoglobulin (IVIG) has been clinically used as an

adjunct in the treatment of severe COVID-19 pneumonia [4,5], but there are disputes on its therapeutic effect.

Yun Xie et al reported intravenous administration of small doses of glucocorticoids (1–2 mg / kg) for 5–7 days on patients in critical conditions and early administration (48 h after admission in intensive care unit) of intravenous immunoglobulin (IVIG) treatment, as adjuvant treatment of COVID-19 pneumonia. They reported a reduction of use of mechanical ventilation, hospitalization with an improvement to achieve significant clinical effectiveness [4]. We here described a 42-years old woman, admitted to our Department after 15 days of persistence of respiratory failure and treated with infusion of intravenous immunoglobulin.

Case report

A healthy 42-year-old Caucasian woman with controlled hypothyroidism developed fever, loss of appetite, diarrhoea fatigue, cough and anosmia over about 7 days. She was admitted in Emergency Department on April 9, 2020. Physical examination showed fever (38 °C) and her pulse oxygen saturation was 90% in ambient air. The patient's BMI was 24, with a normal weight. Subsequently, at that time, her oxygen saturation was 95% on 2 L/min oxygen flow via nasal cannula with a respiratory rate of 24 times per minute. Laboratory examination revealed mild leukocytosis (14.980/mm³) with lymphopenia (600/uL), elevated C-reactive protein (CRP) and lactate dehydrogenase (LDH) (6.7 mg/dL, 564 IU/L, respectively). Levels of interleukin-6 (IL-6) were

* Corresponding author.

E-mail address: maurizia.lanza85@gmail.com (M. Lanza).

slightly higher 15.7 pg/mL. Routine chemistry showed high levels of transaminases (AST 47 and ALT 87 U/L) and electrolyte, and blood coagulation tests showed no abnormalities. Bacterial cultures and the PCR for other respiratory viruses were negative. Infection from SARS-CoV-2 was confirmed on swab test in real time polymerase chain reaction assay. On hospital ward the patient was treated with 400 mg of hydroxychloroquine once daily (the QTc interval was monitored daily) plus azithromycin 500 mg once daily. The computed tomography (CT) scan performed on April 11 showed large consolidations and bilateral ground glass opacities (GGO) areas such as progressive Covid-19 pneumonia (Fig. 1). After 6 days oxygen demand increased with a worsening of clinical conditions and for this reason she was transferred at the Sub Intensive Respiratory Department. She had no subjective dyspnea under reservoir mask (FiO₂ 60%), with respiratory rate over 30 times per minute. The CT scan performed on April 16 showed rapidly percentage increase of bilateral infiltrations and consolidations (Fig. 2). Laboratory examination showed white blood cell (WBC) count at 11.5600/mm³, with lymphopenia 500/uL of CRP and LDH elevated up to 8,7 mg/dL and 845 IU/L. Routine chemistry, electrolyte, and blood coagulation tests again revealed no abnormalities except mildly elevated AST and ALT (149 U/L and 170 U/L). The level of IL-6 was 18 pg/mL. Screening tests were negative for multiple respiratory pathogens. Arterial blood gases (ABG) showed: pH 7.42, PaCO₂ 42 mmHg, PaO₂ 116 mmHg, HCO₃⁻ 27.2 mmol/L with reservoir mask (FiO₂ 66%) with PaO₂/FiO₂ ratio of 181 mmHg. Respiratory rate was 32 times per minute. We decided to start treatment with Continuous Positive Airway Pressure (CPAP). Initial HACOR SCORE was 4. We set up support pressure of CPAP in 7 cmH₂O and FiO₂ 30%, with oro/nasal interface and double branch. After 1 h there was an improvement in arterial blood gases: pH 7.42, PaCO₂ 41 mmHg, PaO₂ 85 mmHg, HCO₃⁻ 26.6 mmol/L with PaO₂/FiO₂ ratio of 283 mmHg, and HACOR SCORE was 0. Respiratory rate of 18 times per minute. After obtaining informed consent from the patient, treatment with IVIG has been started. Recent data from the literature have reported improvements with significant clinical efficacy with use intravenous immunoglobulin. Furthermore, this choice was made to

avoid use of steroids which determine a reduction of viral clearance. IVIG was begun, specifically 450 mL (5 mL/kg) at 36 mL/h x 3 days with premedication with antihistamine and rehydration. Mild hypotension observed during routine check precipitated a decrease in infusion to 28 mL/h and subsequently extended total administration to 4 days. At the end of the administration with IVIG the respiratory function of the patient is significantly improved by rise of arterial blood gas values (ABG showed pH 7.40, PaCO₂ 45 mmHg, PaO₂ 103 mmHg, HCO₃⁻ 27.9 mmol/L with PaO₂/FiO₂ ratio 412). This led to the stop of respiratory support. The improvement in clinical and pulmonary function remained constant in the days to follow the infusion. Patient at sixth day after IVIG showed on ABG in current air: pH 7.38, PaCO₂ 36 mmHg, PaO₂ 90 mmHg, HCO₃⁻ 25 mmol/L with PaO₂/FiO₂ 433 mmHg. On April 24, a further chest CT scan was performed and showed a massive reduction in parenchymal consolidations, residual at present widespread areas of GGO parenchymal hyperattenuation and consolidating streaks with greater left lower lobar expression (Fig. 3).

Discussion

The COVID-19 outbreak is an unprecedented crisis for public health and the global economy and has had a huge impact on the world. Scientists around the world are evaluating COVID-19 effective treatments. Several potential therapies, including supportive interventions, immunomodulatory agents, antiviral therapy and transfusion of convalescent plasma, have been provisionally applied in clinical settings. Current guidelines recommend that systemic corticosteroids should not be routinely administered for the treatment of COVID-19 due to the lack of evidence of its clinical efficacy on reducing mortality [5]. The recent article on the risk factors associated with ARDS and death among COVID-19 patients showed that treatment with methylprednisolone may be helpful in reducing the risk of death for patients who develop ARDS [6]. However, it is believed that corticosteroids could inhibit the appropriate immune responses and viral clearance and delay the production of antibodies [6].

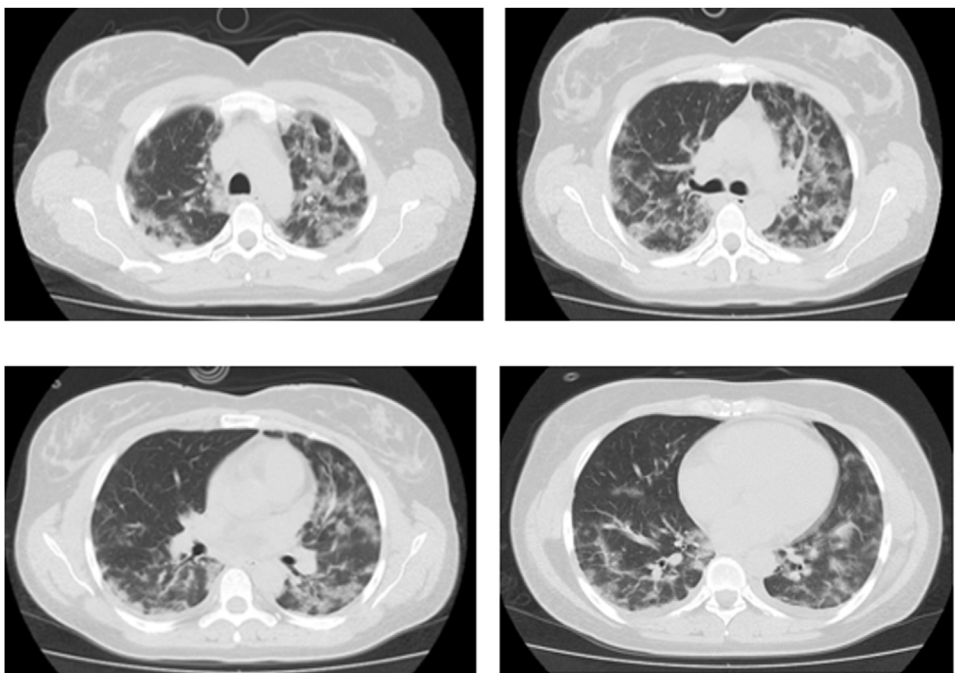


Fig. 1. Parenchymal opacity of the GGO type and consolidations, patchy, with distribution predominantly declive and longitudinal gradient.

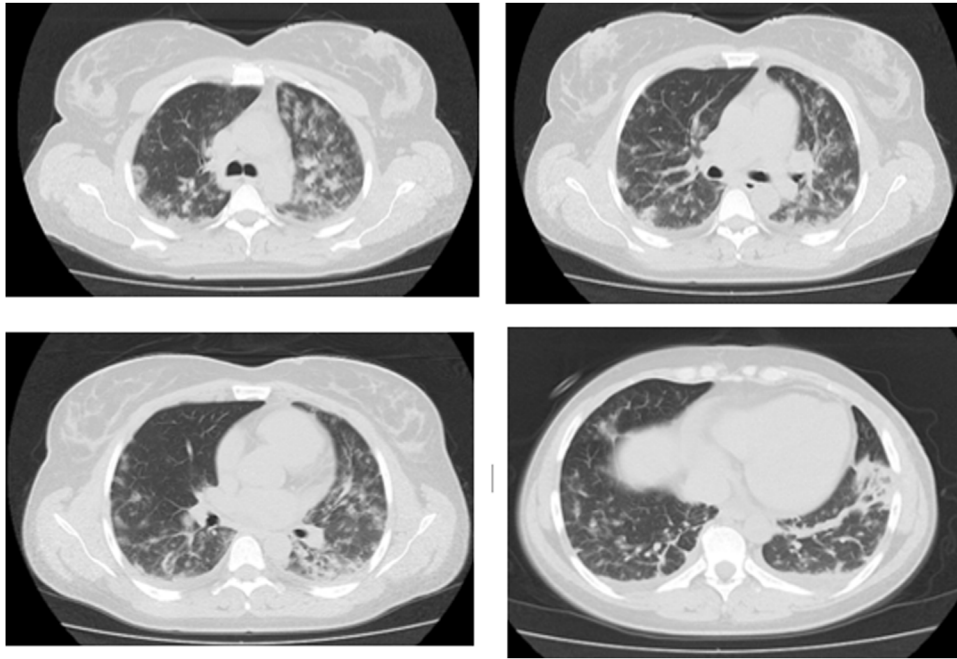


Fig. 2. Unchanged presence of multiple consolidation patches known, associated with diffuse parenchymal attenuation of the GGO, and extended with greater involvement of the lung.

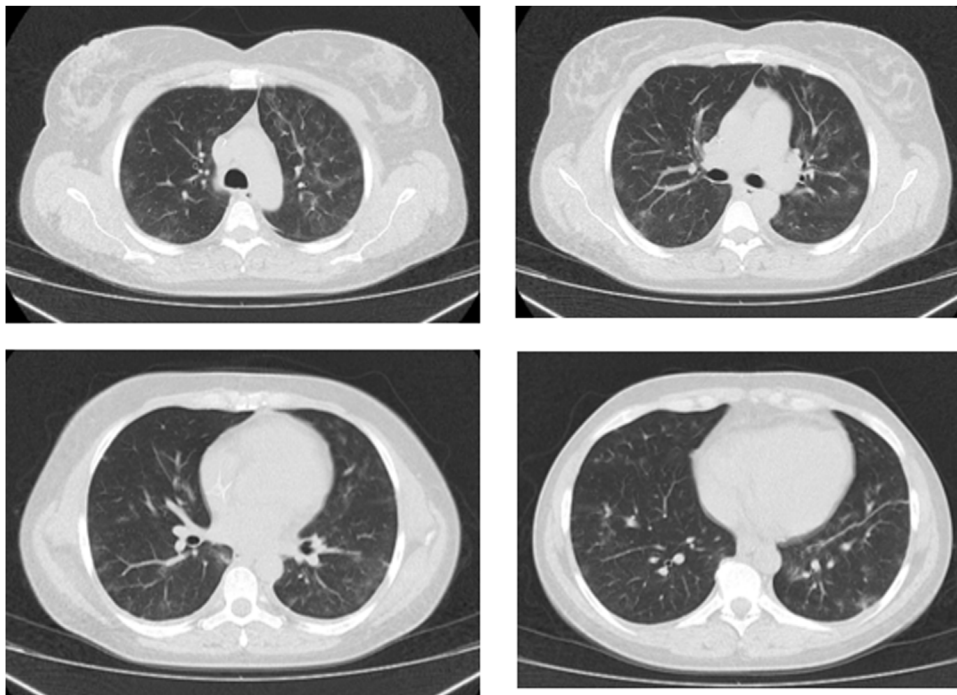


Fig. 3. Significant reduction in both sides of the multiple consolidative patches with few diffuse GGO areas and consolidations.

IVIG could be applied as adjuvant treatment of patients in critical condition. Being a blood product purified from the mixed plasma of healthy people, the protein is the main component and is rich in bacterial and viral IgG antibodies [10]. Continuous infusion may improve the level of IgG in serum, effectively neutralizing pathogens in the respiratory tract of the patient's system, thereby promoting recovery from illness and shortening the course of the disease. IVIG also can improve the body's defense, block the receptors associated with the target cell and prevent the pathogen to further damage the target cell [7]. IVIG acting as an agent that

modifies the body's immune response as it does on vasculitis, ITP and AIHA and Kawasaki. In addition, the use of IVIG can also influence the process of differentiation and maturation of lymphocytes, hinder the normal immune response of white blood cells, inhibit the production of inflammatory factors and thus reduce the inflammatory lesion encountered by patients [8–10]. IVIG acting as an agent that modifies the body's immune response as it does on vasculitis, ITP and AIHA and Kawasaki. A previous meta-analysis of IVIG in SARS infection concluded that it was not clear whether the IVIG improved the prognosis [11]. There are also

Table 1
Clinical and laboratory data of the trend of the patient during hospitalization.

Support	Ambient Air			C-PAP			Ambient Air		
							Venturi Mask		
Antimicrobial Therapy	Azithromycin Hydroxychloroquine			IVIG					
Days	11.04	14.04	16.04	17.04	18.04	19.04	20.04	21.04	23.04
Temperature, °C	37,5	36,7	36,4	36,2	36,3	36,4	36	36	35,6
wbc, 10 ³ /l	3,05	5,34	4,21	5,61	8,84	4,99	5,71	5,44	6,79
CrP, mg/dl	8,3	4,7	2,2	1,1	0,5	0,4	0,4	0,4	0,4
D-dimer, ng/mL	151	178	343	170	165	200	363	300	265
AST, U/L	31	44	114	149	77	38	25	30	23
ALT, U/L	46	55	116	187	152	100	80	76	65
GGT, U/L	15	17	21	27	35	30	26	22	20
Lymphocytes %	17,7	14	21,4	11,1	7,1	13,2	18,4	17,8	17,1
Platelets	153	258	270	262	304	243	268	273	264
Creatinin, mg/dL	0,5	0,6	0,4	0,4	0,5	0,4	0,5	0,4	0,5
pO ₂ , mmHg	56	51	91	109	103	90	89	91	88
P/F ratio	181	242	303	363	412	375	424	433	419
Lactate	0,9	1,9	0,8	0,6	1,2	1,1	2	2	3
Ves	42	50	52	49	38	49	43	34	30

reports of the literature on the use of IVIG in infection by MERS, but there is no evidence that IVIG has anti-MERS activity, since the specific efficacy has not been reported [9]. Studies on infection with influenza viruses such as H1N1, have shown that IVIG may prevent a serious infection with pandemic influenza. A multicenter, double-blind, randomized, controlled hyperimmune globulin used to treat patients with severe H1N1 infection in 2009 found that the use of h-IVIG in the treatment of severe H1N1 within 5 days from onset of symptoms was associated with reduction in viral load and reduction in mortality [9].

It is therefore worth considering when to use IVIG to help treat COVID-19. The IVIG has been clinically used as an adjunct in the treatment of severe pneumonia caused by influenza, but there are disputes on its therapeutic effect on COVID-19 pneumonia, despite the inclusion in the seventh edition of the guidelines stating that can be considered for use in critically ill and critically ill patients [9]. In our case the clinical intravenous administration of immunoglobulins has allowed a rapid clinical improvement demonstrated by the short period of need for respiratory support with CPAP, by the improvement of the blood values and gas and the radiological findings.

The patient was discharged after 15 days from the last CT with two negative swabs and reducing inflammatory markers, normalization of liver function and recovery of lung function (Table 1)

Conclusion

In summary the early use, in selected patients, of IVIG, as an adjuvant treatment for COVID-19 pneumonia, can reduce the use of mechanical ventilation, hospitalization and promote early recovery of patients with an improvement to achieve significant clinical effectiveness.

Author agreement statement

We the undersigned declare that this manuscript is original, has not been published before and is not currently being considered for publication elsewhere.

We confirm that the manuscript has been read and approved by all named authors and that there are no other persons who satisfied the criteria for authorship but are not listed.

We further confirm that the order of authors listed in the manuscript has been approved by all of us.

We understand that the Corresponding Author is the sole contact for the Editorial process.

He/she is responsible for communicating with the other authors about progress, submissions of revisions and final approval of proofs.

References

- [1] Munster Vincent J, Koopmans Marion, van Doremalen Neeltje, et al. A novel coronavirus emerging in China - key questions for impact assessment. *N Engl J Med* 2020;382:692-4.
- [2] Huang Chaolin, Wang Yeming, Li Xingwang, et al. Clinical features of patients infected with 2019 novel coronavirus in Wuhan, China. *Lancet* 2020;395:497-506.
- [3] James Sanders M, Marguerite Monoguel, Tomas Jodlowski, et al. Pharmacologic treatments for coronavirus disease 2019 (COVID-19): a review. *JAMA J Am Med Assoc* 2020, doi:http://dx.doi.org/10.1001/jama.2020.6019.
- [4] Xie Yun, Cao Song, Li Qingyun, et al. Effect of regular intravenous immunoglobulin therapy on prognosis of severe pneumonia in patients with COVID. *J Infect* 2020.
- [5] Cao Wei, Liu Xiaosheng, Bai Tao, et al. High-dose intravenous immunoglobulin as a therapeutic option for deteriorating patients with coronavirus disease 2019. *Open Forum Infect Dis* 2020.
- [6] World Health Organization. Geneva: World Health Organization; 2020. Jan 28, [Updated 2020]. [Accessed February 2, 2020]. [https://www.who.int/publications-detail/clinical-management-of-severe-acute-respiratory-infection-when-novel-coronavirus-\(ncov\)-infection-is-suspected](https://www.who.int/publications-detail/clinical-management-of-severe-acute-respiratory-infection-when-novel-coronavirus-(ncov)-infection-is-suspected).
- [7] Wu Chaomin, Chen Xiaoyan, Cai Yanping, et al. Risk factors associated with acute respiratory distress syndrome and death in patients with coronavirus disease 2019 pneumonia in Wuhan, China. *JAMA Intern Med* 2020(March).
- [8] Tagami Takashi, Matsui Hiroki, Fushimi Kiyohide. Intravenous immunoglobulin and mortality in pneumonia patients with septic shock: an observational nationwide study. *Clin Infect Dis* 2015;61(August (3)):385-92.
- [9] Hung Ivan FN, To Kelvin KW, Ivan Cheuk-KwongLee, et al. Hyperimmune IV immunoglobulin treatment: a multicenter double-blind randomized controlled trial for patients with severe 2009 influenza A(H1N1) infection. *Chest* 2013;144(2):464-73.
- [10] Diebel Lawrence N, Liberati David M, Diglio Clement A, et al. Immunoglobulin a modulates inflammatory responses in an in vitro model of pneumonia. *J Trauma: Inj Infect Crit Care* 2005;1099-106.
- [11] Busse Paula Jane, Razvi Samiya, Cunningham-Rundles Charlotte. Efficacy of intravenous immunoglobulin in the prevention of pneumonia in patients with common variable immunodeficiency. *J Allergy Clin Immunol* 2002;109(6):1001-4.