

TeleInGEstion Remote Video Capsule Endoscope

Aditya Sreenivasan, MD¹, Tianyu She, BA², Seth Gross, MD³, and Ian Storch, MD⁴

¹Long Island Jewish Medical Center-Northwell Health, New Hyde Park, NY

²New York Institute of Technology, College of Osteopathic Medicine, Old Westbury, NY

³NYU Langone Health, New York, NY

⁴Hofstra University/Northwell Health, School of Medicine, Hempstead, NY

ABSTRACT

We describe 2 cases in which video capsule endoscopy was performed remotely using TeleInGEstion Remote Video Capsule Endoscopy (TIGER VCE), given limited access to endoscopy during the COVID-19 pandemic. The patients ingested the CapsoCam capsule during a televisit, and the video was subsequently reviewed remotely by the physician. TIGER VCE was used to diagnose a benign etiology of melena and used to confirm a diagnosis of Crohn's disease before the initiation of biologic therapy. These cases demonstrate the safety and efficacy of TIGER VCE. We feel that this technique may be considered as a standard ingestion technique in the future.

INTRODUCTION

Video capsule endoscopy (VCE) is the gold standard for initial evaluation of the small bowel mucosa and is often used for the workup of obscure gastrointestinal bleeding and the diagnosis of Crohn's disease in the setting of a negative upper endoscopy and colonoscopy. We describe 2 cases of TeleInGEstion Remote Video Capsule Endoscopy (TIGER VCE) performed using the CapsoCam system during the COVID-19 pandemic when the use of endoscopy was limited to life-threatening emergencies. The capsule was mailed to the patient, ingested during a telehealth visit under physician supervision, mailed to a download center, and subsequently reviewed by the physician online. The capsule was used as a surrogate to the upper endoscopy in the first case and for evaluation of the terminal ileum in the second case. Our cases highlight the safety and efficacy of TIGER VCE for capsule endoscopy during times when endoscopic services are limited or when patients cannot travel to the office.

CASE REPORT

Patient 1: A 63-year-old man scheduled a posthospitalization televisit during the COVID-19 pandemic. The patient reported a recent hospitalization for melena, during which he was found to be hypotensive and have a drop in hemoglobin from 13.4 to 8.0. Although transfusion of 2 units of packed red blood cells was required, endoscopy was deferred because of the COVID-19 pandemic. He was discharged after 24 hours on oral proton-pump inhibitor therapy. The patient voiced significant anxiety about the possibility of recurrent bleeding or underlying malignancy. The option of VCE as a surrogate to endoscopy was discussed, and TIGER VCE was performed. We mailed a CapsoVision capsule and retrieval kit to the patient. During a televisit performed in the presence of a responsible adult to monitor for signs of aspiration, consent was obtained, and the patient ingested the capsule. The capsule was retrieved by the patient, and it was mailed to the download center. The study was reviewed online using CapsoCloud Technology. A benign-appearing, hemorrhagic, pedunculated gastric polyp, approximately 15 mm in size without signs of active bleeding, was observed in the gastric antrum, and the patient was reassured (Figure 1).

Patient 2: A 42-year-old woman was seen for a second opinion for bloody diarrhea and 10-lb weight loss and discussion of biologic treatment for Crohn's disease. An upper endoscopy and colonoscopy without terminal ileal intubation had been performed at an outside institution and were unremarkable. Magnetic resonance enterography showed findings consistent with Crohn's disease, but no evidence of small bowel stricture. Oral steroids were started with minimal response. We recommended repeat colonoscopy with ileal intubation before the initiation of biologic therapy. Unfortunately, the procedure was canceled because of the COVID-19 pandemic.

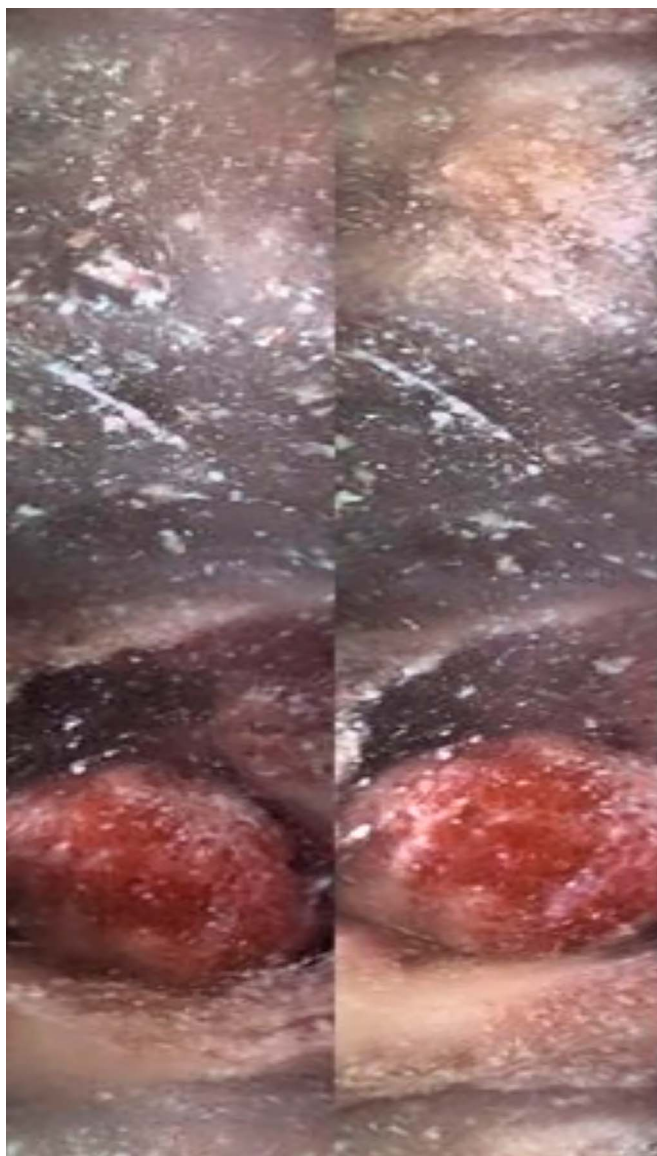

Figure 1. A benign-appearing hemorrhagic polyp noted in the gastric antrum without signs of active bleeding.

During a televisit, the patient expressed reluctance to come to the office because of her immunosuppressed status while on oral steroids. We discussed the option of TIGER VCE, and the patient agreed. The risk of capsule retention was discussed with the patient but deemed to be acceptable because of magnetic resonance enterography findings. The procedure revealed significant ulceration of the distal ileum with a Lewis Score of 215, confirming Crohn's disease. The patient was started on adalimumab (Figure 2).

DISCUSSION

These 2 cases highlight the use of TIGER VCE as a surrogate for endoscopy and colonoscopy when these procedures were not available. Food and Drug Administrations' decision to grant discretionary approval to perform remote ingestions with

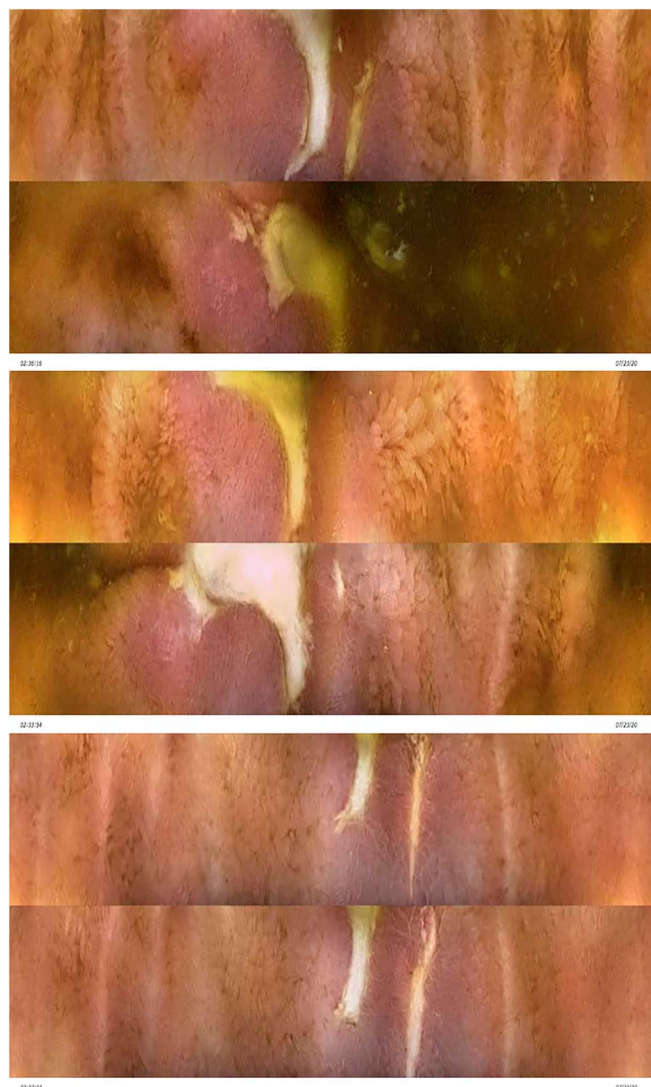


Figure 2. Findings consistent with Crohn's disease in the terminal ileum: inflammation characterized by erythema, nonbleeding ulceration with inflammatory exudate, and stricture.

Capsocam Plus will allow further exploration of this innovative technique. Standard capsule systems require the patient to travel to the office and get connected to a monitor before ingesting the capsule. The patient then needs to return to have the equipment removed, and the study downloaded before the ordering physician can review the video. The Capsocam system (Food and Drug Administration approved for use in the United States in 2017) is ideal for TIGER VCE, given that images are stored on a hard drive within the capsule itself and bulky recording devices are not required. The 4-camera system gives a 360-degree view of the mucosa and has been shown to give a better mucosal visualization when detection of the ampulla is used as a surrogate.¹

With TIGER VCE, the capsule and kit are mailed directly to the patient's house after the patient is prescreened for aspiration risk.

The patient ingests the capsule under physician supervision with another responsible adult present during a televisit, and instructions for retrieval are reviewed. After the patient retrieves the capsule, it is stored in the appropriate container and mailed in a preprinted envelope to the California download center, where the video is uploaded to the CapsoCloud. The physician views the study online and generates a report. The main risks of capsule endoscopy include nonnatural excretion and capsule aspiration. Aspiration of a video capsule is a rare but serious risk of the procedure with an estimated rate of 0.1%.² It occurs mainly in elderly male patients with multiple comorbidities and poor functional status. Almost 60 percent of cases are symptomatic (predominantly cough) with no significant respiratory compromise reported.

Although aspiration is rare, screening patients for a history of dysphagia and consideration of age and associated comorbidities are critical. Observed ingestion through TIGER VCE allows the physician to monitor for signs of difficulty swallowing the capsule or cough. We feel that the presence of a responsible adult at the time of the ingestion is necessary in case of choking so that 911 can be called. Our cases highlight the use of TIGER VCE to perform capsule endoscopy studies with the CapsoCam capsule system without the need for the patient to travel to the physician's office. We feel that TIGER VCE is an important modality that not only broadens the armamentarium of gastroenterologists when endoscopic services are limited but will increase compliance with capsule endoscopy by simplifying the VCE process and removing barriers, such as travel, time-off from work, and access to gastroenterologists. Further study will

be needed to determine whether this method of capsule endoscopy should become "standard of care."

DISCLOSURES

Author contributions: A. Sreenivasan wrote the article. T. She and I. Storch wrote and edited this article. S. Gross edited the article. I. Storch is the article guarantor.

Financial disclosure I. Storch has previously worked as a consultant for CapsoVision. No other authors have any conflicts of interest to disclose.

Informed consent was obtained for this case report.

Received October 7, 2020; Accepted February 16, 2021

REFERENCES

1. Friedrich K, Gehrke S, Stremmel W, Sieg A. First clinical trial of a newly developed capsule endoscope with panoramic side view for small bowel: A pilot study. *J Gastroenterol Hepatol*. 2013;28(9):1496–501.
2. Yung DE, Plevris JN, Koulaouzidis A. Short article: Aspiration of capsule endoscopes: A comprehensive review of the existing literature. *Eur J Gastroenterol Hepatol*. 2017;29(4):428–4.

Copyright: © 2021 The Author(s). Published by Wolters Kluwer Health, Inc. on behalf of The American College of Gastroenterology. This is an open access article distributed under the terms of the Creative Commons Attribution-Non Commercial-No Derivatives License 4.0 (CCBY-NC-ND), where it is permissible to download and share the work provided it is properly cited. The work cannot be changed in any way or used commercially without permission from the journal.