



Emerging Roles of the Endolumenal Functional Lumen Imaging Probe in Gastrointestinal Motility Disorders

Rona M Ata-Lawenko¹ and Yeong Yeh Lee^{2*}

¹Section of Gastroenterology, De La Salle Health Sciences Institute, Dasmariñas City, Cavite, Philippines; and ²School of Medical Sciences, Universiti Sains Malaysia, Kubang Kerian, Kota Bharu, Kelantan, Malaysia

Gastrointestinal sphincters play a vital role in gut function and motility by separating the gut into functional segments. Traditionally, function of sphincters including the esophagogastric junction is studied using endoscopy and manometry. However, due to its dynamic biomechanical properties, data on distensibility and compliance may provide a more accurate representation of the sphincter function. The endolumenal functional lumen imaging probe (EndoFLIP) system uses a multi-detector impedance planimetry system to provide data on tissue distensibility and geometric changes in the sphincter as measured through resistance to volumetric distention with real-time images. With the advent of EndoFLIP studies, esophagogastric junction dysfunction and other disorders of the stomach and bowels may be better evaluated. It may be utilized as a tool in predicting effectiveness of endoscopic and surgical treatments as well as patient outcomes.

(J Neurogastroenterol Motil 2017;23:164-170)

Key Words

Compliance; Electric impedance; Esophagogastric junction; Humans; Manometry

Introduction

Gastrointestinal (GI) sphincters play a vital role in gut function and motility by separating the gut into functional segments.¹ The esophagogastric junction (EGJ) is a dynamic mechanical structure separating the esophagus and stomach and it relies on extrinsic and intrinsic mechanisms to perform its function.^{1,2} Factors that contribute to effective trans-EGJ flow include peristalsis, gravity, the viscoelastic properties of the esophageal wall, and muscle tone of the crural diaphragm.³

High-resolution manometry is the current gold standard to determine the EGJ sphincter function.² However, manometry measures static pressure exerted over an area of surrounding tissues and does not consider radial force. Additionally, manometry is also unable to differentiate between relaxed and contracted states of the EGJ.² In the 1960s, Harris and Pope found that a contracting sphincter did not necessarily mean a competent EGJ.⁴ EGJ competence can be attributed to several other factors including tone, viscoelasticity, mechanoreception, and bolus transport.⁵ The measurement of radial force through resistance to distention, ie, distensibility, rather than pressure alone, should be a prime determinant

Received: October 13, 2016 Revised: None Accepted: November 20, 2016

© This is an Open Access article distributed under the terms of the Creative Commons Attribution Non-Commercial License (<http://creativecommons.org/licenses/by-nc/4.0>) which permits unrestricted non-commercial use, distribution, and reproduction in any medium, provided the original work is properly cited.

*Correspondence: Yeong Yeh Lee, MD, PhD, FACP, FRCP, FACC

School of Medical Sciences, Universiti Sains Malaysia, 16150 Kubang Kerian, Kelantan, Malaysia
Tel: +60-179028147, Fax: +60-97673949, E-mail: justnleey@gmail.com

of sphincteric strength.⁶ The barostat, impedance planimetry (IP) and more recently, the functional lumen imaging probe (FLIP) are available techniques for measuring luminal distensibility.⁷

The barostat measures the pressure and volume in tubular segments in a direct fashion, but the muscle tone indirectly.^{8,9} The principle of the barostat is to exert a constant pressure within a balloon to check for distensibility and to demonstrate pain thresholds.^{6,7}

On the other hand, IP is a technique designed to measure the relationship of cross-sectional area (CSA) and pressure during constant volume distention in the GI lumen.^{3,9} Electrical impedance is converted into an area measurement.¹⁰ The CSA is used to estimate wall tension and strain inside the lumen.⁷ Originally developed for the study of the EGJ, Rao et al first described the IP technique as a method to quantify esophageal wall distensibility.⁹ By applying the law of Laplace, the wall tension can be calculated from CSA and pressure data.⁵ Through IP, the viscoelastic properties of the esophagus, which include circumferential wall tension, compliance, strain and wall stiffness, can be calculated.⁹ The threshold pressure for sensation can also be ascertained. The esophageal wall is compliant to stretch of up to a balloon distention of 40 cm H₂O.⁹ The CSA-pressure relationship at a constant volume is referred as the wall distensibility.¹¹

The newer FLIP adopts the same principle of IP.^{10,12,13} The endolumenal FLIP (EndoFLIP) EF-100 System (Crospon Ltd, Galway, Ireland) uses a multi-detector IP system to produce a 3-di-

dimensional outline of a distensible organ (Fig. 1A).^{7,10} The concept of FLIP was first demonstrated by McMahon and Gregersen in 2007.¹ Tissue distensibility and geometric changes in the EGJ are measured through resistance to volumetric distention with real-time images.^{2,6,14,15} EGJ distensibility index is calculated as the narrowest CSA divided by balloon distending pressure. In healthy volunteers, Lin et al established a linear EGJ CSA-pressure relationship using a balloon distending pressure below 8 mmHg and there was regional distensibility differences with the greatest distensibility seen 3 cm above the EGJ.³

Test Equipment

The EndoFLIP EF-325N measurement probe consists of a polyurethane balloon mounted on the distal 14 cm of a plastic catheter which is 240 cm long, and 3 mm wide (Fig. 1B).^{15,16} The balloon assumes a cylindrical shape providing an image that is 8 cm long, with a diameter of 2.5 cm, and a maximal 50 mL capacity.^{13,16} Within the balloon, there is a 16 cm IP segment with 17 ring electrodes spaced 5 mm apart and also a solid state pressure transducer.^{3,14,15} When inflated, the balloon may be distended to a maximal diameter of 2.5 cm and a CSA of 490 mm².⁹ The balloon can be filled with a specially formulated saline solution.¹³ The EndoFLIP EF-100 system is pre-calibrated but catheters require a pre-use purge sequence to remove air from the inflation line and

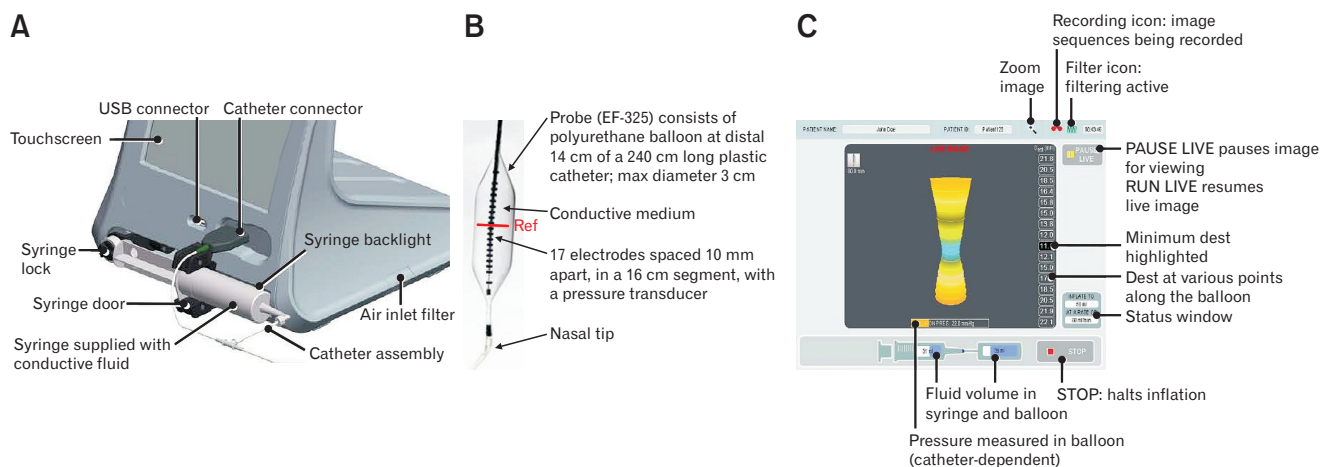


Figure 1. Components of the endolumenal functional lumen imaging probe (EndoFLIP; EF100) system. (A) There is a catheter connector that connects the syringe which is held by a syringe door and lock to the catheter. There are several catheters but the most common is EF-325 (for description, see B). The recording unit has a touchscreen display with a primary user interface (for description, see C). (B) The catheter (EF-325N) is a 240 cm long plastic catheter with a polyurethane balloon at its distal end with a maximum diameter of 2.5 cm. Conductive medium fills the balloon during inflation, and within the balloon there are 17 impedance electrodes within a 8 cm segment. Ref is midpoint of the balloon catheter. (C) The display has a friendly touchscreen interface that includes injection volume controls, live images of the balloon inflation and a status window.

balloon (Fig. 1A).¹³ The catheter's protective sheath is removed and the balloon is placed inside the pre-use metallic tube.¹⁵ Once turned on, the system monitor has a touchscreen control function (Fig. 1C). Both the catheter probe and syringe are connected to the unit to begin the automated purge sequence.⁵

Test Procedure

The distal end of probe is lubricated with gel if inserted nasally or it can be inserted alongside the endoscope channel until the balloon is oriented in the esophagus.¹⁵ For upper GI evaluation, the study subject is required to fast for at least 6 hours.¹² Topical anesthesia is administered to the posterior pharyngeal wall and the subject is then instructed to lie supine with the head tilted by approximately 30° for catheter insertion.⁵ The catheter may be inserted trans-orally until the 45 cm mark is at the level of the patient's teeth or trans-nasally until the 55 cm mark is at the level of the patient's nares for EGJ studies.² The catheters are inserted alongside the endoscope and positioned at the EGJ under direct vision.¹³ Once the probe is placed straddling the EGJ, the balloon is inflated typically to 30 mL or 40 mL.¹³ The monitor will display the EGJ shape which can then be saved for later analysis. Subjects are asked to avoid swallowing during balloon inflation.¹⁵ Measurement of CSA and pressure can be performed up to a maximum volume of 50 mL. Once the procedure is completed, the balloon is deflated

fully and may be removed. The catheter can also be used to evaluate other sphincters such as the pyloric sphincter and anal sphincter, and similar procedural steps can be applied to these sphincters.

Analysis of Endolumenal Functional Lumen Imaging Probe Data

The balloon distention volume, intra-balloon pressure, and planimetry data are displayed in real-time.^{3,12} The system generates FLIP images at a sampling rate of 10 Hz.^{2,3} The bag assumes an hourglass shape with the central constriction at the least distensible locus.¹² Some researchers calculate the median of each CSA and intra-balloon pressure for 30 seconds at each volume distention.¹⁶ The distensibility index (mm²/mmHg) is displayed on the unit. Compliance (mm³/mmHg) is also displayed, it being the volume between 1 cm above and 1 cm below the narrowest point in the EGJ divided by intra-balloon pressure. Wall tension (mmHg·mm) can be calculated according to the Laplace's law, ie, tension = distention pressure × measured minimum radius.¹⁴

Clinical Utility

The indications for clinical use in GI motility disorders of EndoFLIP are expanding. Besides providing physiological data, this technique can guide subsequent clinical management based

Table. The Rationale and Call to Action Using Functional Lumen Imaging Probe Parameters in Upper Gastrointestinal Conditions

Conditions	Rationale	Call to action
Achalasia	Provides the equivalence of barium height test but during endoscopy.	Distensibility ≤ 1 mm ² /mmHg and diameter ≤ 5 mm may indicate the need for dilatation/POEM/Heller myotomy.
Eosinophilic esophagitis	Narrow caliber esophagus is highly predictive of food impaction.	Focal diameter ≤ 17 mm indicates the need for dilatation or drug intervention.
Stricture	Determine stricture size and gauge if dilation is needed.	If diameter ≤ 17 mm indicates the need for dilatation.
Gastroesophageal reflux disease	Useful adjunct to Hill grading of the gastroesophageal flap valve geometry during endoscopy.	Diameter > 9-10 mm suggests that fundoplication may be beneficial. May help to select optimal patients for minimally invasive procedures.
Gastroparesis	Helps to select pylorus problem from antral problem by measuring pylorus stiffness or laxity. More than half of patients may not derive benefit from treatment of pylorus because of incorrect patient selection, and EndoFLIP can help to select the right patients who may benefit from botox/dilatation.	Distensibility < 10 mm ² /mmHg suggests the pylorus will benefit from treatment

POEM, peroral endoscopic myotomy; EndoFLIP, endolumenal functional lumen imaging probe.

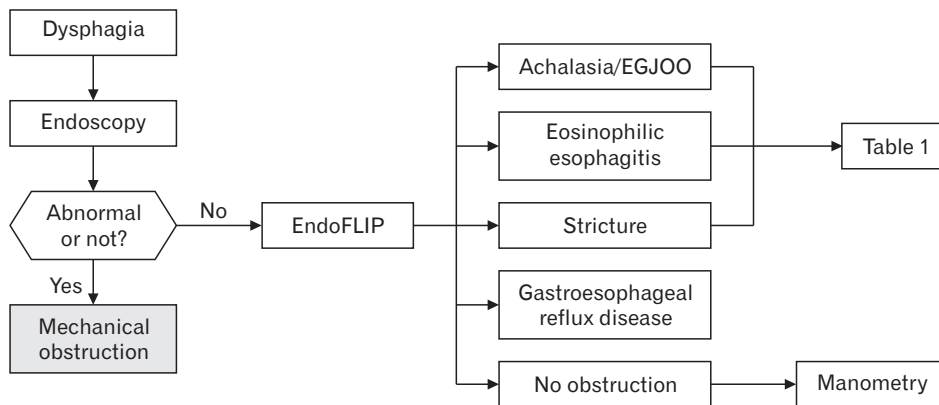


Figure 2. Proposed algorithm incorporating the use of endoluminal functional lumen imaging probe (EndoFLIP) in management of dysphagia. EGJOO, esophagogastric junction outflow obstruction.

on distensibility or diameter cut-offs (Table). Being a common problem, dysphagia is an obvious indication for EndoFLIP that can be performed at the time of endoscopy (Fig. 2). Findings from EndoFLIP can determine if further manometry studies or subsequent therapy are needed, for instance in cases of narrow esophagus lumen or of EGJ outflow obstruction.

Achalasia

In contrast to lower esophageal sphincter (LES) measurement by manometry, EGJ distensibility in achalasia better predicts esophageal emptying and clinical response to therapies.¹⁷ Pandolfino et al¹⁸ showed that EGJ distensibility was significantly greater in a successfully treated achalasia group than an untreated achalasia group. There was also a significant correlation between the Eckardt symptom score severity and EGJ distensibility.¹⁸ EndoFLIP also detects esophageal contractility that is not observed with manometry in achalasia¹⁹ and may in future be useful in subtyping of achalasia.²⁰ We propose that a distensibility of $\leq 1 \text{ mm}^2/\text{mmHg}$ and a diameter $\leq 5 \text{ mm}$ as cut-offs for the need of dilation or peroral endoscopic myotomy (POEM) or myotomy (Table). Distensibility of the EGJ was found to increase following pneumatic dilation²⁰ but a successful outcome may require that the dilation achieves a higher distensibility than that found in normal subjects due to incompetent motility in this group of patients.^{21,22} Familiari et al²³ studied the utility of EndoFLIP in patients who underwent POEM for achalasia and found a substantial post-POEM increases in the diameter and CSA of the EGJ. Subsequent studies of EndoFLIP in POEM and Heller's myotomy have proven the usefulness of distensibility measurement.^{24,25}

Eosinophilic Esophagitis

Reduced esophageal distensibility in eosinophilic esophagitis

(EoE) was significantly associated with increased risk of symptoms and increased likelihood of eventual need for dilation.^{26,27} A focal diameter $\leq 17 \text{ mm}$ indicates the need for dilation or drug intervention in EoE (Table). The same criteria can be applied for esophageal stricture. FLIP topography is a new FLIP technique in development that describes regional variation of CSA over time, and it can provide a more global assessment of distensibility along the axial plane and allows differentiation of endoscopic phenotypes.²⁸ A more recent study suggests that endoscopic ring severity may serve as a marker of remodelling with lower distensibility in higher ring scores.²⁹ Eosinophil counts have poor correlation both with post-treatment symptoms, and with distensibility, whereas the distensibility plateau has been shown to correlate with symptoms.^{27,29}

Gastroesophageal Reflux Disease and Anti-reflux Surgery

In gastroesophageal reflux disease (GERD), a primary abnormality is an increased reflux volume from an abnormally compliant or more distensible EGJ.³⁰ The Hill grade is used to assess the gastroesophageal flap valve geometry,³¹ and EndoFLIP can be an useful adjunct. Kwiatek and colleagues showed an increase in EGJ distensibility of up to 3-fold in GERD patients compared to controls.¹³ In addition, McMahon et al⁶ observed that GERD patients had more distensible and shorter length hiatus than normal subjects. Likewise, Lottrup et al⁸ has shown increases in distensibility in patients with hiatal hernia. EndoFLIP may also be used to assess GEJ distensibility prior to antireflux surgery for surgical technique planning and for assessing long-term outcomes. We propose that a diameter $> 9\text{-}10 \text{ mm}$ in patients with GERD indicates that Nissen fundoplication may be beneficial (Table). Kwiatek et al¹² compared EGJ compliance in patients who underwent fundoplication using FLIP. Their findings showed that the least distensible locus was at

the hiatus and that compared to controls, fundoplication patients had significantly lower EGJ distensibility and EGJ compliance. Furthermore, the FLIP study demonstrated both an increased length of the constricted segment after fundoplication and reduced compliance.

Upper Esophageal Sphincter Evaluation

Besides the EGJ, FLIP has been utilized in the study of the upper esophageal sphincter (UES). Regan et al studied its utility in the measurement of UES distensibility among healthy volunteers.¹⁵ The authors have successfully measured the UES diameter and pressure at rest, during swallowing and voluntary maneuvers. Further study by the same group allowed measurement of UES distensibility and opening patterns during swallowing.³² Further research is needed to establish clinical utility in UES related disorders.

Gastroparesis

EndoFLIP has been shown to be a feasible technique in the measurement of pyloric distensibility, and in a study, early satiety and postprandial fullness were found to be inversely correlated with diameter and CSA of the pylorus.³³ In addition, fasting pyloric compliance was found to decrease in a sub-group of gastroparetic patients, and dilation in these patients improved the quality of life scores.³⁴ The basal pyloric pressure was also found to be elevated in almost half of patients with nausea and vomiting and delayed gastric emptying.³⁵ The above findings suggest that EndoFLIP can help to identify the appropriate pylorus that may benefit from intervention. Botox and dilation interventions only provide benefit in less than half of gastroparetic patients and the reason may be incorrect selection of patients. We propose a distensibility $< 10 \text{ mm}^2/\text{mmHg}$ as the cut-off criteria for pyloric intervention (Table).

Sphincter of Oddi Evaluation

By using a smaller probe, Kunwald et al³⁶ were able to demonstrate the feasibility and reproducibility of FLIP technique in sphincter of Oddi function studies. Its potential role in the management of sphincter of Oddi dysfunction, however, needs further investigation.

Anal Sphincter Evaluation and Fecal Incontinence

Due to segmental dynamic properties of the anal muscles, manometry alone may be insufficient to determine the biomechanical properties of the anal canal. Luft et al,¹⁴ studied the use of EndoFLIP in assessing anal canal properties in healthy individuals. The authors concluded that the upper part of the anal canal is the

most compliant and that the least distensible part is the mid-anal canal region, which contributes the most to resting anal continence.¹⁴ Similar results were reported by Alqudah et al.³⁷ In a study by Gourcerol et al³⁸ comparing the use of EndoFLIP and 3-dimensional high-resolution manometry, it was found that anal distensibility index was higher at rest and during voluntary contraction in fecal incontinence than in healthy subjects, and that the discrimination was better using the distensibility index as compared with the anal pressure. EndoFLIP may be used intra-operatively to assess the anal sphincter geometry and tightness during repair or augmentation. The anal canal length, anal canal diameter derived from the EndoFLIP study and rectal pressure from manometry can be used to calculate the flow which allows identification of incontinence phenotyping. Further studies are needed to confirm the above findings.

Safety and Future Development

The procedure is well-tolerated and there have been no adverse events reported thus far. Despite being so, there must be caution for potential perforation in post-operative and post-radiation conditions, and especially when the insertion is blind without endoscopic guidance.

As mentioned above, FLIP topography is a new technique and future development of the system may incorporate this new method. EndoFLIP has only been in clinical use since 2009, but despite being a relatively young technology, there has been tremendous interest in the technology within the scientific and medical community. Other developments may include the use of EndoFLIP in a management algorithm such as shown in Figure 2 to guide the use of further investigation or interventions.

Conclusion

The EndoFLIP provides data on the biomechanical properties of GI sphincters and walls. The measurement of EGJ distensibility and compliance has been shown to be useful in disorders such as GERD, EoE, and achalasia. It may also be used as a tool in predicting effectiveness of endoscopic and surgical treatments as well as patient outcomes. With FLIP, other sphincters in the GI tract including the anal canal may also be studied.

Acknowledgements: We also thanked Crospon Ltd and MedicPro Supplies Sdn Bhd for providing the necessary information and support towards the current work.

Financial support: Part of research in the current paper was funded by the Research University Individual (RUI) grant of Universiti Sains Malaysia (Grant No. 1001/PPSP/812151).

Conflicts of interest: None.

Author contributions: Yeong Yeh Lee and Rona M Atalawenko contributed equally to conception, methods, literature reviews, and writing of manuscript.

References

- McMahon BP, Drewes AM, Gregersen H. Functional oesophago-gastric junction imaging. *World J Gastroenterol* 2006;12:2818-2824.
- McMahon BP, Frøkjaer JB, Kunwald P, et al. The functional lumen imaging probe (FLIP) for evaluation of the esophagogastric junction. *Am J Physiol Gastrointest Liver Physiol* 2007;292:G377-G384.
- Lin Z, Nicodème F, Boris L, et al. Regional variation in distal esophagus distensibility assessed using the functional luminal imaging probe (FLIP). *Neurogastroenterol Motil* 2013;25:e765-e771.
- Harris LD, Pope CE 2nd. "Squeeze" vs. resistance: an evaluation of the mechanism of sphincter competence. *J Clin Invest* 1964;43:2272-2278.
- McMahon BP, Frøkjaer JB, Drewes AM, et al. A new measurement of oesophago-gastric junction competence. *Neurogastroenterol Motil* 2004;16:543-546.
- McMahon BP, Jobe BA, Pandolfino JE, Gregersen H. Do we really understand the role of the oesophagogastric junction in disease? *World J Gastroenterol* 2009;15:144-150.
- Gregersen H, Drewes AM, McMahon BP, Liao D. Balloon-distension studies in the gastrointestinal tract: current role. *Dig Dis* 2006;24:286-296.
- Lottrup C, Gregersen H, Liao D, et al. Functional lumen imaging of the gastrointestinal tract. *J Gastroenterol* 2015;50:1005-1016.
- Rao SS, Hayek B, Summers RW. Impedance planimetry: an integrated approach for assessing sensory, active, and passive biomechanical properties of the human esophagus. *Am J Gastroenterol* 1995;90:431-438.
- Hoppo T, McMahon BP, Witteman BPL. Functional lumen imaging probe to assess geometric changes in the esophagogastric junction following endoluminal fundoplication. *J Gastrointest Surg* 2011;15:1112-1120.
- Pandolfino JE, Shi G, Curry J, Joehl RJ, Brasseur JG, Kahrilas PJ. Esophagogastric junction distensibility: a factor contributing to sphincter incompetence. *Am J Physiol Gastrointest Liver Physiol* 2002;282:G1052-G1058.
- Kwiatk MA, Kahrilas K, Soper NJ, et al. Esophagogastric junction distensibility after fundoplication assessed with a novel functional luminal imaging probe. *J Gastrointest Surg* 2010;14:268-276.
- Kwiatk MA, Pandolfino JE, Hirano I, Kahrilas PJ. Esophagogastric junction distensibility assessed with an endoscopic functional luminal imaging probe (EndoFLIP). *Gastrointest Endosc* 2010;72:272-278.
- Luft F, Fynne L, Gregersen H, et al. Functional luminal imaging probe: a new technique for dynamic evaluation of mechanical properties of the anal canal. *Tech Coloproctol* 2012;16:451-457.
- Regan J, Walshe M, Rommel N, McMahon BP. A new evaluation of the upper esophageal sphincter using the functional lumen imaging probe: a preliminary report. *Dis Esophagus* 26:117-123.
- Tucker E, Sweis R, Anggiansah A, et al. Measurement of esophago-gastric junction cross-sectional area and distensibility by an endoluminal functional lumen imaging probe for the diagnosis of gastroesophageal reflux disease. *Neurogastroenterol Motil* 2013;25:904-910.
- Rohof WO, Hirsch DP, Kessing BF, Boeckxstaens GE. Efficacy of treatment for patients with achalasia depends on the distensibility of the esophagogastric junction. *Gastroenterology* 2012;143:328-335.
- Pandolfino JE, de Ruigh A, Nicodème F, Xiao Y, Boris L, Kahrilas PJ. Distensibility of the esophagogastric junction assessed with the functional lumen imaging probe (FLIP™) in achalasia patients. *Neurogastroenterol Motil* 2013;25:496-501.
- Ponds FA, Bredenoord AJ, Kessing BF, Smout AJ. Esophagogastric junction distensibility identifies achalasia subgroup with manometrically normal esophagogastric junction relaxation. *Neurogastroenterol Motil* 2017;29:e12908.
- Smeets FG, Masclee AA, Keszthelyi D, Tjwa ET, Conchillo JM. Esophagogastric junction distensibility in the management of achalasia patients: relation to treatment outcome. *Neurogastroenterol Motil* 2015;27:1495-1503.
- O'Dea J. Dilation in Achalasia - is normal distensibility enough? *Neurogastroenterol Motil* 2016;28:153.
- Smeets FG, Masclee AA, Keszthelyi D, Tjwa ET, Conchillo JM. Dilation in achalasia - is normal distensibility enough: Author's reply. *Neurogastroenterol Motil* 2016;28:154-155.
- Familiari P, Gigante G, Marchese M, et al. EndoFLIP system for the intraoperative evaluation of peroral endoscopic myotomy. *United European Gastroenterol J* 2014;2:77-83.
- Ilcyszyn A, Hamaoui K, Cartwright J, Botha A. Intraoperative distensibility measurement during laparoscopic Heller's myotomy for achalasia may reduce the myotomy length without compromising patient outcome. *Dis Esophagus* 2016;29:455-462.
- Ngamruengphong S, von Rahden BH, Filser J, et al. Intraoperative measurement of esophagogastric junction cross-sectional area by impedance planimetry correlates with clinical outcomes of peroral endoscopic myotomy for achalasia: a multicenter study. *Surg Endosc* 2016;30:2886-2894.
- Nicodème F, Hirano I, Chen J, et al. Esophageal distensibility as a measure of disease severity in patients with eosinophilic esophagitis. *Clin Gastroenterol Hepatol* 2013;11:1101-1107.e1.
- Kwiatk MA, Hirano I, Kahrilas PJ, Rothe J, Luger D, Pandolfino JE. Mechanical properties of the esophagus in eosinophilic esophagitis. *Gastroenterology* 2011;140:82-90.
- Lin Z, Kahrilas PJ, Xiao Y, et al. Functional luminal imaging probe topography: an improved method for characterizing esophageal distensibility in eosinophilic esophagitis. *Therap Adv Gastroenterol* 2013;6:97-107.
- Chen JW, Pandolfino JE, Lin Z, et al. Severity of endoscopically identified esophageal rings correlates with reduced esophageal distensibility in

- eosinophilic esophagitis. *Endoscopy* 2016;48:794-801.
30. Pandolfino JE, Shi G, Curry J, Joehl RJ, Brasseur JG, Kahrilas PJ. Esophagogastric junction distensibility: a factor contributing to sphincter incompetence. *Am J Physiol Gastrointest Liver Physiol* 2002;282:G1052-G1058.
 31. Hill LD, Kozarek RA. The gastroesophageal flap valve. *J Clin Gastroenterol* 1999;28:194-197.
 32. Regan J, Walshe M, Rommel N, Tack J, McMahon BP. New measures of upper esophageal sphincter distensibility and opening patterns during swallowing in healthy subjects using EndoFLIP®. *Neurogastroenterol Motil* 2013;25:e25-e34.
 33. Malik Z, Sankineni A, Parkman HP. Assessing pyloric sphincter pathophysiology using EndoFLIP in patients with gastroparesis. *Neurogastroenterol Motil* 2015;27:524-531.
 34. Gourcerol G, Tissier F, Melchior C, et al. Impaired fasting pyloric compliance in gastroparesis and the therapeutic response to pyloric dilatation. *Aliment Pharmacol Ther* 2015;41:360-367.
 35. Snape WJ, Lin MS, Agarwal N, Shaw RE. Evaluation of the pylorus with concurrent intraluminal pressure and EndoFLIP in patients with nausea and vomiting. *Neurogastroenterol Motil* 2016;28:758-764.
 36. Kunwald P, Drewes AM, Kjaer D, et al. A new distensibility technique to measure sphincter of Oddi function. *Neurogastroenterol Motil* 2010;22:978-983, e253.
 37. Alqudah MM, Gregersen H, Drewes AM, McMahon BP. Evaluation of anal sphincter resistance and distensibility in healthy controls using EndoFLIP®. *Neurogastroenterol Motil* 2012;24:e591-e599.
 38. Gourcerol G, Granier S, Bridoux V, Menard JF, Ducrotte P, Leroi AM. Do endoflip assessments of anal sphincter distensibility provide more information on patients with fecal incontinence than high-resolution anal manometry? *Neurogastroenterol Motil* 2016;28:399-409.