

SHORT PAPER

Dermatological manifestation of pediatric multisystem inflammatory syndrome associated with COVID-19 in a 3-year-old girl

Dear Editor,

Pediatric multisystem inflammatory syndrome (PMIS) is an inflammatory condition in children, which usually involves fever and multiple organ failure associated with COVID-19. The condition may match some or all of the diagnostic criteria for Kawasaki disease (KD).¹ PMIS usually develops 1 month later in patients after the first exposure of acute COVID-19. The pathogenesis of PMIS was illness mediated by acquired immunity rather than direct viral injury. The antibody tests were positive in the cases with PMIS, but the results of COVID-19 polymerase chain reaction (PCR) were negative in most of the cases. According to the literature, PMIS has four different clinical presentations from Kawasaki-like illness syndrome to refractory vasodilatory shock (toxic shock syndrome like).²⁻⁵ Thus, due to all of these different clinical manifestations, the syndrome is not adequately diagnosed, and new information is added to the literature every day.

A 3-year-old girl presented to our institution's Emergency Department (ED) with fever and rash. The fever started 6 days ago, and 1 day before, a rash developed, which began on the trunk and spread over the extremities. On admission, body temperature was 39.5°C, a polymorphous rash varying from macular to maculopapular or morbilliform was detected (Figure 1A,B). The patient's face was mildly engorged with edema (Figure 1C), oropharynx hyperemic, and lips were red, swollen, and cracked. The eyes were swollen, and a nonpurulent eye discharge was noted. Lymph nodes were not enlarged, and the liver and spleen were not palpable. Initial blood chemistry results showed leukopenia (2900/ μ L), lymphopenia (900/ μ L), a hemoglobin level of 11 g/dL, thrombocytopenia (100 000/ mm^3), a high C-reactive protein (CRP) level of 121 mg/dL, a procalcitonin level of 9.2 ng/mL, average erythrocyte sedimentation rate (11 mm/h), a high D-dimer level of 2818 ng/mL, a high ferritin level of 520 ng/mL, a troponin level of 40 ng/mL, and albumin level of 3.2 g/dL, a high lactate dehydrogenase level of 725 U/L, a high level of Aspartate transaminase (AST) 125 units/L and a high level of 108 units/L. The patient's clinical findings in her first admission were not compatible with clinical signs (fever, fatigue, dry cough, anorexia, dyspnea), on vital parameters pulse oximetry saturation, and on radiological settings (X-ray, chest computed tomography scan) acute COVID-19. The patient was hospitalized with suspicion of viral exanthematous disease, KD, or PMIS. Transthoracic echocardiography demonstrated a notable increase in echogenicity of coroner vessels. On the fourth day of hospitalization, she was still feverish, well perfused (capillary refill of <3 seconds) but

tachycardia (140/min), and mild hypotension (90/48 mmHg) developed. Also, edema of hands or feet was observed. Thus, intravenous immunoglobulin and aspirin were initiated with a diagnosis of atypical KD. Throughout her hospitalization, the patient's white blood count increased (7800/ μ L), notably, and the patient's lymphopenia recovered and turned to normal (2200/ μ L). The patient's platelet count increased to 1 100 000/ mm^3 , and there was a notable reduction in her CRP. Ten days after the patient was discharged from the hospital, desquamation started throughout her fingertips. Elevated D-dimer level, troponin, ferritin, a low level of platelet, a low albumin level, and lymphopenia were signs of PMIS, and also, COVID-19 PCR was negative in our case. Persistent fever, mucosal findings, echogenicity of coroner vessels, and hypotension led us to think that the clinical presentation could be Kawasaki-like illness as a subtype of with PMIS associated with COVID-19.

Many epidemiologic data suggest that KD is caused or triggered by a transmissible agent or agents. The role of COVID-19 in the pathogenesis of KD is unclear. However, during the ongoing pandemic, children with PMIS mimicking KD are shared from different centers. The case definition is persistent fever, inflammation (neutrophilia, elevated CRP, and lymphopenia) and evidence of single or multiorgan dysfunction (shock, cardiac, respiratory, renal, gastrointestinal, or neurological disorder).^{1-3,6-10} There are variables differences between typical KD and PMIS. Firstly, KD has high platelets but PMIS has low platelets. Secondly, IL-6 and ferritin elevated in PMIS and not KD. Thirdly, lymphopenia in PMIS but not seen in KD. Fourthly, lower albumin in PMIS than KD. Lastly, KD often with normal troponin but PMIS with elevated troponin.^{3-5,11}

The first scientific reports about the relationship between acute COVID-19 and skin involvement in children were reported from China, Italy, and Turkey. Cutaneous manifestations of the patients were chickenpox-like vesicles, erythematous rash, and widespread urticaria. All of these cutaneous manifestations were located in the trunk. Also, itching was low, and all of the lesions ameliorated within less than 5 days.^{3,11,12} The skin rash in our case was not the same as the reported cases of skin rashes patients with COVID-19; instead, it looked like the case in Kawasaki disease. In our case, the skin rash was polymorphous, varying from macular to maculopapular or morbilliform; however, it was never vesicular. It most began on the trunk and spread over the extremities in a few days. To the best of our knowledge, this is the first report of dermatological manifestations of PMIS associated with COVID-19 in a 3-year-old girl.

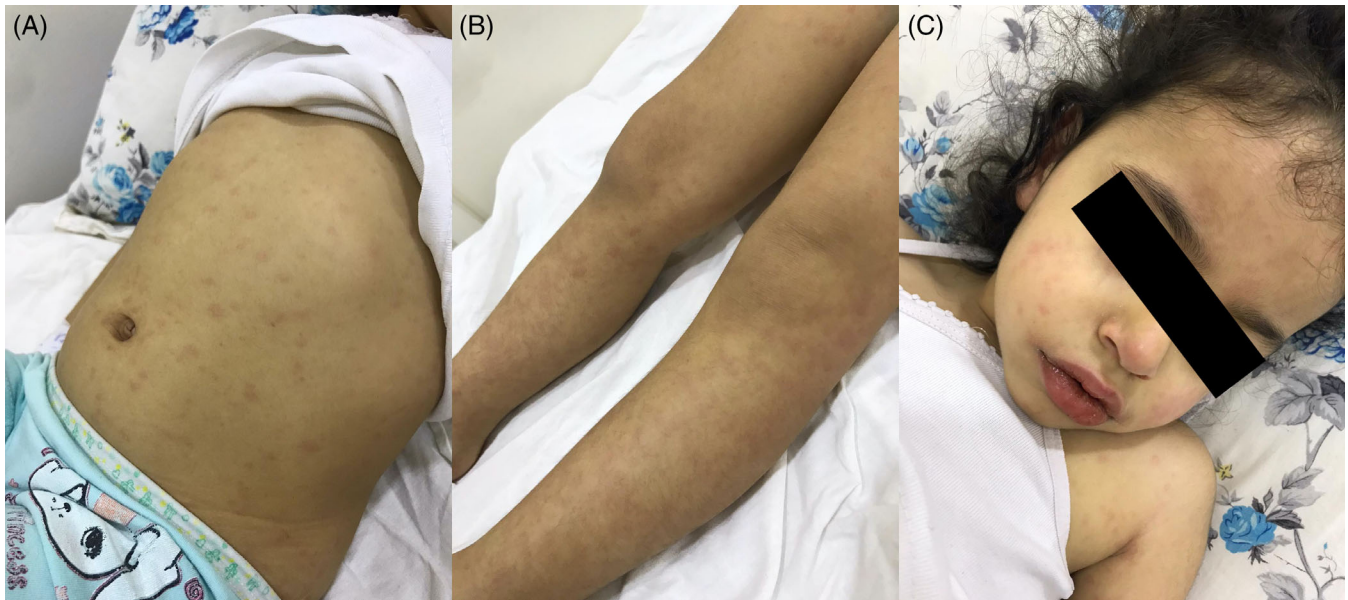


FIGURE 1 A,B, Figures showing polymorphous, varying from macular to maculopapular or morbilliform on the trunk and lower extremities. C, Figure showing lips were swelling, cracked, and the patient's face was mildly engorged with edema

ACKNOWLEDGMENTS








The authors certify that they have obtained all appropriate patient consent forms. In the form, the patients have given their consent for their images and other clinical information to be reported in the journal. The patients understand that their names and initials will not be published and due efforts will be made to conceal their identity, but anonymity cannot be guaranteed. This research received no specific grant from any funding agency or commercial or not-for-profit sectors.

CONFLICT OF INTEREST

The authors declare no potential conflicts of interest with respect to the research, authorship, and/or publication of this article.

AUTHOR CONTRIBUTIONS

All authors participated in creating content for the manuscript, editing, and provided final approval for submission. No undisclosed authors contributed to the manuscript.

Can Yilmaz Yozgat¹ 
 Selcuk Uzuner² 
 Burcu Bursal Duramaz³ 
 Yilmaz Yozgat⁴ 
 Ufuk Erenberk² 
 Akin Iscan⁵ 
 Ozden Turel³ 

¹Faculty of Medicine, Bezmialem Vakif University, Istanbul, Turkey

²Department of Pediatrics, Bezmialem Vakif University, Istanbul, Turkey

³Department of Pediatric Infectious Diseases, Bezmialem Vakif University, Istanbul, Turkey

⁴Department of Pediatric Cardiology, Bezmialem Vakif University, Istanbul, Turkey

⁵Department of Pediatric Neurology, Bezmialem Vakif University, Istanbul, Turkey

Correspondence

Can Yilmaz Yozgat, Faculty of Medicine, Bezmialem Vakif University, Adnan Menderes Bulvarı, Vatan Caddesi, 34093, Istanbul, Turkey.
 Email: yozgatyilmaz@gmail.com

ORCID

Can Yilmaz Yozgat  <https://orcid.org/0000-0001-7693-0261>

Selcuk Uzuner  <https://orcid.org/0000-0002-7133-5452>

Burcu Bursal Duramaz  <https://orcid.org/0000-0002-4098-947X>

Yilmaz Yozgat  <https://orcid.org/0000-0001-5164-8534>

Ufuk Erenberk  <https://orcid.org/0000-0002-5481-8356>

Akin Iscan  <https://orcid.org/0000-0001-5356-2646>

Ozden Turel  <https://orcid.org/0000-0002-6535-4147>

REFERENCES

1. The Royal College of Paediatrics and Child Health (2020). Paediatric multisystem inflammatory syndrome temporally associated with COVID-19. <https://www.rcpch.ac.uk/resources/guidance-paediatric-multisystem-inflammatory-syndrome-temporally-associated-covid-19>. Accessed May 14, 2020.
2. Erika, E. (2020). At least 85 kids across U.S. have developed rare, mysterious COVID-19-linked illness. <https://www.nbcnews.com/health/health-news/least-85-kids-across-u-s-have-developed-rare-mysterious-n1202186>. Accessed May 14, 2020.
3. Riphagen S, Gomez X, Gonzalez-Martinez C, Wilkinson N, Theocharis P. Hyperinflammatory shock in children during COVID-19 pandemic. *Lancet*. 2020;395(10237):1607-1608.

4. Haella, T. (2020). Novel inflammatory syndrome in children possibly linked to COVID-19. (2020). <https://www.medscape.com/viewarticle/930223>. Accessed May 14, 2020.
5. Recalcati S. Cutaneous manifestations in COVID-19: a first perspective. *J Eur Acad Dermatol Venereol*. 2020;34(5):e212-e213.
6. Bursal Duramaz B, Yozgat CY, Yozgat Y, Turel O. Appearance of skin rash in pediatric patients with COVID-19: three case presentations. *Dermatol Ther*. 2020;e13594.
7. Guan WJ, Ni ZY, Hu Y, et al. Clinical characteristics of coronavirus disease 2019 in China. *N Engl J Med*. 2020;382(18):1708-1720.
8. Licciardi F, Pruccoli G, Denina M, et al. SARS-CoV-2-induced Kawasaki-like hyperinflammatory syndrome: a novel COVID phenotype in children. *Pediatrics*. 2020;e20201711.
9. Deza Leon MP, Redzepi A, McGrath E, et al. COVID-19 associated pediatric multi-system inflammatory syndrome. *J Pediatric Infect Dis Soc*. 2020;piaa061.
10. Verdoni L, Mazza A, Gervasoni A, et al. An outbreak of severe Kawasaki-like disease at the Italian epicentre of the SARS-CoV-2 epidemic: an observational cohort study. *Lancet*. 2020. [https://doi.org/10.1016/S0140-6736\(20\)31103-X](https://doi.org/10.1016/S0140-6736(20)31103-X).
11. Harahsheh AS, Dahdah N, Newburger JW, et al. Missed or delayed diagnosis of Kawasaki disease during the 2019 novel coronavirus disease (COVID-19) pandemic. *J Pediatr*. 2020.
12. Bertonecchi D, Guidarini M, Della Greca A, et al. COVID19: potential cardiovascular issues in pediatric patients. *Acta Biomed*. 2020;91(2): 177-183.