

# Intra-abdominal Lymph Nodes: A Privileged Donor Site for Vascularized Lymph Node Transfer

Carrie K. Chu, MD, MS  
Mark V. Schaverien, MBCHB,  
MSc, MED, MD  
Edward I. Chang, MD  
Summer E. Hanson, MD, PhD  
Matthew M. Hanasono, MD  
Jesse C. Selber, MD, MPH

**Summary:** A variety of donor options for vascularized lymph node transfer for the surgical treatment of lymphedema have been described. Intra-abdominal harvest sites including the gastroepiploic nodes within the omental flap and the mesenteric node flap are distinguished from their extra-abdominal counterparts by the absent risk of iatrogenic donor site lymphedema and discrete scar location, as well as the ability to harvest up to 3 vascularized nodal packets from 1 donor site. However, there are also potential morbidities including hernia and intra-abdominal visceral injuries. Patient selection and flap harvest techniques are reviewed. (*Plast Reconstr Surg Glob Open* 2020;8:e2673; doi: [10.1097/GOX.0000000000002673](https://doi.org/10.1097/GOX.0000000000002673); Published online 25 March 2020.)

## INTRODUCTION

Lymphedema is a debilitating condition that may arise primarily or as a sequela of ablative therapies or traumatic injury. Although compression, massage, and physiotherapy remain the mainstay of treatment, emerging surgical therapies increasingly offer therapeutic alternatives to improve quality of life by lessening the intensity of medical regimens. Vascularized lymph node transfer (VLNT) is an option that delivers nodes from a separate anatomic location to restore lymphatic drainage of the affected extremity.<sup>1</sup> The ideal donor site provides functional lymphatic tissue while avoiding donor site morbidity including iatrogenic lymphedema.<sup>1</sup>

The peritoneal cavity houses a plethora of lymphatic tissues related to the absorptive and metabolic functions of the intra-abdominal organs. This article summarizes the options for VLNT contained within this privileged donor site as performed at our institution.

## PATIENT SELECTION

The elective nature of lymphedema surgery mandates careful assessment of the risk–benefit ratios associated with invasive interventions. Because intra-abdominal harvest carries potential risks of visceral injury and incisional hernia, appropriate patient selection is critical to minimize these untoward outcomes.<sup>2</sup> Relative contraindications include history of multiple previous laparotomies,

intra-abdominal radiation, disseminated intra-abdominal infections, and/or ventral hernia repair. Absolute contraindications include previous omentectomy, adhesive bowel obstruction, and mesenteric ischemia. Particular attention should be paid to foregut and colonic procedures that may disrupt the anatomy of the omentum or superior mesenteric axis. Increased body mass index correlates positively with abdominal wall morbidity risk; these patients may be better suited for a minimally invasive approach.<sup>3</sup> Surgeons should advise patients about the potential need for open conversion from minimally invasive surgery.

Although preoperative imaging can visualize the gastroepiploic and superior mesenteric pedicles, routine imaging is unnecessary. As there is no risk for donor site lymphedema with intra-abdominal harvest, preoperative lymphoscintigraphy is not indicated.

## TECHNIQUES

### Gastroepiploic Lymph Node Flap

Sustained by the right and left gastroepiploic vessels, the gastroepiploic nodes lie along the greater curvature of the stomach in continuity with the omentum. Beyond the discrete nodes, the omentum also hosts lymphatic tissues within “milky spots.” As the so-called policeman of the abdomen, the omentum serves the immunologic functions of containing and controlling infection.<sup>4</sup>

Harvest of the gastroepiploic nodes may be performed laparoscopically, robotically, or through open laparotomy. Minimally invasive approaches confer advantages including reduced postoperative pain, shorter scars, faster return of bowel function, reduced adhesions, and decreased

From the Department of Plastic Surgery, The University of Texas MD Anderson Cancer Center, Houston, Tex.

Received for publication November 4, 2019; accepted December 18, 2019.

Copyright © 2020 The Authors. Published by Wolters Kluwer Health, Inc. on behalf of The American Society of Plastic Surgeons. This is an open-access article distributed under the terms of the [Creative Commons Attribution-Non Commercial-No Derivatives License 4.0 \(CCBY-NC-ND\)](https://creativecommons.org/licenses/by-nc-nd/4.0/), where it is permissible to download and share the work provided it is properly cited. The work cannot be changed in any way or used commercially without permission from the journal.

DOI: [10.1097/GOX.0000000000002673](https://doi.org/10.1097/GOX.0000000000002673)

**Disclosure:** The authors have no financial interest to declare in relation to the content of this article.

Related Digital Media are available in the full-text version of the article on [www.PRSGlobalOpen.com](http://www.PRSGlobalOpen.com).

abdominal wall morbidity.<sup>5</sup> Laparoscopic harvest of the omentum is the first author's (C.K.C.) approach of choice for retrieval of the gastroepiploic nodes.<sup>6</sup> The senior author (J.C.S.) prefers a minilaparotomy for simultaneous assessment of the mesenteric nodes.

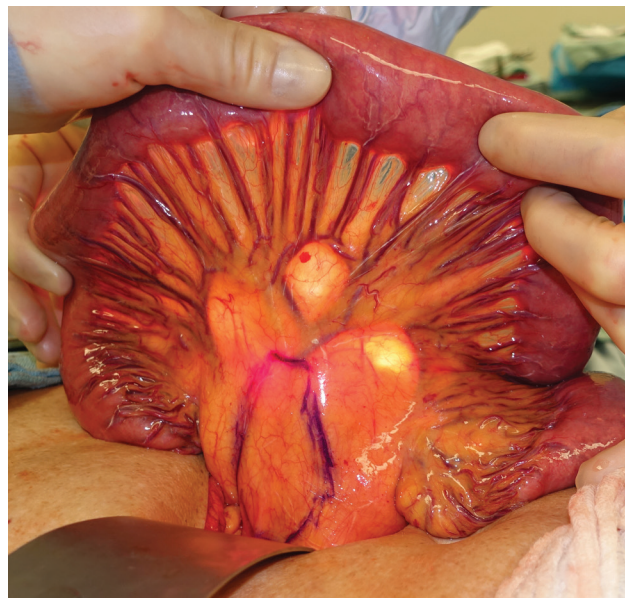
Either the right or left gastroepiploic pedicle may be selected. The right gastroepiploic pedicle is preferred if a single flap is required (See Video 1, [online], which demonstrates the laparoscopic-assisted harvest of a free omental flap for vascularized gastroepiploic lymph node transfer. One 10-mm and 3 5-mm trocars are used for access and dissection. The omentum is released from its attachments along the transverse colon and hepatic flexure. The plane between the transverse colonic mesentery and the posterior surface of the omentum is developed with care to avoid injury to the mesentery and middle colic vessels. The lesser sac is entered. The omentum is split, and the confluence of the left and right gastroepiploic pedicle is transected. Branches along the greater curvature are ligated. Just proximal to the pylorus, the right gastroepiploic artery and vein are isolated and divided. The midline incision is extended to 3–4 cm to facilitate flap retrieval. Pedicle length varies between 4 and 10 cm depending upon the dimensions of the gastroepiploic arcade preserved. The diameters of the artery and vein are typically 2–2.5 and 2.5–4 mm (personal experience). The flap may be vascularized in end-to-end or flow-through configuration for the artery, and the bidirectional valveless venous outflow enables end-to-end anastomoses to the superficial and/or deep venous systems of the extremities.<sup>7</sup> Flap size may be adjusted based on recipient site requirements; in particular, the omentum amply fills the concavity and contour deformity created by axillary dissection in breast-cancer-associated lymphedema.

### Mesenteric Lymph Node Flap

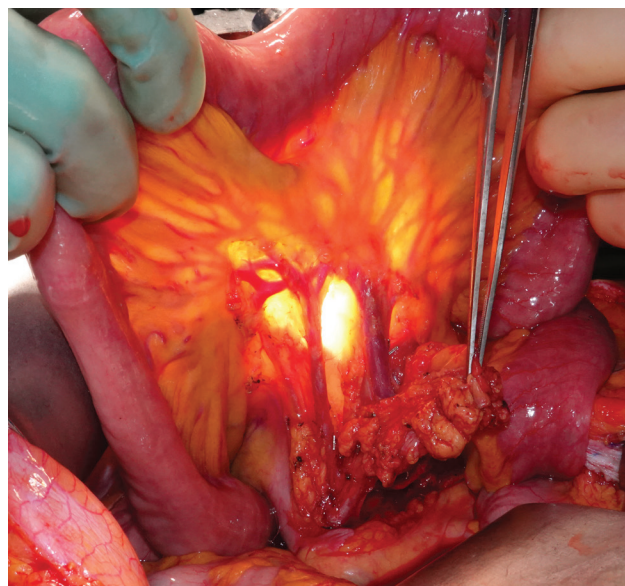
The small intestine mesentery contains an abundance of lymph nodes nourished by the sequential arcades of cascading branches of the superior mesenteric artery and vein. Knowledge of this anatomy has facilitated harvest of the free jejunal and supercharged jejunal flaps for pharyngoesophageal reconstruction while avoiding ischemic sequelae to the remaining bowel.

The peritoneal cavity is accessed via a 5- to 8-cm supra-umbilical midline laparotomy incision. The ligament of Treitz is identified. The mesentery is transilluminated for visualization of the vascular arcades. The second, third, or fourth mesenteric branch is selected with palpated confirmation of the associated node cluster. These branches are on average about 40 cm from the ligament of Treitz. Selection of these basins maximizes the length of the mesenteric branches from the source vessels to the intestinal serosa, thus increasing the versatility of the flap at the recipient site. The secondary arcade from which arises the marginal blood supply along the mesenteric border of the bowel is preserved, thereby avoiding intestinal ischemia. The flap harvest boundaries are marked, delineated laterally by the adjacent branches of the superior mesenteric vessels on either side of the target vessels, proximally by the root of the mesentery, and distally by the secondary

vascular arcade (Fig. 1). The anterior mesenteric visceral peritoneum is opened during flap harvest, whereas the posterior peritoneum remains intact (Figs. 2 and 3). Because dissection ends at the secondary arcade, no capillary bed connects the artery and vein. Without flow-through flaps, this scenario would result in blind-end vessels and subsequent clotting. For this reason, both artery and vein are designed as flow-through flaps; the artery is used as an

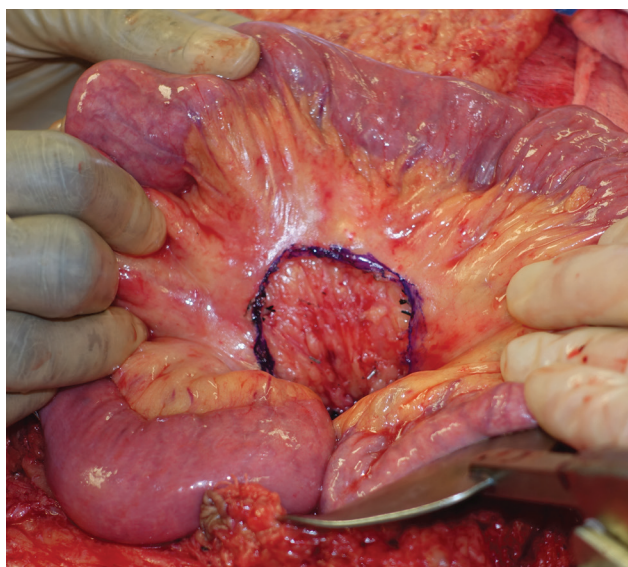


**Fig. 1.** The jejunal mesenteric vascularized lymph node flap harvest boundaries are marked in blue ink, delineated laterally by the adjacent branches of the superior mesenteric vessels on either side of the target vessels, proximally by the root of the mesentery, and distally by the secondary vascular arcade.

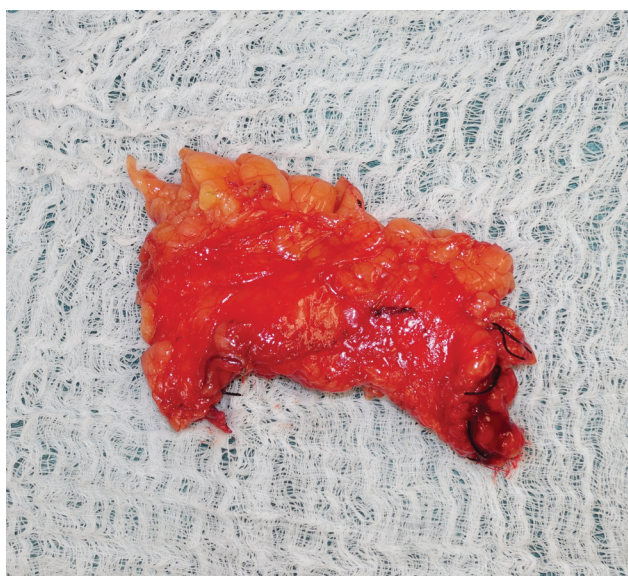

**Fig. 2.** The anterior mesenteric visceral peritoneum is opened for flap harvest and the tissue containing a large branch of the superior mesenteric vessels supplying the third part of the jejunum, as well as several large palpable lymph nodes, is mobilized.





**Fig. 3.** The posterior peritoneum remains intact to avoid the risk of internal hernia.



**Fig. 4.** The mesenteric branch with the greatest distance between the root and the secondary arcade is selected, with a resultant pedicle length following flap harvest of approximately 4–5 cm.

interposition into the radial artery at the level of the antecubital fossa and the vein is used to connect the cephalic and basilic veins. Connection of the deep and superficial systems may help mitigate the rheologic component of venous hypertension that is often a significant factor in lymphedema.<sup>8</sup> Typical arterial and venous pedicle diameters are 1.5–2 and 2–3.5 mm, respectively (Fig. 4).

### DISCUSSION

Modern-day plastic surgery has witnessed replacement of the free omental and jejunal flaps with fasciocutaneous perforator alternatives. However, the search for optimal

VLNT donor sites has led to recognition of the value of the intestinal mesentery and the omentum, both as hosts to a plethora of lymphatic tissue with well-defined blood supply.<sup>9,10</sup> Beyond the benefit of obviating iatrogenic donor-site lymphedema, the peritoneal cavity also offers the opportunity to harvest multiple flaps by splitting the omentum and/or procuring multiple mesenteric flaps for multilevel or multiextremity transfer. This feature substantially increases the potency and versatility in treating extremities with multilevel physiologic derangements. For instance, in patients with dermal backflow patterns on lymphoscintigraphy at the level of both the forearm and upper arm with a dissected and/or radiated axilla, the dual- or triple-level intervention may be designed with bypasses in the forearm, mesenteric nodes in the antecubital fossa, and omentum in the axilla. The potential for minimally invasive harvest exists for both flaps. At our institution, plastic surgeons routinely perform intra-abdominal flap harvest. It is incumbent upon plastic surgeons to maintain knowledge of intra-abdominal anatomy to ensure pedicle integrity and atraumatic node handling during harvest.

Given the relative novelty of these procedures, assessment of long-term efficacy and outcomes represent future directions for investigation. Although enteromesenteric resection and omentectomy have been well described for other indications, the long-term implications for abdominal sequelae such as obstruction, hernia, and peritonitis should be monitored.<sup>4</sup> Based on our recent institutional observations, however, with careful patient selection, the abdominal cavity with mesenteric and gastroepiploic lymph nodes represents a viable, safe, and privileged donor site for VLNT with discrete benefits and risks from extra-abdominal alternatives.<sup>8,10</sup>

Jesse C. Selber, MD, MPH

Department of Plastic Surgery, Unit 1488  
The University of Texas MD Anderson Cancer Center  
1515 Holcombe Boulevard  
Houston, TX 77030  
E-mail: JCSelber@mdanderson.org

### REFERENCES

- Schaverien MV, Badash I, Patel KM, et al. Vascularized lymph node transfer for lymphedema. *Semin Plast Surg.* 2018;32:28–35.
- Kraft CT, Eiferman D, Jordan S, et al. Complications after vascularized jejunal mesenteric lymph node transfer: a 3-year experience. *Microsurgery.* 2019;39:497–501.
- Puzziferri N, Austrheim-Smith IT, Wolfe BM, et al. Three-year follow-up of a prospective randomized trial comparing laparoscopic versus open gastric bypass. *Ann Surg.* 2006;243:181–188.
- Wang AW, Prieto JM, Cauvi DM, et al. The greater omentum - a vibrant and enigmatic immunologic organ involved in injury and infection resolution. *Shock.* 2019. Epub ahead of print. doi: 10.1097/SHK.0000000000001428.
- Buia A, Stockhausen F, Hanisch E. Laparoscopic surgery: a qualified systematic review. *World J Methodol.* 2015;5:238–254.
- Nguyen AT, Suami H. Laparoscopic free omental lymphatic flap for the treatment of lymphedema. *Plast Reconstr Surg.* 2015;136:114–118.
- Dayan JH, Voineskos S, Verma R, et al. Managing venous hypertension in vascularized omentum lymphatic transplant: restoring bidirectional venous drainage. *Plast Reconstr Surg.* 2018;141:326e–327e.

8. Schaverien MV, Hofstetter WL, Selber JC. Vascularized jejunal mesenteric lymph node transfer for lymphedema: a novel approach. *Plast Reconstr Surg.* 2018;141:468e–469e.
9. Coriddi M, Wee C, Meyerson J, et al. Vascularized jejunal mesenteric lymph node transfer: a novel surgical treatment for extremity lymphedema. *J Am Coll Surg.* 2017;225:650–657.
10. Nguyen AT, Suami H, Hanasono MM, et al. Long-term outcomes of the minimally invasive free vascularized omental lymphatic flap for the treatment of lymphedema. *J Surg Oncol.* 2017;115:84–89.