

# Asian Face Lift with the Composite Face Lift Technique

Chin-Ho Wong, M.Med.  
(Surg.), F.A.M.S. (Plast.Surg.)

Michael Ku Hung Hsieh,  
M.D., M.R.C.S.(Ed.), M.Med.  
(Surg.)

Bryan Mendelson,  
F.R.C.S.(Ed.), F.R.A.C.S.,  
F.A.C.S.

Singapore; and Toorak, Victoria,  
Australia



**Background:** The composite face lift is becoming increasingly popular following recent advances in understanding of facial anatomy that enable safe sub-superficial musculoaponeurotic system (SMAS) dissection. This article presents the authors' technique for composite face lift in Asian patients and reviews their experience and outcome with this procedure.

**Methods:** Composite face lifts were performed on 128 Asian patients between January of 2010 and June of 2020. Ninety-four were primary face lifts, and 34 were secondary or tertiary face lifts. The authors' surgical technique and adaptations for the specific requirements of Asian patients are described in detail. The mean follow-up was 26 months (range, 6 to 108 months). Fat grafting was an integral part of our procedure, with 95 percent having concomitant facial fat grafting with their face lift.

**Results:** Patients were followed up in accordance with a standardized schedule. The majority of patients reported high satisfaction with the aesthetic outcome of the technique, with natural, long-lasting results. The face lift plane of dissection is through the facial soft-tissue spaces, which provide atraumatic sub-SMAS access with precise release of the intervening retaining ligaments for effective flap mobilization. By emphasizing tension on the composite flap with no tension on the skin closure, the scars were discrete in the great majority of patients. Complications were few, with no hematomas or skin flap necrosis. The temporary nerve injury rate was 1.5 percent, with no patient having a permanent nerve injury.

**Conclusion:** The composite face lift is an ideal technique for Asian patients, as it delivers natural, long-lasting results; a quick recovery; and high patient satisfaction. (*Plast. Reconstr. Surg.* 149: 59, 2022.)

**CLINICAL QUESTION/LEVEL OF EVIDENCE:** Therapeutic, IV.

The face lift in Asian patients is a unique procedure because of the differences in the skeletal structure and soft-tissue quality of Asian patients compared to white patients. Accordingly, the performance of face lift techniques developed primarily for white patients may be different in Asian patients.<sup>1-11</sup> These techniques have to be modified and adapted for the

Asian anatomy and tissue characteristics. Many techniques have been used in Asian face lifts.<sup>12-17</sup> In general, these techniques may be divided into two broad categories: (1) superficial techniques that dissect only above the superficial musculoaponeurotic system (SMAS) and (2) deep plane techniques that require sub-SMAS dissection. The

From *W Aesthetic Plastic Surgery*; the Department of Plastic Reconstructive and Aesthetic Surgery, Singapore General Hospital; and the Centre for Facial Plastic Surgery.

Received for publication January 15, 2021; accepted July 13, 2021.

Copyright © 2021 The Authors. Published by Wolters Kluwer Health, Inc. on behalf of the American Society of Plastic Surgeons. All rights reserved. This is an open-access article distributed under the terms of the [Creative Commons Attribution-Non Commercial-No Derivatives License 4.0 \(CCBY-NC-ND\)](#), where it is permissible to download and share the work provided it is properly cited. The work cannot be changed in any way or used commercially without permission from the journal.

DOI: 10.1097/PRS.0000000000008686

**Disclosure:** The authors have no financial interest to declare in relation to the content of this article.

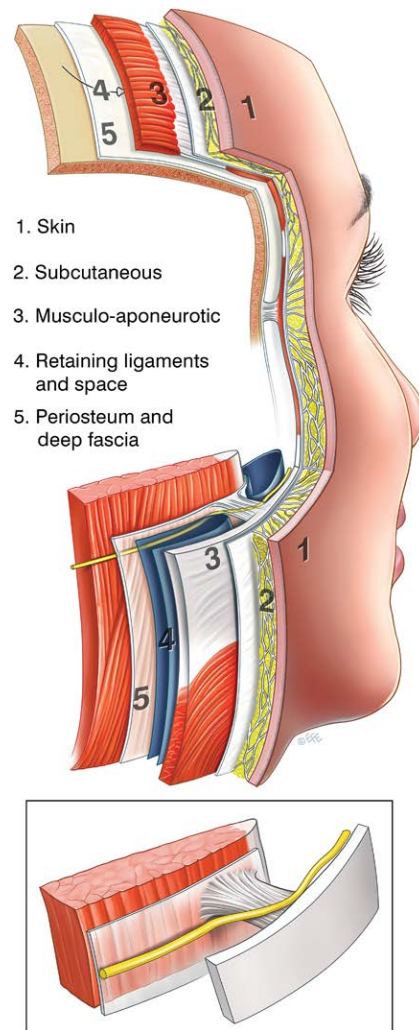
Related digital media are available in the full-text version of the article on [www.PRSGlobal.com](http://www.PRSGlobal.com).

A Video Discussion by Alan Matarasso, M.D., accompanies this article. Go to [PRSGlobal.com](http://PRSGlobal.com) and click on "Video Discussions" in the "Digital Media" tab to watch.

composite face lift belongs to the latter group of procedures that involve juxtafacial nerve dissection. Understandably, while a profoundly powerful technique, the potential risks of nerve injury remain a significant deterrent to surgeons in adopting this approach. However, the composite face lift technique has experienced a resurgence in popularity recently because of improved understanding of the surgical anatomy, which allows for greater safety in performing the procedure.<sup>18</sup> The composite face lift has certain inherent characteristics and technical features that make it ideal for Asian patients. This article reports our experience with the composite face lift for Asian patients.

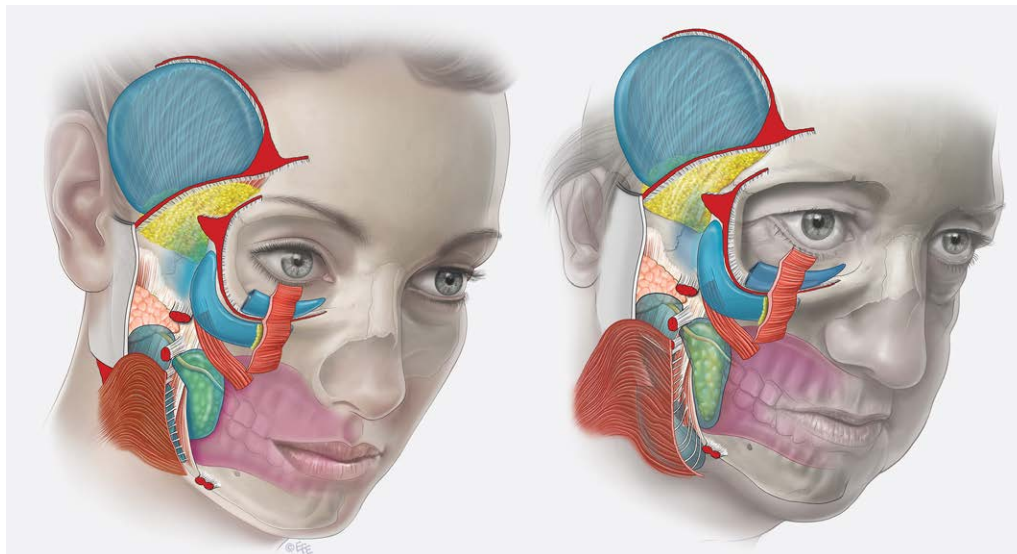
### APPLIED ANATOMY OF THE FACE FOR COMPOSITE FACE LIFT

The soft tissues of the face and neck are constructed in five concentric layers: (1) skin, (2) subcutaneous fat, (3) the musculoaponeurotic layer, (4) the loose areolar layer, and (5) deep fascia or periosteum. These five layers, as summarized by the mnemonic SCALP, are bound together and supported by a system of facial retaining ligaments (Fig. 1).<sup>19,20</sup> Functionally, however, the face is divided into two fascial layers, the superficial and deep fascia, with the muscle of facial expression located in the superficial fascia, while the muscles of mastication and the associated glandular structures (e.g., the parotid gland) are located under the deep fascia.<sup>21</sup> The superficial fascia is made up of the outer three layers: skin, subcutaneous layer, and the musculoaponeurotic layer bounded together by the retaining ligaments. The musculoaponeurotic layer (layer 3) is the SMAS in the lateral cheeks, orbicularis oculi in the periorbital area, and platysma in the anteromedial lower face and neck.<sup>22</sup> The deep fascia (layer 5) is the periosteum and deep facial layers covering the muscle of mastication, the temporalis, and masseter. The loose areolar layer (layer 4) is for the most part a gliding plane that allows the superficial fascia to glide and hence move freely over the deep fascia. A series of facial soft-tissue spaces, from the lateral cheek to the neck (i.e., prezygomatic, upper and lower premasseter, and subplatysmal spaces) located within layer 4, are designed for this purpose.<sup>19,23</sup> Because of the inherent mobility of this plane, it is the anatomical location most predisposed to laxity and sagging with aging (Fig. 2). Accordingly, it is also the location that, when directly tightened, results in the most natural restoration of the contours of youth. The composite face lift is an approach that dissects in layer



**Fig. 1.** The face is constructed of five basic soft-tissue layers. These five layers are bound together by a system of retaining ligaments that secures the soft tissues to the facial skeleton and deep fascia. The outer three layers function as a single unit, a composite flap that is the superficial fascia. Layer 4 contains the gliding plane in the form of soft-tissue spaces alternating with areas of fixation provided by the retaining ligaments. This facilitates movement of the superficial fascia independent of the underlying deep fascia. Surgically, this is the “ideal” plane for dissection because it is avascular, may be opened bluntly with minimal trauma, and is safe, as it is devoid of any vital structures. Accordingly, it is the plane of dissection in our composite face lift technique. The facial nerve branches travel through layer 4, where they remain outside the spaces. They ascend to layer 3 in close relationship with the retaining ligaments. These are locations where the nerves are at risk of injury (*insert*) (© EFE).

4, through the facial soft-tissue spaces (the gliding plane), with precise release of the retaining ligaments in layer 4 to allow for tightening of the superficial fascia as a single composite from the underside of the composite flap.



**Fig. 2.** Layer 4 is the natural gliding plane between the composite superficial fascia and the deep fascia and the masticatory apparatus below. In youth, this layer, while allowing for mobility, is firm and taut (*left*). With aging, because of the predisposition for laxity and tissue relaxation, expansion and sagging develop over the roof of the facial soft-tissue spaces (*right*). Accordingly, as this is the main anatomic site of laxity that develops with aging, directly tightening the superficial fascia is the most effective and logical way to perform the face lift. This also delivers the most natural and harmonious facial rejuvenation by restoring the superficial fascia to its location in youth (© EFE).

### SURGICAL TECHNIQUE

The skin incision is as shown in [Figure 3](#) (*above, left*). In the face, a line for the deep plane entry is marked, extending from the lateral canthus to the angle of the mandible. In the neck, the key point is marked. This key point, usually located along the uppermost neck crease at or slightly anterior to the angle of the mandible,<sup>24,25</sup> is the location on the neck that, when traction is applied, will optimally lift the submental and neck areas simultaneously. Subcutaneous dissection is performed to these markings only to the extent necessary to access these deep plane entry points. Visually, the posterior border of platysma in the lower face and neck and the lateral border of the orbicularis oculi marks the anterior limit of the subcutaneous dissection. [See [Video 1 \(online\)](#), which shows skin incisions and limited subcutaneous dissection, only to the extent necessary to access the sub-SMAS dissection plane.]

Facial sub-SMAS dissection is performed with a three-step approach. This is initiated with entrance into the lower premasseter space, as this is easiest to access, being the largest and most distinct soft-tissue space in the face.<sup>26</sup> An initial 2-cm incision at 10 mm above the angle of mandible along the planned SMAS incision line is made with a no. 15 blade. The space is bluntly opened using vertical spreading of the Metzenbaum scissors. Correct

entrance into the lower premasseter space is confirmed by visualization of fibers of the masseter on the floor of the space and fibers of the platysma in the roof of the space. Once these landmarks are visualized, the space is bluntly opened with a Trepstat dissector to its anterior boundary ([Fig. 3, above, right](#)). The SMAS incision is then extended upward to the body of the zygoma along the rest of the planned incision. The upper premasseter space located approximately 10 mm above the upper boundary of the lower premasseter space is then opened using the same dissection technique.<sup>27</sup> Once opened, the upper space is tented upward with a retractor, and the retaining ligaments in the interval separating the lower and upper spaces are sharply released near the roof of the space ([Fig. 3, center](#)). Dissection is then shifted to the upper extent of SMAS dissection over the body of the zygoma (step 2). The orbicularis oculi is bluntly elevated off the body of the zygoma, aiming the tip of the Metzenbaum scissors toward the lateral canthus. This then takes the dissection into the prezygomatic space. The prezygomatic space may be opened further with blunt finger dissection.<sup>28-30</sup> The next release is the zygomatic retaining ligaments inferior to the pre-zygomatic space (step 3). Using retractors in the prezygomatic space above and the premasseter spaces below, the intervening zygomatic ligaments are sharply released with

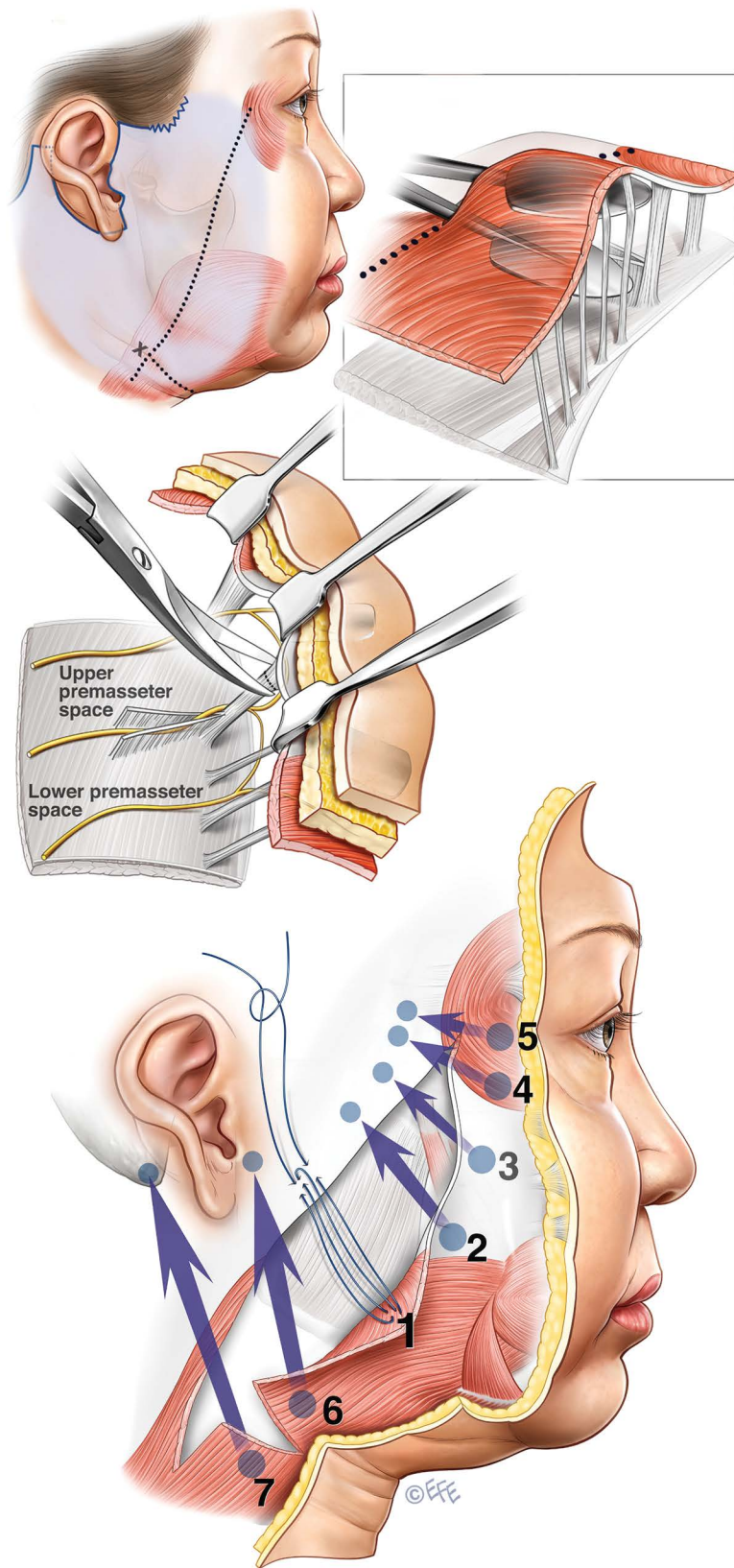


Fig. 3. (Continued).

scissors, staying closer to the roof of the spaces as the nerves are still running deep under the floor of the spaces at this location and under the zygomaticus major. Dissecting in this plane brings the release over the zygomaticus major toward the nasolabial fold.<sup>31,32</sup> Anteriorly, dissection may be stopped when the zygomatic ligament medial to zygomaticus major and the key masseteric ligaments more anteriorly and inferiorly have been released and one can see the branches of the facial nerves transitioning from deep to superficial in close association with the key retaining ligaments. The adequacy of release is then confirmed by noting good mobility of the superficial fascia, which results in correction of the jowl, corner of the mouth, and nasolabial folds and elevation of the lower eyelid with traction on the composite flap.

The neck dissection is then started by sharply releasing the cervical retaining ligaments along the posterior border of the platysma, mobilizing the platysma off the sternocleidomastoid muscle.<sup>33,34</sup> This allows the platysma to be lifted off the sternomastoid and deep cervical fascia with a Trepsat dissector in the subplatysma space, completing the usual extent of the surgical release. Buccal fat removal, if indicated, is performed. The capsule of the buccal fat pad is opened, and the excess buccal fat is gently teased out for excision. Care should be taken not to injure the buccal branch of the facial nerve, which runs over the capsule of the buccal fat pad.<sup>35</sup> [See Video 2 (online), which shows sub-SMAS dissection. To maximize safety, dissection was performed using a technique that bluntly opens the facial soft-tissue spaces followed by precisely releasing the retaining ligaments to effectively mobilize the composite face and neck lift flaps.]

Fixation of the composite flap to achieve the face lift may now be performed.<sup>36</sup> This is started at the lower face on the underside of the platysma to robustly fix the composite flap to the fixed SMAS

over the parotid gland. In the lower face, a more superolateral vector is used. As fixation progresses up to the zygoma, a more lateral vector is used (Fig. 3, below). In general, five fixation sutures are placed: from lower face to the zygoma, in the roofs of the lower premasseter, upper premasseter space, in the location of the zygomatic ligaments, and in the lateral roof of the prezygomatic space respectively, fixing into the fixed SMAS slightly posterior to cut edges of the SMAS incision. The highest fixation suture in the roof of the prezygomatic space delivers the cheek lift or “high-SMAS” effect. Ethibond 3-0 sutures (Johnson & Johnson Medical Devices, Irvine, Calif.) are used for this, and the sutures are tied firmly under strong tension.<sup>37</sup> The next fixation is the posterior platysma in the neck. The platysma is transected over the previously elevated tunnel, at the location of the key point, for approximately 4 cm, raising an inferior and a superior platysma flap. The superior flap is fixated with two figure-of-eight sutures to the Lore’s fascia anterior to the tragus.<sup>24</sup> The inferior platysma flap is fixated to the mastoid fascia with two fixation sutures. For the face, a second row of fixation is performed from the cut edge of the SMAS on the composite flap to the fixed SMAS just anterior to the ear. Using 3-0 Vicryl sutures (Ethicon, Inc., Raritan, N.J.), this second row reinforces the anterior fixation and also functions to obliterate dead space to prevent the occurrence of hematoma. [See Video 3 (online), which shows composite flap fixation in multiple vectors to achieve the face and neck lifts.] The excess skin flap is precisely trimmed and inset around the ear and the retroauricular and posterior prehairline for a tension-free skin closure. Structural fat grafting is done as needed at the end of the procedure using the Coleman technique.<sup>38–41</sup> No drains are used. [See Video 4 (online), which shows the skin flap inset and closure in a tension-free manner.]

**Fig. 3. (Continued).** (Above, left) Our skin incisions design. The dotted line marked the anterior extent of our subcutaneous dissection to reach our sub-SMAS entry locations. (Above, right) The facial soft-tissue space is a preferred plane of dissection, as it may be opened safely and atraumatically with vertical spreading of the Trepsat dissector. (Center) Release of the retaining ligament in the sub-SMAS plane should be performed with the ligaments under tension. Cutting should be performed near the roof of the spaces, as facial nerves are running under the floor of the spaces and out of harm’s way. (Below) Vector of fixation is more vertical in the neck and lower face. As we progress up the cheek, a more lateral vector is used. This optimally tightens the superficial fascia and avoids excessive skin bunching in the temporal area (© EFE).

## MATERIALS AND METHODS

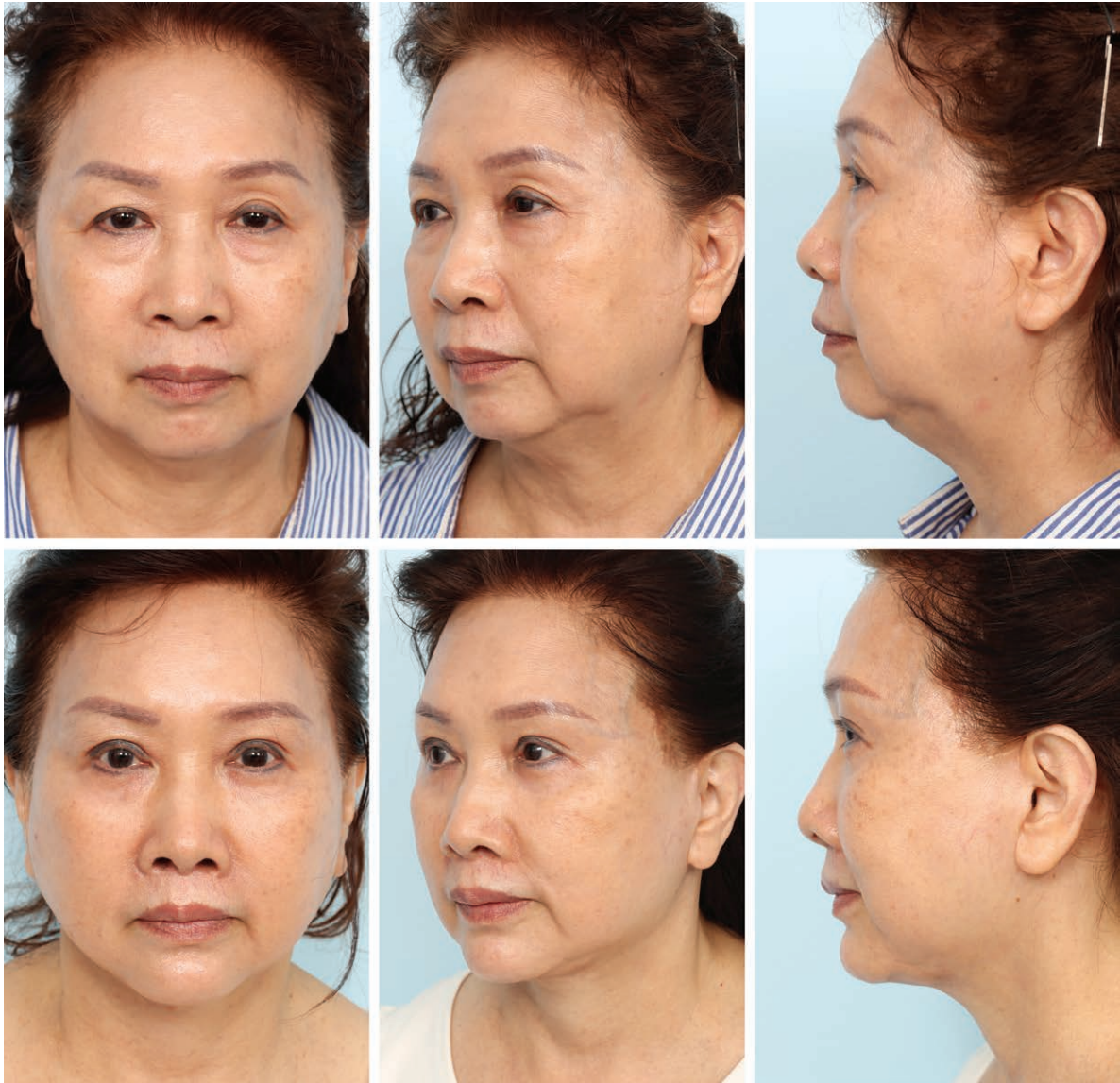From June of 2009 to June of 2020, 128 Asian patients underwent a composite face lift. Ninety-four patients underwent primary face lifts, and 34 underwent secondary or tertiary face lifts. The mean follow-up was 26 months (range, 6 to 108 months). The neck lift was achieved using the lateral approach only as described in our surgical technique in majority of our patients (102 patients, 79 percent). This was accompanied by a submental approach in 21 percent of our patients when indicated to enhance the surgical results in the neck. Patient satisfaction was assessed from 6

months after surgery. A simple, targeted survey spanning two domains, appearance and quality of life, was administered to patients. The ordinal scale ranged from dissatisfied, neutral, satisfied, and very satisfied for each parameter within a domain. An “overall satisfaction” rating based on the same ordinal scale allowed for a qualitative

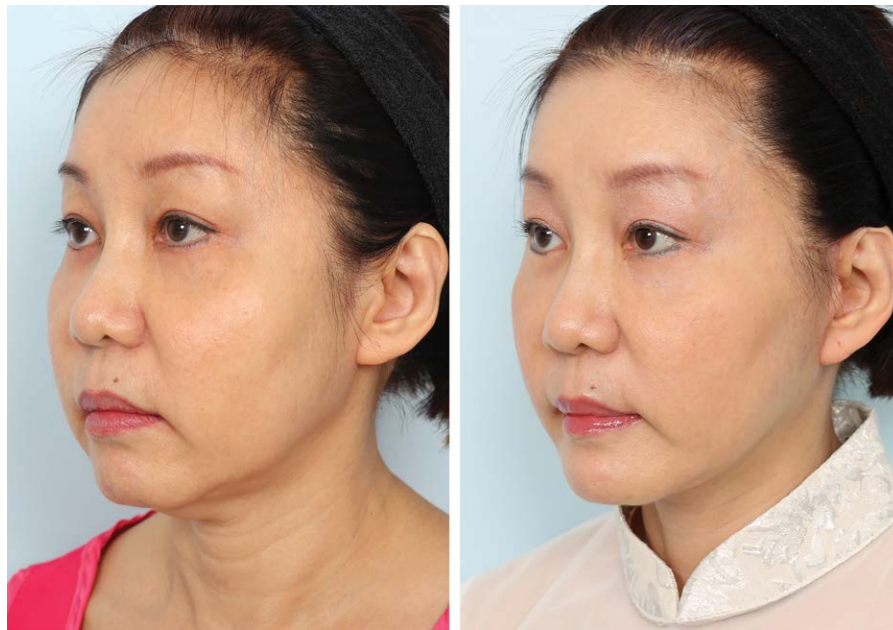measure of the aesthetic outcome from the patient’s perspective.

## RESULTS

Figures 4 and 5 show long-term results of our patients treated with this technique. (See



**Fig. 4.** (Above, left and below, left) This 63-year-old Chinese woman underwent a composite face lift with full face fat grafting. Twenty milliliters of fat were injected for her. At the same time, upper blepharoplasty with levator advancement for upper eyelid ptosis correction was performed. Additional procedures performed included an extended transconjunctival lower blepharoplasty (Wong CH, Mendelson B. Extended transconjunctival lower eyelid blepharoplasty with release of the tear trough ligament and fat redistribution. *Plast Reconstr Surg.* 2017;140:273–282), an upper lip lift, and a chin implant via an intraoral approach. No submental incision was performed. The patient is shown at one year after surgery. The composite face lift delivers a natural rejuvenation. (Above, center, and below, center) Three-quarter view of our patient. Note the restoration of the Ogee curve of youth and long-term correction of the jowl and jawline. (Above, right and below, right) Lateral views of our patient with good long-term results. The temporal hairline and retrotragal incisions healed well, being imperceptible when closed in a tension-free manner.



**Fig. 5.** (Left) This 57-year-old Chinese woman underwent a composite face lift with facial fat grafting. A chin implant was placed via the intraoral approach. No submental incision was performed. Fourteen cc of fat were injected into her centropalpebral areas. (Right) She is shown here at 2 years postoperatively. Note the restoration of the Ogee curve of youth and long-term correction of the jowl and jawline. (See Figure, Supplemental Digital Content 1, which shows the patient's frontal and side views, <http://links.lww.com/PRS/E760>.)

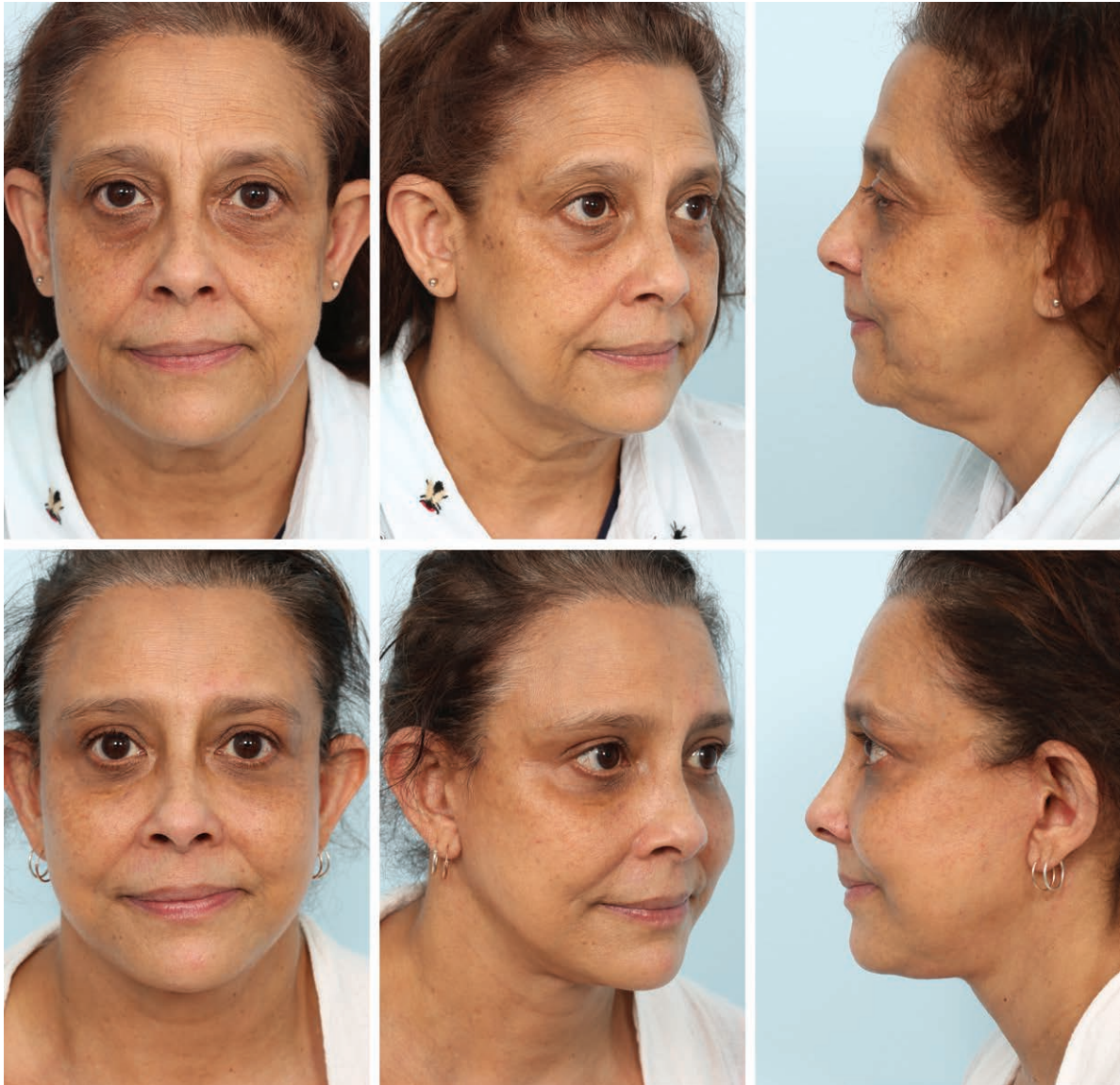**Figure, Supplemental Digital Content 1**, which shows the frontal preoperative and 2-year postoperative photographs of the patient presented in Fig. 5, <http://links.lww.com/PRS/E760>. See **Figure, Supplemental Digital Content 2**, which shows the side view before-and-after photographs of the patient. In addition to the good long-term results, scars are well hidden and acceptable. This is most predictably attainable with tension-free closure of the incisions, <http://links.lww.com/PRS/E761>.) Most patients (121 out of 128, 95 percent) had facial fat grafting performed together with their face lift. The mean volume of structural fat grafted was 29 cc (range, 14 to 46 cc of fat). Ninety-six percent of patients were satisfied or highly satisfied with their result. The scars healed well and were discrete. Only three patients, with strong tendency toward scarring, developed prominent hypertrophic scars after surgery. These were successfully treated in all three with intralesional steroid injections and laser treatments (Nd:YAG laser; Cutera, Brisbane, Calif.).<sup>42</sup>

The complication rates were low, compared to usual reported rates.<sup>43,44</sup> There were no hematomas requiring surgical drainage, nor was there any case of skin flap necrosis. Our nerve injury rate was low with a 1.5 percent temporary nerve injury rate. One patient developed a temporary

buccal branch neuropraxia, and one developed a temporal branch neuropraxia. Both recovered fully in within 4 weeks. No patient developed a permanent nerve injury.

## DISCUSSION

Asian patients seeking face lifts want natural results with no tell-tale signs of surgery. They are also most concerned about scarring and minimizing their down time. Face lift techniques used for Asian patients should deliver on these objectives. The anatomy of the Asian face is unique, with wider bizygomatic distance with a more abrupt or acute transition from the lateral to the anterior face over the body of the zygoma and a flatter or more retruded central face. This characteristic of the Asian face results in loss of effective mechanical lifting force in the anterior face for forces applied from the preauricular or temporal areas of the lateral face.<sup>12</sup> It is, therefore, mechanically necessary for the lifting and fixation to be applied more anteriorly in Asian patients. To optimally fulfill these requirements and circumvent the challenges peculiar to the Asian anatomy, our technique of composite face lift has been adapted to address these specific considerations. The advantages include the following: (1) the



**Fig. 6.** (Above, left and below, left) A 59-year old woman underwent a composite face lift with a temporal brow lift, upper lid blepharoplasty, extended transconjunctival eyebag removal (Wong CH, Mendelson B. Extended transconjunctival lower eyelid blepharoplasty with release of the tear trough ligament and fat redistribution. *Plast Reconstr Surg.* 2017;140:273–282), and full-face fat grafting. Forty-six cc of fat were grafted. No submental approach was performed for her. She is shown at 1 year postoperatively with natural and harmonious facial rejuvenation and discrete scars. (Above, center, and below, center) Three-quarter views of our patient. (Above, right, and below, right) Lateral views of our patient with good long-term results. The temporal hairline and retrotragal incisions healed well, being imperceptible when closed in a tension-free manner.

composite face lift restores the superficial fascia to its youthful location as tension is placed on the support layer of the face (i.e., the SMAS). (2) The results are profoundly rejuvenating and yet completely natural.<sup>19</sup> (3) The unnatural stretched and taut appearance that may be seen with more superficial procedures that rely on directly tightening the skin to achieve the desired lift is not seen with this technique. (4) With the composite face lift, because of the anatomical advantage of

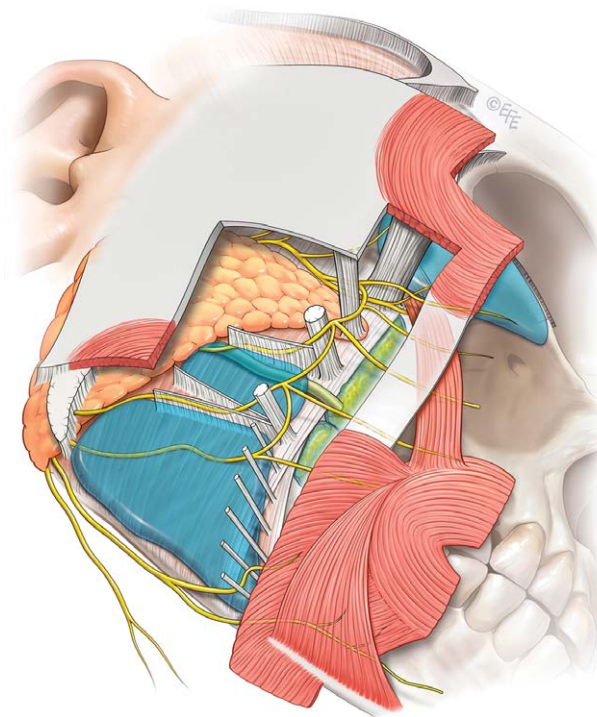
keeping the skin, subcutaneous tissue, and SMAS intact as a single composite flap, the thickness and effective strength of the SMAS may be completely preserved. The vascular supply of the composite flap is, therefore, more robust. This allows for greater tension on the skin flaps to lift the thicker and heavier tissues in Asian patients. This is in contrast to face lift techniques that either elevate the SMAS as an isolated flap or dissect on the surface of the SMAS, which may thin the



flap and hence reduce its ability to hold tension placed on it. Lifting and fixation of the composite flap—*independent of skin closure*—enable the skin to be closed in a tension-free manner. This provides the required tension-free condition for optimal skin healing and minimizes scarring.

Composite face lift dissection is performed in layer 4, the loose areolar plane that is the interface between the superficial and deep fascia.<sup>19</sup> Adequate release of the retaining ligaments is important to give the required mobility to the superficial fascia to achieve effective, long-lasting lifting of the flaps.<sup>36</sup> To maximize safety from nerve injury, the release of the retaining ligaments should be performed when they are under tension and at the level of the ligament that is furthest away from the path of the facial nerve. To achieve this, the sub-SMAS dissection is started by bluntly opening the facial soft-tissue spaces, as these spaces are devoid of any vital structures and, therefore, the safest areas to dissect.<sup>45</sup> This is then followed by retraction of the roof of the adjacent spaces to put the target retaining ligament under tension. The ligaments can then be precisely released closer to the roof of the space, while the nerves are protected, running close to the floor of the dissected space. With the three-step dissection approach as described (Fig. 7), the surgical release may be performed safely with minimal risks of nerve injury.<sup>46,47</sup>

We place the fixation sutures more anteriorly on the face. The mechanical advantage of this is that fixation is closer to the primary targets for correction (i.e., the jowl, nasolabial fold, and cheek). The strong lifting of the lower face with direct fixation of the platysma to the dense fascia over the parotid (the “fixed SMAS”) provides good contouring of the lower face and jowls. In the midcheek, direct tightening of the prezygomatic space effectively lifts the cheek over the prominence of the body of the zygoma.<sup>31</sup> The “vector” of the lift is determined on a case-by-case basis depending on the direction that provides the tissue with the most significant lifting and correction of the targeted areas of laxity.<sup>36,48</sup> In the neck and lower face, a more vertical lift is used, and as one progresses toward the body of the zygoma and lower eyelid, a gradual transition to a more superolateral vector is applied.<sup>7</sup> This is beneficial, as laxity develops to a different extent and directions in different areas of the face. In techniques that rely on a single vector, en-bloc lifting of the skin flaps, areas of suboptimal tightening, and pockets of laxity will develop, resulting in early relapse at these locations. This approach of tightening more



**Fig. 7.** This diagram illustrates the layer 4 (sub-SMAS) anatomy of the face. We perform the sub-SMAS release in a three-step approach. *Step 1* is dissection in the lower face, accessing the lower and upper premasseter spaces with release of the retaining ligaments that separate them. The lower premasseter space is the widest and easiest to access. This is followed by opening of the upper space then, with both spaces retracted, the retaining ligaments between them can be sharply released. Here, lower buccal branches of the facial nerve are running deep under the parotidomasseteric fascia, so the release of the retaining ligaments should therefore be done high, at the level of the roof of the soft-tissue spaces. *Step 2* directs the dissection to the upper extent of the release by blunt dissection under the orbicularis oculi and opening the prezygomatic space. Blunt finger dissection may be used to completely open the space (FAME, finger assister malar elevation, technique) toward the nasolabial folds. *Step 3* is the key step to sharply release the zygomatic retaining ligaments. As there are no facial soft-tissue spaces here, the release has to be done with sharp dissection. To do this safely, retractors are placed in the spaces, under the roof of the prezygomatic and premasseter spaces, above and below this area, respectively, so that the zygomatic ligaments are placed under tension. As the nerves are located in the floor of the dissection (under the parotidomasseteric fascia), release is performed high, closer to the roof of the spaces, releasing the zygomatic ligaments and taking the dissection over the zygomaticus major toward the nasolabial fold, keeping the nerves safely down on the floor of the dissection. This extent of release allows for the complete mobilization of the face composite flap.

anteriorly and using a gradually transitioning vector from the neck to the cheek allows for optimal tightening of the composite flap, while avoiding

the tendency to excessive skin bunching in the temporal region. Fixation is performed using braided, nonabsorbable, Ethibond sutures for greater strength of the fixation. The additional benefit of permanent sutures is that they serve as markers for location of the deep plane entry points in future secondary face lifts.<sup>37</sup>

The necks of Asian patients tend to hold up better, with aging with less skin laxity and sagging seen. For most of our patients (81 percent), the lateral approach alone to neck lifting, with platysma transection at the key point and suspension to the Lorre's and mastoid fascia as described above, is able to predictably deliver the desired neck lift for our Asian patients. We do perform the anterior/submental approach to the neck in selected patients to enhance our results in the neck. These include patients with very obtuse necks and who do not mind having an additional submental incision. In addition to deep anterior neck structures manipulation, an added benefit of the submental approach is that a chin implant, when needed, may be easily placed via this incision.

Facial fat grafting is an integral part of our procedure.<sup>38,39</sup> Fat grafting in Asian patients differs in quantity and locations of priority compared with white patients.<sup>49</sup> Asian patients, because of their fuller faces, generally require less volume of fat.<sup>40,41</sup> However, as with white patients, with aging, certain areas of the face lose projection and facial fullness. On average, we grafted 29 cc of fat in our patients. Considering the areas that we grafted, in the forehead the areas of deficiency are similar to those of white patients, with the temple, supraorbital ridge, the brow, and the forehead in general being the areas that required grafting. In the midface, however, the areas of priority are quite distinct. The areas of deficiency are the medial maxilla, piriform aperture, and nasolabial folds. The zygoma is generally much more prominent, so that much less graft volume is required here compared to white patients. That is, Asian patients require much more in the central mid-face and less in the lateral aspect of this area. In the lower face, the chin and pre-jowl areas were commonly grafted. The jawline and, specifically, the angle of the mandible are usually quite prominent and therefore do not commonly require grafting.

Finally, as Asian patients tend to bleed and bruise more, they develop more prolonged swelling. To minimize the down time and recovery following face lift surgery, minimizing bleeding and trauma associated with the surgery is key. From this perspective, the ideal plane of dissection is the gliding plane of level 4 (i.e., through the facial soft-tissue spaces).<sup>45</sup> By limiting the extent of the subcutaneous

dissection to only the extent necessary to access these spaces and subsequently excising a significant portion of the undermined skin subsequent to tightening the soft tissues, most of the skin flaps on the face and neck would have been dissected atraumatically in the plane of the facial soft-tissue spaces. With the composite face lift technique, most of our patients are able to gradually return to their social engagements in about 3 weeks after surgery.

*Chin-Ho Wong, M.Med. (Surg.), F.A.M.S. (Plast.Surg.)*

W Aesthetic Plastic Surgery  
06-28/29, Mount Elizabeth Novena Specialist Center  
38 Irrawaddy Road  
Singapore 329563  
[drwong@waesthetics.com](mailto:drwong@waesthetics.com)  
Facebook: chinho.wong.7  
Instagram: @wchinho1975

## PATIENT CONSENT

*Patients provided written consent for the use of their images.*

## REFERENCES

- Warren RJ, Aston SJ, Mendelson BC. Face lift. *Plast Reconstr Surg.* 2011;128:747e-764e.
- Tonnard P, Verpaele A, Monstrey S, et al. Minimal access cranial suspension lift: A modified S-lift. *Plast Reconstr Surg.* 2002;109:2074-2086.
- Baker DC. Minimal incision rhytidectomy (short scar face lift) with lateral SMASectomy: Evolution and application. *Aesthet Surg J.* 2001;21:14-26.
- Stuzin JM, Baker TJ, Gordon HL, Baker TM. Extended SMAS dissection as an approach to midface rejuvenation. *Clin Plast Surg.* 1995;22:295-311.
- Jacono AA, Bryant LM, Ahmedli NN. A novel extended deep plane facelift technique for jawline rejuvenation and volumization. *Aesthet Surg J.* 2019;39:1265-1281.
- Hamra ST. Composite rhytidectomy. *Plast Reconstr Surg.* 1992;90:1-13.
- Jacono AA, Parikh SS. The minimal access deep plane extended vertical facelift. *Aesthet Surg J.* 2011;31:874-890.
- Marten TJ. High SMAS facelift: Combined single flap lifting of the jawline, cheek, and midface. *Clin Plast Surg.* 2008;35:569-603, vi.
- Marten TJ. Facelift. Planning and technique. *Clin Plast Surg.* 1997;24:269-308.
- Rohrich RJ, Ghavami A, Constantine FC, Unger J, Mojallal A. Lift-and-fill face lift: Integrating the fat compartments. *Plast Reconstr Surg.* 2014;133:756e-767e.
- Hamra ST. Building the composite face lift: A personal odyssey. *Plast Reconstr Surg.* 2016;138:85-96.
- Park DM. Extended SMAS facelift. *J Korean Soc Aesthetic Plast Surg.* 2007;13:167-174.
- Ryu MH, Moon VA. High superficial musculoaponeurotic system facelift with finger-assisted facial spaces dissection for Asian patients. *Aesthet Surg J.* 2015;35:1-8.
- Ryu MH, Moon VA, Yin W. The inclusion of orbicularis oculi muscle in the SMAS flap in Asian facelift: Anatomical consideration of orbicularis muscle and zygomaticus major muscle. *Aesthetic Plast Surg.* 2018;42:471-478.

15. Wang R, Yang J, Guo K, et al. Asian facelift technique refinement with high patient satisfaction: FACE-Q report. *Ann Plast Surg*. 2018;81(6S):1.
16. Onizuka T, Hosaka Y, Miyata M, Ichinose M. Our mini-face-lift for Orientals. *Aesthetic Plast Surg*. 1995;19:49–58.
17. Bergeron L, Chen YR. The Asian face lift. *Semin Plast Surg*. 2009;23:40–47.
18. Melbourne Advanced Facial Anatomy Course. Available at: <https://mafac.com.au>. Accessed November 9, 2021.
19. Mendelson BC, Wong CH. Anatomy of the aging face. In: Neligan PC, Warren RJ, eds. *Plastic Surgery Volume 2: Aesthetic*. 3rd ed. Elsevier; 2012:78–92.
20. Furnas DW. The retaining ligaments of the cheek. *Plast Reconstr Surg*. 1989;83:11–16.
21. Stuzin JM, Baker TJ, Gordon HL. The relationship of the superficial and deep facial fascias: Relevance to rhytidectomy and aging. *Plast Reconstr Surg*. 1992;89:441–449; discussion 450.
22. Mitz V, Peyronie M. The superficial musculo-aponeurotic system (SMAS) in the parotid and cheek area. *Plast Reconstr Surg*. 1976;58:80–88.
23. Mendelson BC. Anatomic study of the retaining ligaments of the face and applications for facial rejuvenation. *Aesthetic Plast Surg*. 2013;37:513–515.
24. Labbé D, Franco RG, Nicolas J. Platysma suspension and platysmaplasty during neck lift: Anatomical study and analysis of 30 cases. *Plast Reconstr Surg*. 2006;117:2001–2007; discussion 2008.
25. Labbé D, Rocha CSM, de Souza Rocha F. Cervico-mental angle suspensory ligament: The keystone to understand the cervico-mental angle and the ageing process of the neck. *Aesthetic Plast Surg*. 2017;41:832–836.
26. Mendelson BC, Freeman ME, Wu W, Huggins RJ. Surgical anatomy of the lower face: The premasseter space, the jowl, and the labiomandibular fold. *Aesthetic Plast Surg*. 2008;32:185–195.
27. Mendelson BC, Wong CH. Surgical anatomy of the middle premasseter space and its application in sub-SMAS face lift surgery. *Plast Reconstr Surg*. 2013;132:57–64.
28. Aston SJ. Commentary on: High superficial musculoaponeurotic system facelift with finger-assisted facial spaces dissection for Asian patients. *Aesthet Surg J*. 2015;35:9–10.
29. Mendelson BC, Jacobson SR. Surgical anatomy of the mid-cheek: Facial layers, spaces, and the midcheek segments. *Clin Plast Surg*. 2008;35:395–404; discussion 393.
30. Muzaffar AR, Mendelson BC, Adams WP Jr. Surgical anatomy of the ligamentous attachments of the lower lid and lateral canthus. *Plast Reconstr Surg*. 2002;110:873–84; discussion 897.
31. Mendelson BC. Correction of the nasolabial fold: Extended SMAS dissection with periosteal fixation. *Plast Reconstr Surg*. 1992;89:822–33; discussion 834.
32. Barton FE Jr. The SMAS and the nasolabial fold. *Plast Reconstr Surg*. 1992;89:1054–7; discussion 1058.
33. Jacono AA, Malone MH. Characterization of the cervical retaining ligaments during subplatysmal facelift dissection and its implications. *Aesthet Surg J*. 2017;37:495–501.
34. Pelle-Ceravolo M, Angelini M, Silvi E. Treatment of anterior neck aging without a submental approach: Lateral skin-platysma displacement, a new and proven technique for platysma bands and skin laxity. *Plast Reconstr Surg*. 2017;139:308–321.
35. Sung HM. The use of buccal fat to improve the effect of facelift surgery in Asian patients. *Plast Reconstr Surg Glob Open* 2020;8:e3139.
36. Mendelson BC. Surgery of the superficial musculoaponeurotic system: Principles of release, vectors, and fixation. *Plast Reconstr Surg*. 2002;109:824–825.
37. Huggins RJ, Freeman ME, Kerr JB, Mendelson BC. Histologic and ultrastructural evaluation of sutures used for surgical fixation of the SMAS. *Aesthetic Plast Surg*. 2007;31:719–724.
38. Coleman SR. Facial augmentation with structural fat grafting. *Clin Plast Surg*. 2006;33:567–577.
39. Coleman SR. Structural fat grafting: More than a permanent filler. *Plast Reconstr Surg*. 2006;118(3 Suppl):108S–120S.
40. Marten TJ, Elyassnia D. Fat grafting in facial rejuvenation. *Clin Plast Surg*. 2015;42:219–252.
41. Marten T, Elyassnia D. Facial fat grafting: Why, where, how, and how much. *Aesthetic Plast Surg*. 2018;42:1278–1297.
42. Koike S, Akaishi S, Nagashima Y, Dohi T, Hyakusoku H, Ogawa R. Nd:YAG laser treatment for keloids and hypertrophic scars: An analysis of 102 cases. *Plast Reconstr Surg Glob Open* 2014;2:e272.
43. Baker DC. Complications of cervicofacial rhytidectomy. *Clin Plast Surg*. 1983;10:543–562.
44. Jacono AA, Alemi AS, Russell JL. A meta-analysis of complication rates among different SMAS facelift techniques. *Aesthet Surg J*. 2019;39:927–942.
45. Wong CH, Mendelson B. Midcheek lift using facial soft-tissue spaces of the midcheek. *Plast Reconstr Surg*. 2015;136:1155–1165.
46. Roostaeian J, Rohrich RJ, Stuzin JM. Anatomical considerations to prevent facial nerve injury. *Plast Reconstr Surg*. 2015;135:1318–1327.
47. Stuzin JM, Rohrich RJ. Facial nerve danger zones. *Plast Reconstr Surg*. 2020;145:99–102.
48. Jacono AA, Bryant LM, Alemi AS. Optimal facelift vector and its relation to zygomaticus major orientation. *Aesthet Surg J*. 2020;40:351–356.
49. Mendelson B, Wong CH. Changes in the facial skeleton with aging: Implications and clinical applications in facial rejuvenation. *Aesthetic Plast Surg*. 2012;36:753–760.