

## A Successful Healthy Childbirth in a Case of Total Globozoospermia with Oocyte Activation by Calcium Ionophore

Nilay Karaca<sup>1\*</sup>, Yasam Kemal Akpak<sup>2</sup>, Serkan Oral<sup>3</sup>, Tugce Durmus<sup>1</sup>, Rabiye Yilmaz<sup>1</sup>

1- TDV 29 Mayıs Hospital, Department of Assisted Reproduction, Istanbul, Turkey

2- Ankara Mevki Military Hospital, Department of Obstetrics and Gynecology, Ankara, Turkey

3- LIV Hospital, Department of Assisted Reproduction, Istanbul, Turkey

### Abstract

**Background:** Globozoospermia is a rare (incidence of 0.1% among andrological patients) and poorly understood condition, but a severe disorder in male infertility. This case report detailed the course of treatment and protocol of a patient with type 1 globozoospermia using Intracytoplasmic Sperm Injection (ICSI) and oocyte activation by calcium ionophore, which yielded conception and birth of a healthy baby after six previous unsuccessful attempts, using ICSI alone.

**Case Presentation:** A 39-year-old male with normal findings on routine examination presented to TDV 29 Mayıs Hospital, Assisted Reproduction Unit (ART) with his 37-year-old wife. Her examination was also within normal limits and ovulatory cycle was regular. The male's diagnostic screening revealed normal karyotype (46, XY) and no Y-microdeletion. However, the spermogram was abnormal; sperm count of 14 million/ml with 35% active motility and 100% morphologically abnormal sperm, indicating globozoospermia. Ovarian stimulation was provided using classic long down-regulation protocol and 13 MII oocytes were collected. Next, calcium ionophore was applied following the ICSI procedure to improve the chances for fertilization. The case report compared quantitative procedural and diagnostic screening data, and fertilization rates. On day 5, two grade 1 blastocysts out of 5 embryos were transferred, yielding positive beta-human chorionic gonadotropin (beta hCG), and ultimately a healthy delivery.

**Conclusion:** ICSI with assisted oocyte activation by calcium ionophore may overcome male infertility where there is total globozoospermia.

**Keywords:** Calcium ionophore, Globozoospermia, Intracytoplasmic sperm injection (ICSI), Morphologically abnormal sperm.

**To cite this article:** Karaca N, Akpak YK, Oral S, Durmus T, Yilmaz R. A Successful Healthy Childbirth in a Case of Total Globozoospermia with Oocyte Activation by Calcium Ionophore. *J Reprod Infertil.* 2015;16(1):116-120.

\* Corresponding Author:  
Nilay Karaca, Mailing  
Merkez Efendi Mah.  
Mevlana Cad. 94D-41,  
Zeytinburnu, Istanbul,  
34200 Turkey  
E-mail:  
karacanilay@hotmail.com

Received: Oct. 27, 2014

Accepted: Jan. 13, 2015

### Introduction

Infertility is described as inability to conceive after one year of unprotected intercourse. Currently, the condition affects about 15% of couples. In classification of infertility, 1/3 of infertility cases can be attributed to males, 1/3 to females and 1/3 have no identifiable causes (1). Common problems in male related infertility are sperm count, motility or structural abnormalities. One of the rare and severe causes of structural abnormality is globozoospermia. This defect is

detected in less than 0.1% of patients admitted for andrologic screening (2).

Two types of globozoospermic sperm have been described in the literature. Type 1 is classified as total globozoospermia owing to the absence of spermatozoa with an acrosome in the spermatozoon. Type 2 is classified as partial globozoospermia in that the ratio of round-headed spermatozoa is less than 100% (*i.e.*, 20-90%) in a semen sample and acrosomal vesicles are present in the rest of

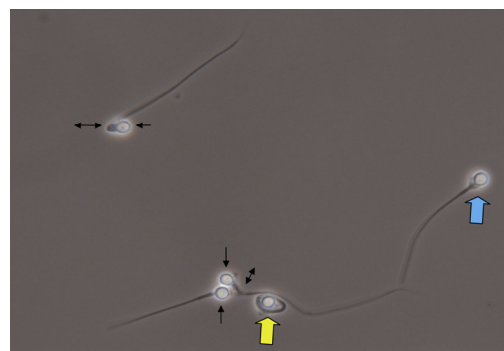
the spermatozoa (3). The pathogenesis of globozoospermia syndrome is not yet clear. However, findings from recent studies suggest disturbance in spermiogenesis, which appears to be induced by a genetic disorder like homozygous deletion in DYP19L2, homozygous missense PICK1 mutation, or mutation in a testis specific gene such as SPATA 16 (4-7). In 1994, Lundin et al. (8) reported the first successful pregnancy in globozoospermic patient using ICSI; however, most studies continued reporting very low fertilization rates for cases in which ICSI was performed on globozoospermic patients. It is suggested that assisted oocyte activation with Ca<sup>++</sup> ionophore and electrical or mechanical stimulation might increase fertilization rates (9-11).

This case report detailed the course of treatment and protocol of a patient with type 1 globozoospermia using ICSI and oocyte activation by calcium ionophore, which yielded conception and birth of a healthy baby after six previous unsuccessful attempts, using ICSI alone.

### Case Presentation

The couple was admitted to TDV 29 Mayıs Hospital, Assisted Reproduction Technologies (ART) Unit with a history of infertility for 17 years. Only one pregnancy had been obtained after five ICSI attempts, one of which resulted in an ectopic tubal pregnancy. During those 17 years, frozen embryos were not obtained because fertilization rate was very low in all ICSI attempts. ICSI attempts are summarized in table 1.

At the time of initial consult, the female partner was 37 years old. She had regular menstrual cycles occurring every 30 days. Her body mass index (BMI) was 31 kg/m<sup>2</sup>. Physical examination was unremarkable except a surgical scar on the abdomen related to a ruptured fallopian tube due to ectopic pregnancy. Her antral follicle count was



**Figure 1.** Photomicrographs of the sample with phase contrast microscopy, in which spermatozoa with a round head (arrow), wide (blue arrow) and broken neck (double arrow) are observed. Also, the picture depicts the spermatozoa with dag defect (yellow arrow)

nine and baseline serum hormone levels were as follows: FSH, 3.3 IU/l; LH, 4.2 IU/l; and estradiol, 33 pg/ml.

The male partner's medical and physical history, which included a urogenital exam was unremarkable. However, total globozoospermia was present in several semen analyses. All of the morphologically assessed spermatozoa had a round head with a wide, long, and irregular neck in phase contrast image (Figure 1). Transmission electron microscopic (TEM) imaging revealed the lack of acrosome, presence of vacuolization in the nucleus, abnormal structure of microtubule, and abnormalities in chromatin condensation with aniline blue staining. Only 82% of the total number of spermatozoa had normal chromatin condensation. Full results of semen analyses are presented in table 2. Serum hormone levels were as follows: FSH, 6.2 IU/l; LH, 3.5 IU/l; total testosterone, 9.1 ng/ml; inhibin-B, 125 ng/ml. He had normal chromosomal constitution of 46 XY, without a microdeletion of the Y chromosome.

ICSI followed by oocyte activation with Ca<sup>++</sup> ionophore was offered to the couple. Following

**Table 1.** All ICSI attempts of the patient

Attempt No	Protocol	N of OR	N of ICSI	AOA with CAI	N of 2 PN	N of ET	N of CP	FR %
1.	Antagonist	16	14	NO	1	1	NO	7.14
2.	Long DR	12	11	NO	1	1	NO	9.09
3.	Long DR	10	8	NO	1	1	NO	12.50
4.	Long DR	9	8	NO	1	1	NO	12.50
5.	Long DR	11	11	YES	3	2	NO	27.27
6.	Long DR	8	8	NO	1	1	NO	12.50
7.	Long DR	14	13	YES	5	2	YES	38.46

Long DR: Long down-regulation; N of OR: Number of oocyte retrieval; N of ICSI: Number of ICSI; AOA with CAI: Assisted oocyte activation with Ca<sup>++</sup> ionophore; N of 2PN: Number of 2 pronucleus; N of ET: Number of embryos transferred; N of CP: Number of cryopreserved embryos; FR: Fertilization rate

**Table 2.** All sperm parameters of the patient

All sperm parameters of the patient			
Volume ( <i>ml</i> )	3	3.1	3.5
Concentration ×10 <sup>6</sup> ( <i>ml</i> )	57.2	51	14
Progressive motility (%)	53.0	57.0	26.0
Non-progressive motility (%)	13.0	14.0	9.0
Normal spermatozoon (%)	0.0	0.0	0.0
Teratozoospermia index	1.04	1.03	1.0

classic long down-regulation priming, which included recombinant FSH and human menopausal gonadotrophins (hMG) injections, the procedure started at a dose of 225 IU/day and 150 IU/day on cycle day 3, respectively. On the 12th day of stimulation, the female had four follicles at 17 mm and 8 at 14-16 mm. She was given 250 µgr/0.5 ml chrogonadotropin alpha and oocytes were obtained 35.5 hr later. Thirteen metaphase two stage oocytes were collected. On the day of oocyte collection, sperm concentration was 11×10<sup>6</sup>/ml with 25% progressive motility. A semen sample was prepared according to the gradient method. In this method, layers were made with 1 ml of gradient solution (90% lower and 50% upper layer) after which 1.5 ml of semen was carefully layered on top of 50% and centrifuged at 1500 g for 20 min. Cell debris, immobile, and abnormal sperm all accumulated at interfaces and a soft pellet was formed at the bottom of the tube. This pellet was aspirated and suspended in 2 ml of culture medium. In the following step, the pellet was centrifuged at 1500 g for 6-7 min. Next the pellet was suspended in 0.3-0.5 ml of culture medium and used for insemination. By using an Olympus IX 71 Inverted Research Microscope (Olympus Corporation, Shibuyaku, Tokyo, Japan), only the spermatozoa having linear, progressive motility, normal structure of the neck, and lacking nuclear vacuoles for ICSI were selected. Following ICSI, oocytes were treated with Ca<sup>++</sup> ionophore 7 µl/ml which was extracted from a prepared solution of 10 µl Ca<sup>++</sup> ionophore (A23187, Sigma-Aldrich, Istanbul, Turkey) and 1 ml G-IVF (Vitrolife, Istanbul, Turkey) solutions with different durations in compliance with our laboratory protocol. Exposure times with Ca<sup>++</sup> ionophore were as follows: 4 oocytes for 7 min, and 5 oocytes for 14 min. In addition, 4 oocytes were not exposed. After exposure to Ca<sup>++</sup> ionophore, the oocytes were washed three times with G-IVF (Vitrolife, Istanbul, Turkey) medium and cultured in the same medium at 36.7°C, 5% oxygen, and 6% CO<sub>2</sub> concentration.

Two oocytes were observed to have 2 PN after being treated with Ca<sup>++</sup> ionophore for 7 min as the three oocytes which were treated with Ca<sup>++</sup> ionophore for 14 min. Moreover, 2PN was not observed in the four oocytes which had not been treated with Ca<sup>++</sup> ionophore. On day 5, two obtained embryos after 14 min of treatment with Ca<sup>++</sup> ionophore were implanted under ultrasound guidance. Three obtained blastocysts after 7 min and 14 min were frozen using vitrification technique. Vitrolife GIII series (Istanbul, Turkey) media were used in all steps. Starting from the day of oocyte collection, intramuscular injections of progesterone in oil at a dose of 100 mg/day were given to support the luteal phase of the cycle.

Two weeks after the oocyte collection, the serum beta hCG level was 101 IU/l. Clinical pregnancy with a heartbeat was confirmed after two additional weeks. The pregnancy concluded with the live birth delivery of a single, healthy male: 3720 gr., 52 cm at delivery.

Written informed consent was obtained from the patient for publication of this case report and any accompanying images.

### Discussion

Globozoospermia is a rare type of teratozoospermia that accounts for 0.1% of all cases of andrologic infertility (2). The condition is also known as round-headed sperm syndrome. The main characteristic defects of this syndrome are lack of acrosome and a round-headed nucleus. Furthermore, several other morphologic defects which accompany the deficiency include deformed tails, abnormal perinuclear cytoskeleton, abnormally arranged mitochondria, vacuoles in nucleus, abnormally condensed nucleus, no post-acrosomal sheath, and disturbed midpiece (5, 12). In line with the findings in other studies in literature, all investigations using microscopy revealed anomalous findings in the patient.

The pathogenesis of globozoospermia is still poorly understood. However, recent studies show that there is a genetic basis with familial distribution of globozoospermia as well as different modes of inheritance that are X-linked, dominantly sex-restricted, or autosomal recessive (13). In animal studies, the knockout of different genes can lead to approximately the same phenotype. Moreover, there might indeed be different genetic pathways of pathogenesis that lead to this morphological sperm disorder (14, 15). However, no genetic data was provided in this case.

Spontaneous fertilization in cases of total globozoospermia has not been reported in the literature (13). The basis for the absence of spontaneous fertilization is that spermatozoa without acrosomes are unable to bind to the zona pellucida and fuse with the oocyte membrane. For this reason, many authors suggested that infertility can be overcome by ICSI. However, since the first pregnancy using the ICSI cycle technique was reported by Lundin et al. (8, 9) in globozoospermic males, low or absent fertilization rates persist. As shown in table 1, our case had low fertilization rate in all ICSI attempts except the last one which was treated with  $\text{Ca}^{++}$  ionophore in our center.

Human oocyte activation occurred when intracellular  $\text{Ca}^{++}$  release triggered. Sperm-specific phospholipase C (PLC zeta) which has been implicated as an oocyte-activating factor was localized in the equatorial region in sperm and  $\text{Ca}^{++}$  oscillation was increased by this enzyme (11). Findings from some studies suggest that fertilization rates are very low due to reduction in the PLC zeta level of globozoospermic spermatozoa (16). In order to solve the low fertilization rate, assisted oocyte activation and morphologically selected sperm injection (IMSI) are used (17, 18). Artificial activation applies mechanical, chemical, or physical stimuli to increase calcium levels in the oocyte cytoplasm (16). Likewise, in our case,  $\text{Ca}^{++}$  was used for chemical oocyte activation (19). In addition, the other studies reported that using  $\text{Ca}^{++}$  ionophore for ICSI procedure increased not only the fertilization rate, but also the embryologic development (20). For example, Kuentz et al. (21) reported a fertilization rate of 72.1% with  $\text{Ca}^{++}$  ionophore, but only 10.6% without  $\text{Ca}^{++}$  ionophore. Additionally, Versieren et al. (22) showed that using assisted activation was increased to develop the blastocyst stage in mouse oocytes. In our case, artificial activation was also used with  $\text{Ca}^{++}$  ionophore and it demonstrated high fertilization rates and good embryonic development despite previous unsuccessful attempts.

In the fertilization process, sperm chromatin condensation has a crucial influence and its disturbances may negatively affect fertility. This process occurs by increased formation of disulphide bonds and involves replacement of histones by protamines (23). Usually, abnormal chromatin condensation can be indicative of a maturation defect (24). Chromatin immaturity is also characterized by low phosphorus, high zinc, and variable lysine levels (24). The morphological aspects of

chromatin condensation in globozoospermia are measured by the flow cytometric sperm chromatin structure assay (SCSA), which is based on the sensitivity of sperm nuclear DNA to acid-induced denaturation (25). Furthermore, chromatin maturation can be measured by fluorescence-activated cell sorter (FACS) analysis of propidium iodide-stained semen samples by propidium iodide staining (26). Most of the studies in the literature show that males with globozoospermia have abnormal sperm chromatin condensation more often than fertile men (27). However, Larson et al. (25) found no rise in DNA fragmentation in globozoospermic cells when contrasted with the sperm of fertile men. Similar to the latter report, in this study, it was found that assessment of chromatin condensation by aniline blue staining was normal in 82% of spermatozoa.

### Conclusion

Globozoospermia is the severe and rare form of teratozoospermia that usually causes low fertilization and pregnancy rates. The majority of us use assisted oocyte activation with  $\text{Ca}^{++}$  ionophore to solve this issue in ICSI cycles. This case was special because our technique led to successful conception and birth of a healthy baby to a patient with type 1 globozoospermia after Intracytoplasmic Sperm Injection (ICSI) with oocyte activation by calcium ionophore, after six previous unsuccessful attempts using ICSI alone.

### Conflict of Interest

The authors declare that they have no conflict of interest and have received neither material nor financial support to undertake this research. All authors contributed equally to this study.

### References

1. Thonneau P, Marchand S, Tallec A, Ferial ML, Ducot B, Lansac J, et al. Incidence and main causes of infertility in a resident population (1,850,000) of three French regions (1988-1989). *Hum Reprod.* 1991;6(6):811-6.
2. World Health Organization. WHO manual for the standardised investigation and diagnosis of the infertile male. Cambridge: Cambridge University Press; 2000. 5 p.
3. Anton-Lamprecht I, Kotzur B, Schopf E. Round-headed human spermatozoa. *Fertil Steril.* 1976;27(6):685-93.
4. Xu M, Xiao J, Chen J, Li J, Yin L, Zhu H, et al. Identification and characterization of a novel human

- testis-specific Golgi protein, NYD-SP12. *Mol Hum Reprod.* 2003;9(1):9-17.
5. Koscinski I, Elinati E, Fossard C, Redin C, Muller J, Velez de la Calle J, et al. DPY19L2 deletion as a major cause of globozoospermia. *Am J Hum Genet.* 2011;88(3):344-50.
  6. Liu G, Shi QW, Lu GX. A newly discovered mutation in PICK1 in a human with globozoospermia. *Asian J Androl.* 2010;12(4):556-60.
  7. Dam AH, Koscinski I, Kremer JA, Moutou C, Jaeger AS, Oudakker AR, et al. Homozygous mutation in SPATA16 is associated with male infertility in human globozoospermia. *Am J Hum Genet.* 2007;81(4):813-20.
  8. Lundin K, Sjogren A, Nilsson L, Hamberger L. Fertilization and pregnancy after intracytoplasmic microinjection of acrosomeless spermatozoa. *Fertil Steril.* 1994;62(6):1266-7.
  9. Kilani Z, Ismail R, Ghunaim S, Mohamed H, Hughes D, Brewis I, et al. Evaluation and treatment of familial globozoospermia in five brothers. *Fertil Steril.* 2004;82(5):1436-9.
  10. Egashira A, Murakami M, Haigo K, Horiuchi T, Kuramoto T. A successful pregnancy and live birth after intracytoplasmic sperm injection with globozoospermic sperm and electrical oocyte activation. *Fertil Steril.* 2009;92(6):2037.
  11. Grasa P, Coward K, Young C, Parrington J. The pattern of localization of the putative oocyte activation factor, phospholipase C zeta, in uncapacitated, capacitated, and ionophore-treated human spermatozoa. *Hum Reprod.* 2008;23(11):2513-22.
  12. Harbuz R, Zouari R, Pierre V, Ben Khelifa M, Kharouf M, Coutton C, et al. A recurrent deletion of DPY19L2 causes infertility in man by blocking sperm head elongation and acrosome formation. *Am J Hum Genet.* 2011;88(3):351-61.
  13. Dam AH, Feenstra I, Westphal JR, Ramos L, van Golde RJ, Kremer JA. Globozoospermia revisited. *Hum Reprod Update.* 2007;13(1):63-75.
  14. Yao R, Ito C, Natsume Y, Sugitani Y, Yamanaka H, Kuretake S, et al. Lack of acrosome formation in mice lacking a Golgi protein, GOPC. *Proc Natl Acad Sci U S A.* 2002;99(17):11211-6.
  15. Kierszenbaum AL, Tres LL, Rivkin E, Kang-Decker N, van Deursen JM. The acroplaxome is the docking site of Golgi-derived myosin Va/Rab27a/b-containing proacrosomal vesicles in wild-type and Hrb mutant mouse spermatids. *Biol Reprod.* 2004;70(5):1400-10.
  16. Kashir J, Heindryckx B, Jones C, De Sutter P, Parrington J, Coward K. Oocyte activation, phospholipase C zeta and human infertility. *Hum Reprod Update.* 2010;16(6):690-703.
  17. Sermondade N, Hafhouf E, Dupont C, Bechoua S, Palacios C, Eustache F, et al. Successful childbirth after intracytoplasmic morphologically selected sperm injection without assisted oocyte activation in a patient with globozoospermia. *Hum Reprod.* 2011;26(11):2944-9.
  18. Dirican EK, Isik A, Vicdan K, Sozen E, Suludere Z. Clinical pregnancies and livebirths achieved by intracytoplasmic injection of round headed acrosomeless spermatozoa with and without oocyte activation in familial globozoospermia: case report. *Asian J Androl.* 2008;10(2):332-6.
  19. Heindryckx B, Van der Elst J, De Sutter P, Dhont M. Treatment option for sperm- or oocyte-related fertilization failure: assisted oocyte activation following diagnostic heterologous ICSI. *Hum Reprod.* 2005;20(8):2237-41.
  20. Vanden Meerschaut F, Leybaert L, Nikiforaki D, Qian C, Heindryckx B, De Sutter P. Diagnostic and prognostic value of calcium oscillatory pattern analysis for patients with ICSI fertilization failure. *Hum Reprod.* 2013;28(1):87-98.
  21. Kuentz P, Vanden Meerschaut F, Elinati E, Nasr-Esfahani MH, Gurgan T, Iqbal N, et al. Assisted oocyte activation overcomes fertilization failure in globozoospermic patients regardless of the DPY19L2 status. *Hum Reprod.* 2013;28(4):1054-61.
  22. Versieren K, Heindryckx B, Lierman S, Gerris J, De Sutter P. Developmental competence of parthenogenetic mouse and human embryos after chemical or electrical activation. *Reprod Biomed Online.* 2010;21(6):769-75.
  23. Perrin A, Nguyen MH, Bujan L, Vialard F, Amice V, Gueganic N, et al. DNA fragmentation is higher in spermatozoa with chromosomally unbalanced content in men with a structural chromosomal rearrangement. *Andrology.* 2013;1(4):632-8.
  24. Baccetti B, Renieri T, Rosati F, Selmi MG, Casanova S. Further observations on the morphogenesis of the round headed human spermatozoa. *Andrologia.* 1977;9(3):255-64.
  25. Larson KL, Brannian JD, Singh NP, Burbach JA, Jost LK, Hansen KP, et al. Chromatin structure in globozoospermia: a case report. *J Androl.* 2001;22(3):424-31.
  26. Vicari E, Perdichizzi A, De Palma A, Burrello N, D'Agata R, Calogero AE. Globozoospermia is associated with chromatin structure abnormalities: case report. *Hum Reprod.* 2002;17(8):2128-33.
  27. Perrin A, Louanjli N, Ziane Y, Louanjli T, Le Roy C, Gueganic N, et al. Study of aneuploidy and DNA fragmentation in gametes of patients with severe teratozoospermia. *Reprod Biomed Online.* 2011;22(2):148-54.