

SDRIFE-Like Rash With COVID - 19

Symmetrical drug-related intertriginous and flexural exanthema (SDRIFE), previously termed drug-related Baboon syndrome, is described as type IV hypersensitivity to a systemic drug [1]. SDRIFE has been commonly associated with beta-lactams, antihypertensives, radiocontrast media, chemotherapeutic agents and biologics, though its occurrence has also been described in the absence of previous drug exposure [2,3]. There are reports of SDRIFE-like rashes associated with infections including parvovirus infections and of late, in coronavirus disease 19 (COVID-19) patients [1,4,5].

A 9-year-old girl presented with a history of fever and a peculiar SDRIFE-like rash with reactive severe acute respiratory syndrome (SARS-CoV-2) coronavirus 2 antibody. The rash started as an erythematous maculopapular eruption on the upper arm which slowly progressed. A similar erythematous rash involving the flexural aspect of the knee and elbow joints was noted on the second day (**Fig. 1 a and 1 b**). On the third day, the rash progressed further to form a large plaque involving the upper chest and posterior trunk, with a clear line of demarcation from the normal skin. The child also had a low-grade fever and sore throat. By the 7th day of onset of the rash, erythema of skin resolved with desquamation followed by normalization of the involved areas, with complete resolution by the next day. Her blood counts, liver function tests, renal function tests and urine examination were within normal limits. Her SARS-CoV-2 rapid antigen test and RT-PCR were reported negative; however, SARS-CoV-2 IgG antibody was reactive. On reviewing the history, the child as well as four other family members had history of fever with upper respiratory tract infection two months back. In view of fever with rash in a post-Covid-19 state, a possibility of multisystem inflammatory syndrome in children (MIS-C) was

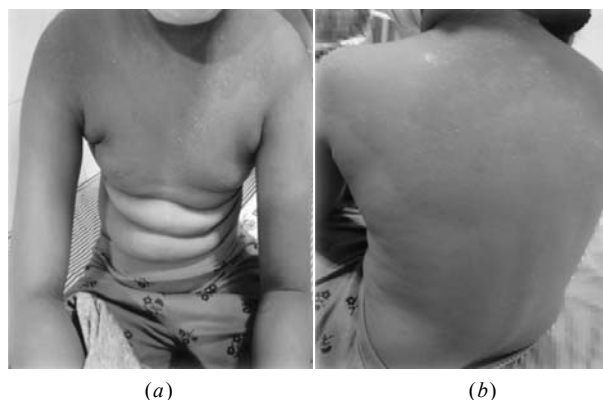


Fig. 1 (a) Erythematous rash with clear demarcation from normal skin involving the flexures on day-2; (b) Rash spreads to form plaques on day-3.

considered. However, the clinical diagnostic criteria were not satisfied, and the inflammatory markers were within the normal range, and MIS-C was ruled out. A diagnosis of SDRIFE was made considering the typical morphology and distribution of the rash, as well as the rapid and complete resolution of the lesions. Treatment given were antibiotics, antihistamines and calamine lotion.

SDRIFE has been defined by inclusion of the following criteria: (i) exposure of a systemically administered drug at the time of first or repeated doses (contact allergens excluded); (ii) sharply demarcated erythema of the gluteal/perianal area and/V shaped erythema of the inguinal/perigenital area; (iii) involvement of at least one other intertriginous/flexural fold; (iv) symmetry of affected areas; and (v) absence of systemic symptoms and signs. The clinical scenario which we encountered was consistent with the above mentioned clinical features [2,3].

SDRIFE usually arises within a few hours to days following administration of the so-called offending agents, though it is also known to be triggered by infections [1,4,5]. Most cases spontaneously resolve via desquamation within 1 to 2 weeks which was the case with our patient also. The typical morphology of the rash helps to make the diagnosis. Interestingly, there was no history of drug intake prior to onset of rash in our patient. The patient had a positive SARS-CoV-2 IgG antibody and a history suggestive of Covid infection in the family two months back. Though SDRIFE-like rash has been reported in association with SARS-CoV-2 infection earlier also, the presence of SARS-CoV-2 IgG antibody in this patient could be a mere coincidence. At this stage, we need more data to assess if there is a true correlation between COVID-19 and SDRIFE-like rash.

Published online: Dec. 10, 2021, *PII*: S097475591600378

**RATHIRA,¹ LABEEBA HAMSA,² NAVEEN THOMAS,^{3*}
REKHA ZACHARIAS¹**

*Departments of¹ Pediatrics, ² Family Medicine and ³ Dermatology,
Medical Trust Hospital, Kochi, Kerala.
naveenthomas04@yahoo.com

REFERENCES

1. Bevilacqua M, Ribolli GB, Luzzatto L, et al. SDRIFE-like rash in COVID-19 patient: drug reaction or another cutaneous manifestation of SARS-CoV-2? *Int J Dermatol.* 2021;60:884-85.
2. Tan SC, Tan JW. Symmetrical drug-related intertriginous and flexural exanthema. *Curr Opin Allergy Clin Immunol.* 2011;11:313-8.
3. Feldmeyer L, Heidemeyer K, Yawalkar N. Acute generalized exanthematous pustulosis: pathogenesis, genetic background, clinical variants and therapy. *Int J Mol Sci.* 2016;17:1214.
4. Dubois A, Thellier S, Wierzbicka-Hainaut E, et al. Exanthème a type de "syndrome babouin" au cours d'une primo-infection par le parvovirus B19: deux cas. *Ann Dermatol Venereol.* 2010; 137:709-12.
5. Chicharro P, Rodríguez-Jiménez P, Muñoz-Aceituno E, et al. SDRIFE-like rash associated with COVID-19, clinicopathological correlation. *Australas J Dermatol.* 2021;62:88-89.