

Case report

Ocular manifestations in Edward's syndrome, a case report and literature review

Arash Mirmohammadsadeghi, Mohammad Reza Akbari, Afsaneh Malekpoor*

Eye Research Center, Farabi Eye Hospital, Tehran University of Medical Sciences, Tehran, Iran

Received 8 December 2016; revised 3 June 2017; accepted 13 June 2017

Available online 15 July 2017

Abstract

Purpose: To report a case with Edward's syndrome and ocular manifestations.

Methods: A three-year-old female visited our clinic. The diagnosis of Edward's Syndrome was made prior to the ophthalmic visit based on a karyotype study report. Complete ophthalmic evaluations were done for the patient.

Results: On the initial ophthalmic examination, bilateral ptosis, epicanthal folds, and 40 prism diopters alternate esotropia (ET) were seen. In the fundus examination, decreased red reflexes along with retinal folds, pigmentary retinopathy (patches of hyperpigmentation in the fovea and retinal periphery), and optic disc atrophy in both eyes were seen.

Conclusion: Our case adds some evidence to the literature that ET may be one of the classic manifestations and anomalies in trisomy 18.

Copyright © 2017, Iranian Society of Ophthalmology. Production and hosting by Elsevier B.V. This is an open access article under the CC BY-NC-ND license (<http://creativecommons.org/licenses/by-nc-nd/4.0/>).

Keywords: Edward's syndrome; Trisomy 18; Esotropia

Introduction

Trisomy 18, also known as Edward's syndrome, is defined as a hereditary disorder, presenting with an extra chromosome 18 in the karyotype study.^{1–4} This syndrome is the second most common autosomal disorder among live-born children after trisomy 21. It is estimated that one in every 3000 to 10,000 live births is diagnosed with Edward's syndrome.^{3–5} Of these, less than 10% survive through the first year. As most male infants with the disease die during pregnancy, it is believed that most live-born children with trisomy 18 are females; thus, there is a 3:1 ratio in the prevalence of females to males.^{4–6} This syndrome affects multiple organs, leading to neurological, cardiac, pulmonary, gastrointestinal, musculo-skeletal manifestations.^{6,7} In the present article, we reported a

three-year-old girl with ocular presentations of Edward's syndrome as esotropia (ET), optic atrophy, and pigmentary retinopathy.

Case report

A three-year-old female visited our clinic for ophthalmic evaluations. She was born of a normal pregnancy with the birth weight of 2 kg. The diagnosis of Edwards Syndrome was made prior to the ophthalmic visit based on a karyotype study report (Fig. 1). Low-set ears, micrognathia, prominent occiput, and dolichocephaly were evident on observation (Fig. 2). General physical examinations were also consistent with the diagnosis including developmental delay and short stature.

On the initial ophthalmic examination, bilateral ptosis, epicanthal folds, and 40 prism diopters alternate ET, measured with Krimsky method were seen (Fig. 2). Visual acuity was central-steady-maintain (CSM) in both eyes. There was some limitation of abduction in versions but ocular ductions were full in both eyes. Cycloplegic refraction was $+1.5-0.75 \times 15^\circ$

Authors obtained consent from the parents for publishing the photo.

* Corresponding author. Farabi Eye Hospital, Ghazvin Square, Iran.

E-mail address: afsaneh.malekpoor@yahoo.com (A. Malekpoor).

Peer review under responsibility of the Iranian Society of Ophthalmology.

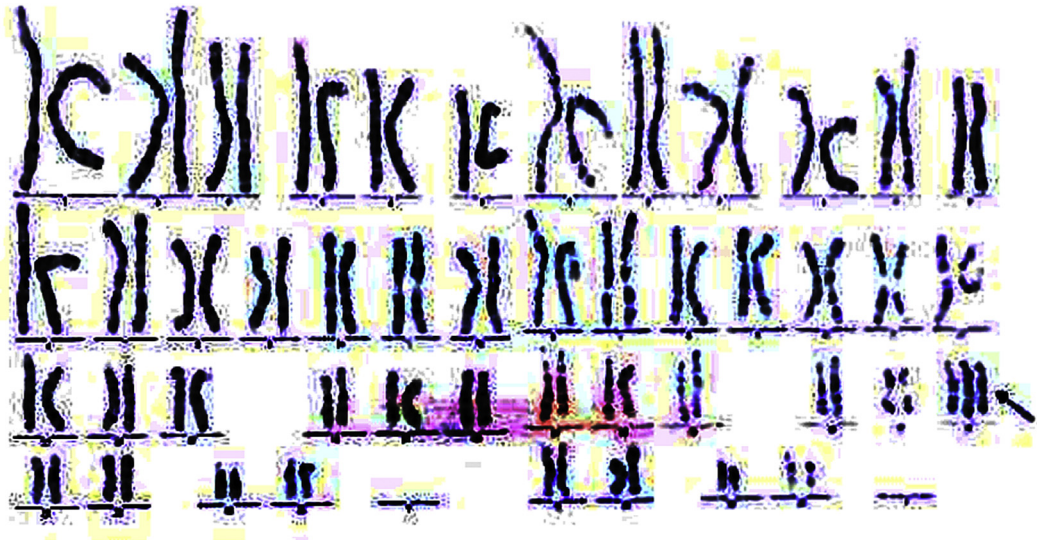

Fig. 1. Chromosomal analysis of the patient showed 47 chromosomes with an extra chromosome 18 (arrow).




Fig. 2. Three-year-old girl with esotropia (ET) and Edward's syndrome.

in the right eye and $+1.25-0.5 \times 150^\circ$ in the left eye. In the fundus examination, decreased red reflexes along with retinal folds, pigmentary retinopathy (patches of hyperpigmentation in the fovea and retinal periphery), and optic disc atrophy in both eyes were seen.

In order to evaluate the differential diagnosis such as infectious, metabolic, and endocrine diseases, TORCH study (anti-toxoplasma, anti-rubella, anti-cytomegalovirus, and anti-herpes simplex virus IgG and IgM antibodies), blood amino acids, serum lactate, and thyroid function tests had been tested which revealed normal results. Brain MRI was normal. The parents declined strabismus surgery.

Discussion

Edward's syndrome, as a genetic disorder, results from full, mosaic, or partial trisomy 18q. Full trisomy 18 is the most common form occurring in about 94% of cases.^{5–7} Risk factors for the disease include a positive family history in close relatives and rising maternal age.^{7–10} Most cases in the developed countries are diagnosed antenatally based on

screening by maternal age, maternal serum marker screening or detection of sonographic abnormalities during second or third trimester.⁹ Antenatal diagnosis of trisomy 18 leads to termination of pregnancy in 86% of cases.⁹ The clinical presentations of Edward's syndrome are characterized by antenatal growth deficiency, specific craniofacial features, major system malformations and marked psychomotor and cognitive developmental delay.^{8,9,11} Features that may be noted right after the birth include: low birth weight, craniofacial abnormalities, low-set and malformed ears, micrognathia, prominent occiput and dolichocephaly, small facial features, skeletal abnormalities, congenital heart defects, gastrointestinal abnormalities, urogenital abnormalities, neurological problems, and pulmonary hypoplasia.^{6,8,11} The most common anomalies of the eyes, on the other hand, usually involve the ocular adnexae, especially eyelids and orbits (narrow palpebral fissures,¹⁰ ptosis,¹⁰ epicanthal folds,¹⁰ hypoplastic supraorbital ridges,¹² punctal agenesis,¹² discontinuous eyebrows,¹³ long eyelashes with distichiasis,¹³ hyper- or hypotelorism,¹⁰ and blepharophimosis¹⁰). The other reported ocular manifestations are: microphthalmia,¹⁴ microcornea,¹⁴ corneal opacity,¹⁰

cataract,¹⁰ glaucoma,¹⁰ retinal folds,¹⁰ absent retinal pigmentation,¹⁰ optic disc coloboma,¹⁴ coloboma of iris, persistent hyaloid artery,¹⁴ optic nerve pit,¹² nystagmus,¹⁰ anisocoria¹⁰ and blue sclera.¹³

Our case presented with some of the above manifestations such as ptosis, epicanthal folds, and retinal folds. This case is one of the rare reports of esotropia, retinal hyperpigmentations, and optic atrophy in Edward's syndrome. Whether these findings are the result of trisomy 18 or merely an association is unclear, and further reports are required. A 13-year-old case of trisomy 18 with convergent strabismus (esotropia) was also reported by Mehta et al.¹³ Anomalous medial rectus insertion was reported in one case in this syndrome.¹⁰ Our case adds some evidence to the literature that ET may be one of the classic manifestations and anomalies in trisomy 18.

References

1. Cereda A, Carey JC. The trisomy 18 syndrome. *Orphanet J Rare Dis*. 2012 Oct 23;7:81.
2. Shaw J. Trisomy 18: a case study. *Neonatal Netw*. 2008 Jan-Feb;27(1):33–41.
3. Lin HY, Lin SP, Chen YJ, et al. Clinical characteristics and survival of trisomy 18 in a medical center in Taipei, 1988–2004. *Am J Med Genet A*. 2006 May 1;140(9):945–951.
4. Destree A, Fourneau C, Dugauquier C, Rombout S, Sartenaer D, Gillerot Y. Prenatal diagnosis of trisomy 6 mosaicism. *Prenat Diagn*. 2005 May;25(5):354–357.
5. Qian Y, Lewis RA, Traboulsi EI. Pigmentary retinopathy is systemic inherited disease. In: *Genetic Disease of the Eye*. second ed. Oxford University Press; Jan 2012.
6. Nagamuthu EA, Neelaveni N. Edward syndrome (Trisomy 18): a case report. *Ann Biol Res*. 2014;5(3):67–72.
7. Helveston EM. Esotropia. *Trans Am Ophthalmol Soc*. 1988;86:441–460.
8. Esotropia. Retrieved 01.2016. American Association of Pediatrics Ophthalmology and Strabismus on the world wide web: <http://www.aapos.org/terms/conditions/48>.
9. Ginsberg J, Perrin EV, Sueoka WT. Ocular manifestations of trisomy 18. *Am J Ophthalmol*. 1968;66(1):59–67.
10. Calderone JP, Chess J, Borodic G, Albert DM. Intraocular pathology of trisomy 18 (Edwards's syndrome): report of a case and review of the literature. *Br J Ophthalmol*. 1983 Mar;67(3):162–169.
11. Lim FF, Ng YY, Hu JM, Chen SJ, Su PH, Chen JY. Ocular findings in a case of trisomy 18 with variant of Dandy-Walker syndrome. *Pediatr Neonatol*. 2010 Oct;51(5):292–295.
12. Villegas VM, Chang JS, Hess DJ, Berrocal AM. Congenital optic nerve pit in trisomy 18. *J Pediatr Ophthalmol Strabismus*. 2013 Jun 4;50. Online: e24–6.
13. Mehta L, Shannon RS, Duckett DP, Young ID. Trisomy 18 in a 13 year old girl. *J Med Genet*. 1986 Jun;23(3):256–257.
14. Acar DE, Acar U, Ozdemir O, Ozen ZT, Cakar ES. Microphthalmia in a case of Edward syndrome. *Semin Ophthalmol*. 2014 Mar;29(2):114–117.