



Contents lists available at ScienceDirect

## International Journal of Surgery Case Reports

journal homepage: [www.casereports.com](http://www.casereports.com)

## An unusual stress fracture: Bilateral posterior longitudinal stress fracture of tibia

Melih Malkoc<sup>a,\*</sup>, Ozgur Korkmaz<sup>a</sup>, Tugrul Ormeci<sup>b</sup>, Ismail Oltulu<sup>a</sup>, Mehmet Isyar<sup>a</sup>, Mahir Mahirogullari<sup>a</sup><sup>a</sup> Department of Orthopedics and Traumatology, Istanbul Medipol University, School of Medicine, Turkey<sup>b</sup> Department of Radiology, Istanbul Medipol University, School of Medicine, Turkey

## ARTICLE INFO

## Article history:

Received 24 April 2014

Received in revised form 2 June 2014

Accepted 2 June 2014

Available online 11 June 2014

## Keywords:

Tibial stress fracture

Longitudinal tibial fracture

## ABSTRACT

**INTRODUCTION:** Stress fractures (SF) occur when healthy bone is subjected to cyclic loading, which the normal carrying range capacity is exceeded. Usually, stress fractures occur at the metatarsal bones, calcaneus, proximal or distal tibia and tends to be unilateral.

**PRESENTATION OF CASE:** This article presents a 58-year-old male patient with bilateral posterior longitudinal tibial stress fractures. A 58 years old male suffering for persistent left calf pain and decreased walking distance for last one month and after imaging studies posterior longitudinal tibial stress fracture was detected on his left tibia. After six months the patient was admitted to our clinic with the same type of complaints in his right leg. All imaging modalities and blood counts were performed and as a result longitudinal posterior tibial stress fractures were detected on his right tibia.

**DISCUSSION:** Treatment of tibial stress fracture includes rest and modified activity, followed by a graded return to activity commensurate with bony healing. We have applied the same treatment protocol and our results were acceptable but our follow up time short for this reason our study is restricted for separate stress fractures of the posterior tibia.

**CONCLUSION:** Although the main localization of tibial stress fractures were unilateral, anterior and transverse pattern, rarely, like in our case, the unusual bilateral posterior localization and longitudinal pattern can be seen.

© 2014 The Authors. Published by Elsevier Ltd. on behalf of Surgical Associates Ltd. This is an open access article under the CC BY-NC-ND license (<http://creativecommons.org/licenses/by-nc-nd/3.0/>).

## 1. Introduction

Stress fractures (SF) occur when healthy bone is subjected to cyclic loading, which the normal carrying range capacity is exceeded.<sup>1,2</sup> SF mostly seen athletes or military recruits because of intensive physical exercise.<sup>2–4</sup> Usually, stress fractures occur at the metatarsal bones, calcaneus, proximal or distal tibia and tends to be unilateral.<sup>1,2</sup> In this study, we aimed to report a 58-year-old male patient with bilateral posterior longitudinal tibial stress fractures.

## 2. Case presentation

A 58 years old male suffering for persistent left calf pain and decreased walking distance for last one month. He was complaining the progression of pain through on his left leg. In his medical history there was no changes at the daily walking and exercise

habits for last one year. Localization of the progressive pain is mostly posterior of the whole leg and calf. The pain he suffer was existing both with motion and rest. He was checked and had a therapy for chronic osteomyelitis for three months and no recovery has been acquired. The standard last infection titles have been studied such as sedimentation rates, C-reactive protein, ASO, rheumatoid factor, white blood cell value, red blood cell value. All the values of the tests were normal. X-ray (Fig. 1) and magnetic resonance imaging (MRI) (Figs. 4 and 5) have been obtained and three-phased bone scintigraphy was studied (Fig. 6). Especially with MRI and bone scintigraphy posterior longitudinal tibial stress fracture was detected on his left tibia. The patient was instructed to restrict activity to nonweight-bearing exercise for four to six weeks, followed by a period of gradual increase in weight-bearing activity and anti-inflammatory treatment applied. After six months the patient was admitted to our clinic with the same type of complaints in his right leg. All imaging modalities and blood counts were performed and as a result longitudinal posterior tibial stress fractures were detected on his right tibia (Figs. 2, 3 and 7) The patient was instructed to restrict activity to nonweight-bearing exercise for four to six weeks, followed by a period of gradual increase in weight-bearing activity and anti-inflammatory treatment applied

\* Corresponding author at: Istanbul Medipol University, School of Medicine, Department of Orthopedic and Traumatology, Tem Avrupa Otoyolu Goztepe Cikisi, No:1 Bagcilar, 34214 Istanbul, Turkey. Tel.: +90 212 4607777; fax: +90 212 4607070. E-mail address: [memalkoc@yahoo.com](mailto:memalkoc@yahoo.com) (M. Malkoc).

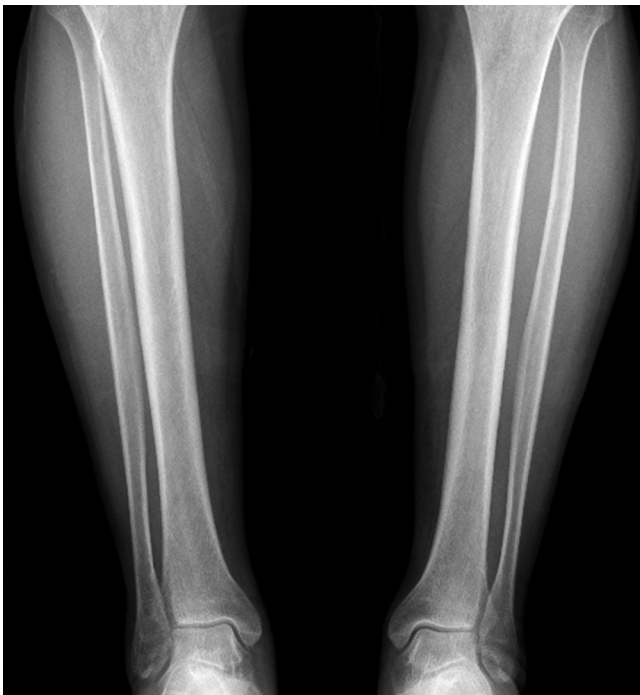

Fig. 1. Bilateral antero-posterior X-ray graphy of tibias.

again. At the end of six weeks, patient had painless and free movement of the both lower extremity. 14 months of follow-up period, patient gained the pain free weight-bearing and full of leg motion.

3. Discussion

Sports injuries have significantly increased in frequency in the past few years, especially among individuals whose level of physical fitness is ill suited to the intensity or the very nature of the activity undertaken. Although data on the prevalence of sports injuries seem to be difficult to collect, it is estimated that approximately 6% of those who engage in sports require medical care for their injuries.<sup>5,6</sup> The most common locations for stress fractures are in

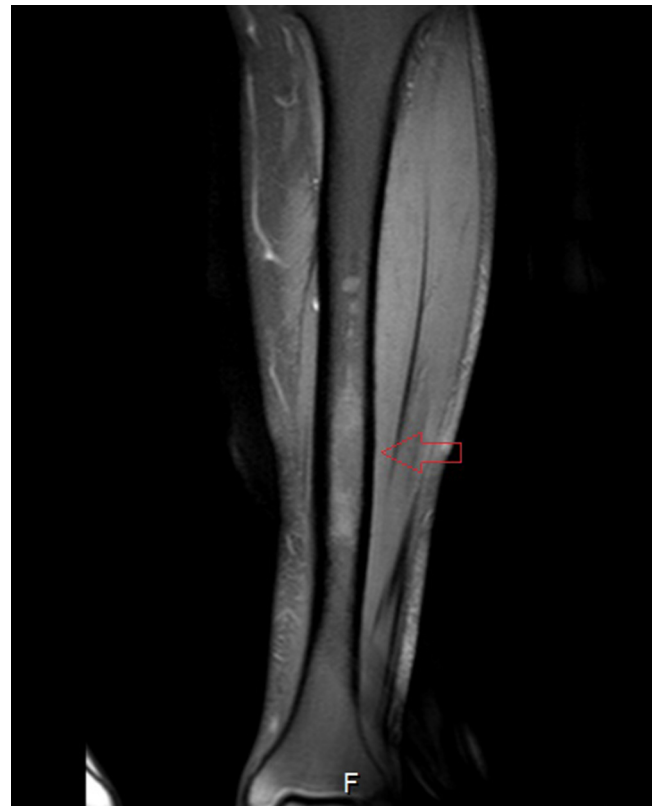

Fig. 3. Coronal MRI section of right tibia.

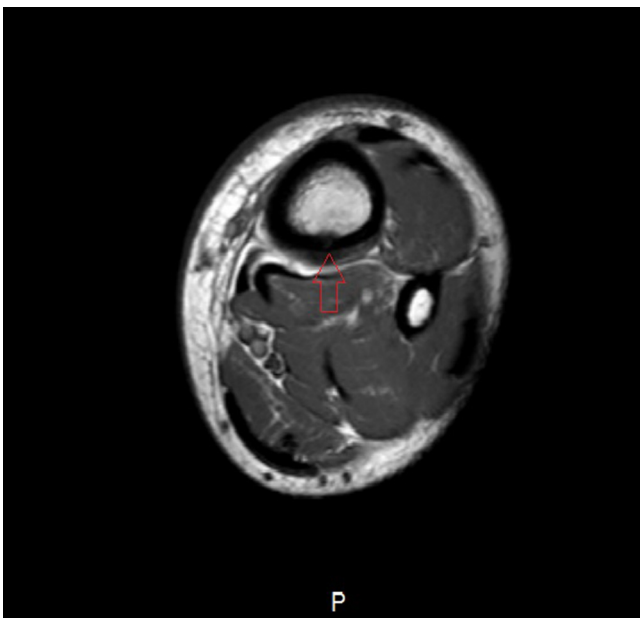


Fig. 2. Transverse MRI section of right tibia.

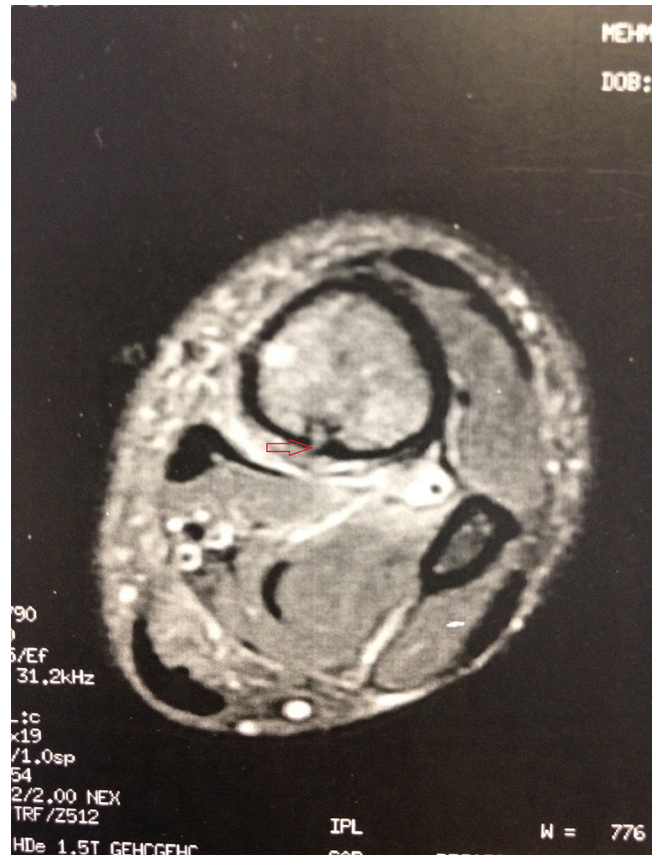


Fig. 4. Transverse MRI section of left tibia.

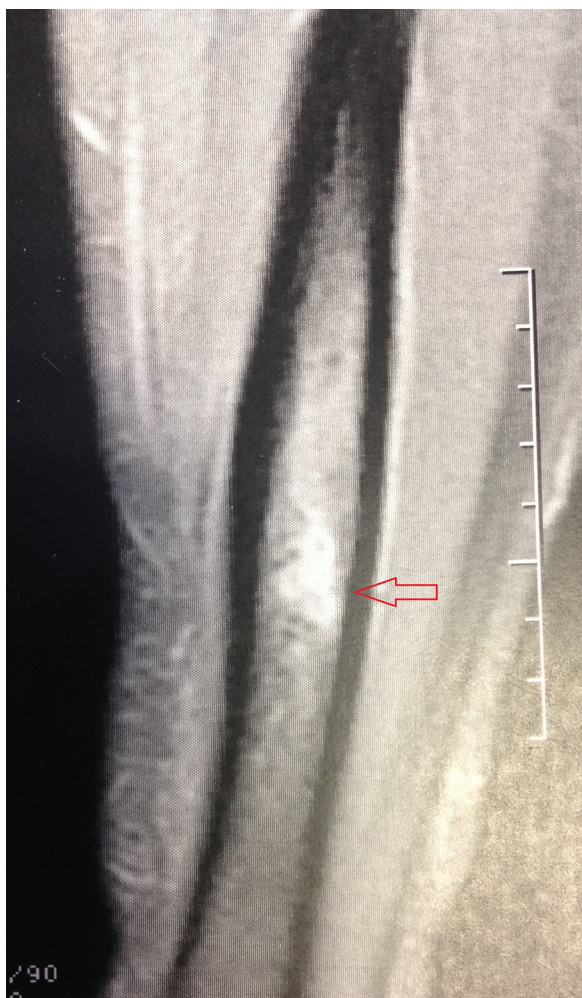

Fig. 5. Coronal MRI section of left tibia.

the tibia (23.6%), tarsal navicular (17.6%), metatarsal (16.2%), fibula (15.5%), femur (6.6%), pelvis (1.6%), and spine (0.6%).<sup>7,8</sup> A bone scan is a sensitive method for early diagnosis of a fatigue fracture. The radioactive tracer is incorporated into the cells responsible for bone remodelling within 24 h following the fracture. However, this technique is not sufficiently specific because bone turnover can be increased in a wide variety of others conditions including tumours, infections or inflammations.<sup>8–10</sup> At 3-D CT-scan, the bone repair reaction appears as bony sclerosis surrounding the line of fracture. In some studies, this technique is even more sensitive and specific than MRI.<sup>11,12</sup> Due to its multiplanar capabilities and high tissue contrast, MRI is the imaging modality of choice for diagnosing an SF. MRI is sensitive and specific, revealing intramedullary oedema, the periosteal reaction and the fracture line.

Khy et al. reported a 35 years old patient presenting with pain in the medial aspect of both knees. Ultrasonography (USG) appearance and with clinical findings together, suggested a diagnosis of simultaneous bilateral fatigue fracture. An MRI confirmed the diagnosis and the patient's symptoms resolved with rest. They reported USG may be a useful imaging tool in the diagnosis of stress fracture.<sup>13</sup> In our case we did not performed USG to our patient. Kilcoyne et al. were randomized the patients with tibial stress fractures to pulsed ultrasound or placebo treatment. The results of placebo versus pulsed ultrasound were no different with respect to healing time and return to duty.<sup>14</sup> In our case, restriction of weight-bearing and anti-inflammatory medication were limited the pain and increased the range of motion. Liimatainen et al. treated surgically 49 anterior mid-tibial stress fractures in 45 patients during the years 1985–2005. All the patients were athletes, mainly runners. The mean age of the patients was 26 years. 34 of the fractures occurred in men and 15 in women. The first method of treatment, anteromedial and lateral drilling, was used in 20 operations and the second method, laminofixation, in 29 operations. Surgical treatment with laminofixation proved to be superior to tibial fracture site drilling.<sup>15</sup> We treated our case without surgery and all the tibial stress fractures are mid tibial in Liimatainen et al. study but in our case the tibial stress fractures are bilaterally and in the posterior

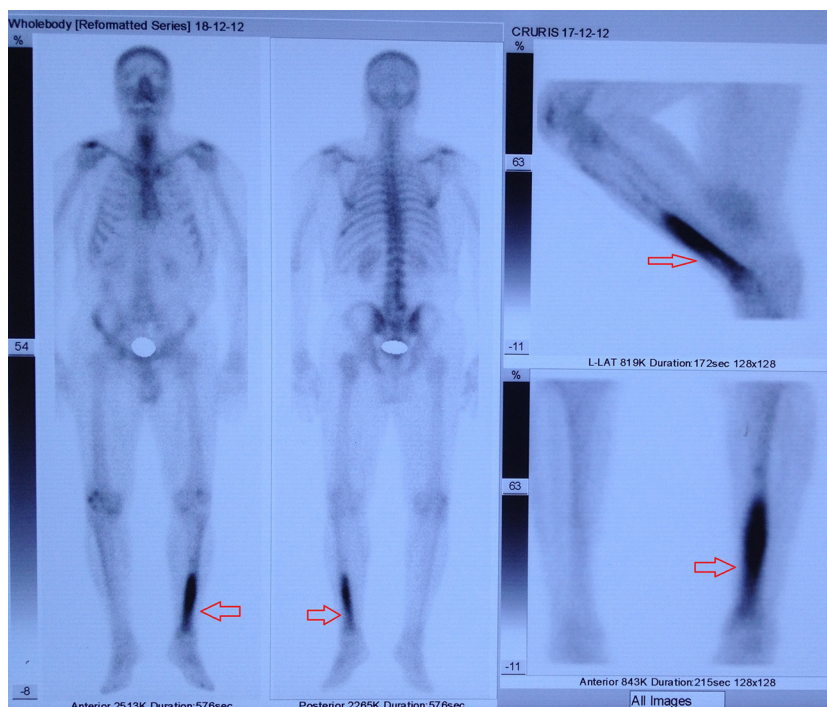


Fig. 6. Bone scan of left tibia.

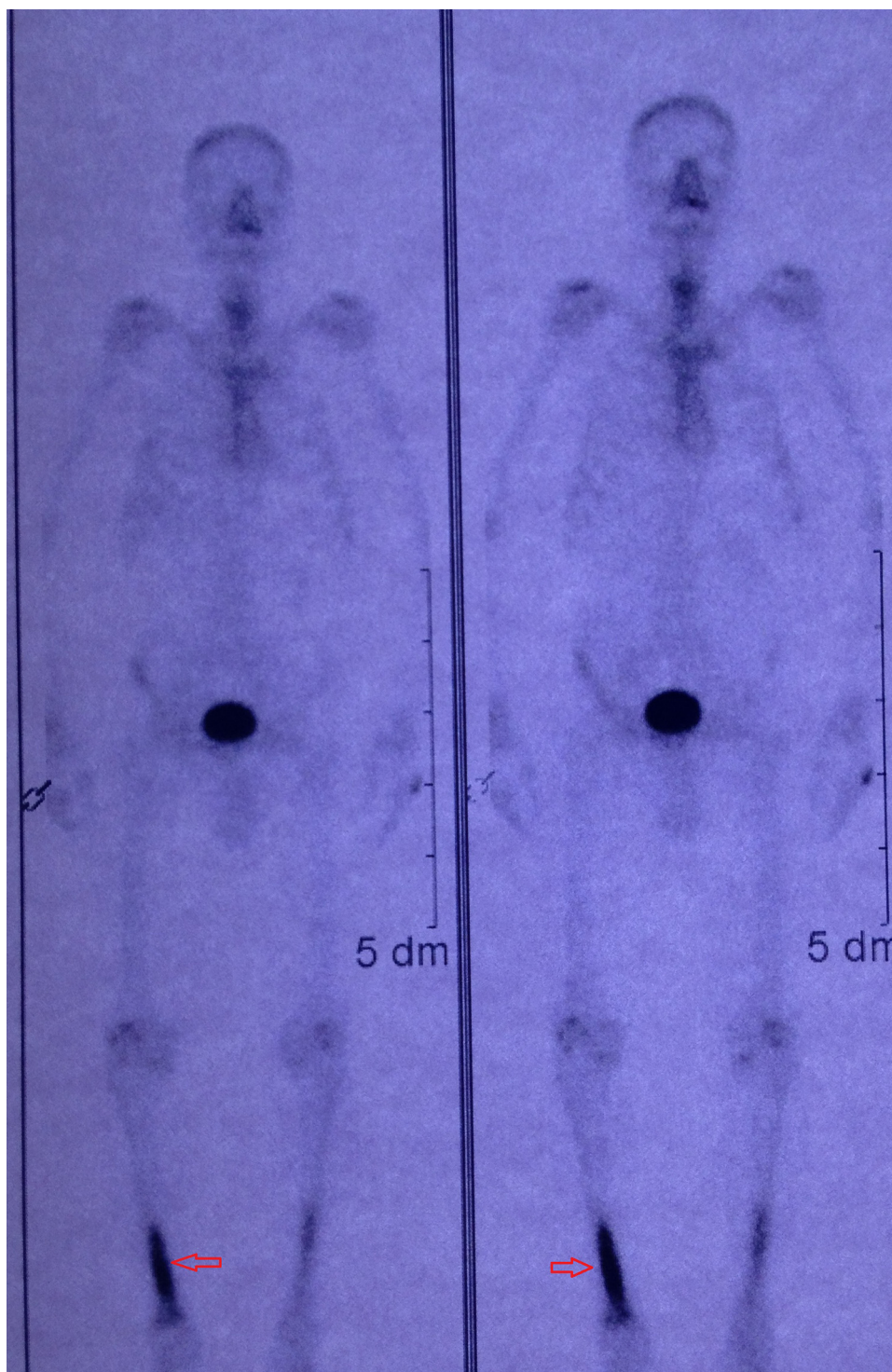


Fig. 7. Bone scan of right tibia.

longitudinal formation. According to van der Velde's study three patients suffered from exercise-related lower leg pain, clinical features, and risk factors specific for posterior tibial stress fracture. Diagnosis was confirmed for all three individuals by radiographic imaging. Treatment included rest and modified activity, followed by a graded return to activity commensurate with bony healing. This approach was successful for two of the individuals diagnosed with posterior tibial stress fracture. In the third individual treatment recommendations were not adhered to, resulting in three

separate stress fractures of the posterior tibia over 27 months.<sup>16</sup> We have applied the same treatment protocol and our results were acceptable but our follow up time short for this reason our study is restricted for separate stress fractures of the posterior tibia.

#### 4. Conclusion

Although the main localization of tibial stress fractures was unilateral, anterior and transverse pattern, rarely, like in our case, the

unusual bilateral posterior localization and longitudinal pattern can be seen. The majority of tibial stress fractures are effectively managed with an appropriate balance of relative rest and therapy without any surgery.

#### Conflict of interest

None.

#### Funding

None.

#### Key learning point

- Unusual and bilateral placement of tibial stress fracture.

#### Ethical approval

Written informed consent was obtained from the patient for publication of this case report and accompanying images.

#### Author contributions

Melih Malkoc: study design; Tugrul Ormeci: data collection and figure preparation; Ozgur Korkmaz: writing; Ismail Oltulu: data collection; Mehmet Isyar: data collection; Mahir Mahiroglu: analysis.

#### References

- Matheson GO, Clement DB, McKenzie DC, Taunton JE, Lloyd-Smith DR, MacIntyre JG. Stress fractures in athletes. A study of 320 cases. *Am J Sports Med* 1987;**15**:46–58.
- Hulkko A [Dissertation] *Stress fractures in athletes. A clinical study of 368 cases.* Finland: Acta Univ Ouluensis, Series D: Medica 169, University of Oulu; 1988.
- Devas MB. Stress fracture of the tibia in athletes or “shin soreness”. *J Bone Joint Surg* 1958;**40B**:227–39.
- Hallel T, amit S, Segal D. Fatigue fractures of tibial and femoral shaft in soldiers. *Clin Orthop* 1976;**118**:35–43.
- Dreinhöfer KE, Reichel H, Käfer W. Strategies for prevention and management of musculoskeletal conditions. Lower limb pain. *Best Pract Res Clin Rheumatol* 2007;**21**:135e52.
- Peris P. Stress fractures. *Best Pract Res Clin Rheumatol* 2003;**17**(6):61–1043.
- Bruckner P, Bradshaw C, Khan KM, White S, Crossley K. Stress fractures: a review of 180 cases. *Clin J Sport Med* 1996;**6**(2):85–9.
- Matheson GO, Clement DB, McKenzie DC, Taunton JE, Lloyd-Smith DR, MacIntyre JG. Stress fractures in athletes. A study of 320 cases. *Am J Sports Med* 1987;**15**(1):46–58.
- Sofka C. Imaging of stress fractures. *Clin Sports Med* 2006;**25**:53e62.
- Soubrier M, Dubost JJ, Boisgard S, Sauvezie B, Gaillard P, Michel J, et al. Insufficiency fracture. A survey of 60 cases and review of the literature. *Joint Bone Spine* 2003;**70**:209e18.
- Gaeta M, Minutoli F, Scribano E, Ascenti G, Vinci S, Bruschetta D, et al. CT and MR imaging findings in athletes with early tibial stress injuries: comparison with bone. Scintigraphy findings and emphasis on cortical abnormalities. *Radiology* 2005;**235**:553e61.
- Ganiyusufoglu AK, Onat L, Karatoprak O, Enercan M, Hamzaoglu A. Diagnostic accuracy of magnetic resonance imaging versus computed tomography in stress fractures of the lumbar spine. *Clin Radiol* 2010;**65**:902e7.
- Khy V, Wyssa B, Bianchi S. Bilateral stress fracture of the tibia diagnosed by ultrasound. A case report. *J Ultrasound* 2012;**15**:130e134.
- Kilcoyne KG, Dickens JF, Rue JP. Tibial stress fractures in an active duty population: long-term outcomes. *J Surg Orthop Adv* 2013;**22**(1):50–3.
- Liimatainen E, Sarimo J, Hulkko A, Ranne J, Heikkilä JS. Orava anterior mid-tibial stress fractures. Results of surgical treatment. *Scand J Surg* 2009;**98**:244–9.
- Gabrielle M, van der Velde DC, William S, Hsu DC. Posterior tibial stress fracture: a report of three cases. *J Manipulative Physiol Ther* 1999;**22**(June (5)):341–6.

#### Open Access

This article is published Open Access at [sciedirect.com](http://sciedirect.com). It is distributed under the [IJSCR Supplemental terms and conditions](#), which permits unrestricted non commercial use, distribution, and reproduction in any medium, provided the original authors and source are credited.