

Influence of zinc supplementation on histopathological changes in the stomach, liver, kidney, brain, pancreas and spleen during subchronic exposure of Wistar rats to glyphosate

Emmanuel Vandi Tizhe · Najume Dogon-Giginya Ibrahim · Mohammed Yakasai Fatihu · Igbokwe Ikechukwu Onyebuchi · Butcher Danladi Jonathan George · Suleiman Folorunsho Ambali · Joshua Mallum Shallangwa

Received: 11 March 2013 / Accepted: 16 September 2013 / Published online: 10 October 2013
© The Author(s) 2013. This article is published with open access at Springerlink.com

Abstract A subchronic toxicity study was carried out to determine the glyphosate-induced histopathological changes in the stomach, liver, kidney, brain, pancreas and spleen of rats and the attendant ameliorative effect when pretreated with zinc at the dose rate of 50 mg/kg body weight. The rats were exposed to two doses of the glyphosate (375 and 14.4 mg/kg body weight) for the period of 8 weeks which was the duration of the study, and some groups were exposed to the glyphosate after pretreatment with zinc. The histopathological changes recorded during the study were only in the rats exposed to the glyphosate at the dose rate of 375 mg/kg body weight except the vacuolation encountered in the brains and haemosiderosis in the spleens of rats exposed to zinc alone. Degenerated mucosal epithelial cells which involved the muscularis mucosa

and the glands in the stomachs of rats were seen microscopically. Hepatic cells degeneration especially at the portal areas of the livers of rats was observed. The histopathological examination of the kidneys showed glomerular degeneration, mononuclear cells infiltration into the interstices of the tubules and tubular necrosis. The conspicuous changes seen in the brains were neuronal degeneration. Pancreatic acinar cells were degenerated while the spleen of the rats showed depopulated splenic cells in both the red and the white pulps. It was concluded that zinc supplementation in rats prior to glyphosate exposure ameliorated the histopathological changes observed in the stomach, liver, kidney, brain, pancreas and spleen with no observable alteration in the histoarchitecture in the organs of the zinc-supplemented rats.

E. V. Tizhe (✉) · N. D.-G. Ibrahim · M. Y. Fatihu
Department of Pathology, Faculty of Veterinary Medicine,
Ahmadu Bello University, Zaria, Kaduna, Nigeria
e-mail: comradevandi@yahoo.com

I. I. Onyebuchi
Department of Pathology, Faculty of Veterinary Medicine,
University of Maiduguri, Maiduguri, Nigeria

B. D. J. George
Department of Parasitology and Entomology, Faculty of Veterinary
Medicine, Ahmadu Bello University, Zaria, Kaduna, Nigeria

S. F. Ambali
Department of Pharmacology, Faculty of Veterinary Medicine,
Ahmadu Bello University, Zaria, Kaduna, Nigeria

J. M. Shallangwa
Ministry for Livestock Production, Adamawa State, Nigeria
e-mail: joshuamallum@yahoo.com

Keywords Glyphosate · Zinc · Supplementation · Subchronic · Stomach · Liver · Kidney · Brain · Pancreas · Spleen · Wistar rats

Introduction

Glyphosate, the active ingredient which is 48 % acid equivalent of the 180 propylamine salt of glyphosate (phosphonomethyl glycine), is used as a non-selective herbicide and for control of a great variety of annual, biennial and perennial grasses, broad-leaved weeds and woody shrubs in orchards, vineyards, conifer plantations and many plantation crops. It is perhaps the most important herbicide ever developed (World Health Organization 1994). Glyphosate has low persistence and, because repeated applications of this herbicide are practiced for the control of

weeds in agricultural fields, large quantities find their way into water bodies. The indiscriminate use of the herbicide therefore makes it a potential source of danger to animals, not only in grazing fields but also in the water bodies (Ayoola 2008).

The manufacturers of glyphosate-based herbicides claim their 'low toxicity and environmental friendliness', however, evidence indicates that the herbicide may not be as safe as previously thought (Franz et al. 1997). In addition, the surfactant used in a common glyphosate product (Roundup®) is more acutely toxic than the glyphosate itself, the combination of the two is yet more toxic (Santillo et al. 1989; Howe et al. 2004; Santos et al. 2005). Glyphosate had also been reported to induce oxidative stress in animals (Vivian and Claudia 2007). As an herbicide, glyphosate works not only by being absorbed into the plant mainly through its leaves but also through soft stalk tissues. It is then transported throughout the plant where it acts on various enzyme systems, inhibiting amino acid metabolism in what is known as shikimic acid pathway. This pathway exists in higher plants and microorganisms but not in animals. Plants treated with glyphosate slowly die over a period of days or weeks, and because the chemical is transported throughout the plant, no part survives (Cox 1995; Malik et al. 1989). In animals, mechanisms of toxic action have not been fully elucidated. A reduced respiratory control ratio, enhanced ATPase activity and stimulated oxygen uptake rate were observed in liver mitochondria obtained from rats given glyphosate. Based on these results, the authors suggested that these toxicological effects may be primarily due to the uncoupling of oxidative phosphorylation (Olurunsogo et al. 1979).

Oxidative stress have been implicated in the molecular mechanisms of glyphosate toxicity (Beuret et al. 2004). The body responds to oxidative stress by evoking the enzymatic defence system within the body (Vivian and Claudia 2007).

In pure chemical terms, glyphosate is an organophosphate (OP) in that it contains carbon and phosphorus. However, it does not affect the nervous system in the same way as organophosphate insecticides, and is not a cholinesterase inhibitor (Rebecca et al. 1991). Most glyphosate-containing products are either made or used with a surfactant. The surfactant used in a common glyphosate product (Roundup®) is more acutely toxic than glyphosate itself, but the combination of the two is yet more toxic (Santillo et al. 1989).

Zinc is an essential trace mineral, which means that it must be obtained from the diet since the body cannot produce enough. It is the second most abundant mineral in the body, stored primarily in the muscle; it is also found in high concentrations in red and white blood cells, the retina of the eye, bones, skin, kidneys, liver and pancreas (Belongia et al. 2001). Zinc plays an important role in the immune system, regulation of appetite, stress level, taste and smell (McClain et al. 1992). Two antioxidant mechanisms of zinc have been identified: zinc ions may replace redox active molecules such as iron and copper at critical sites in cell membranes and proteins;

alternatively, zinc ions may induce the biosynthesis of metallothione, sulfhydryl-rich proteins that protect against free radicals (Rostan et al. 2002). Owing to its mechanisms of action, zinc has been used in the amelioration of organophosphate (chlorpyrifos)-induced alterations in haematological and serum-biochemical changes in Wistar rats (Ambali et al. 2010). It has also been used to attenuate oxidative stress in arsenic- and cadmium-exposed rats (Kumar et al. 2010; Amara et al. 2008). The objective of the study was to determine the glyphosate-induced histopathological changes in rat stomach, liver, kidney, brain, pancreas and spleen and the ameliorative effect therein with the pretreatment with zinc.

Materials and methods

Experimental animals

Forty-eight adult male and female Wistar rats, 160–200 g body weight, were obtained from the Animal House of the Department of Veterinary Physiology and Pharmacology, Ahmadu Bello University, Zaria. They were housed in the Animal Room of the Department of Veterinary Pathology and Microbiology, Ahmadu Bello University, Zaria, for 2 weeks before the commencement of the experiment which lasted for 8 weeks. The rats were fed appropriately using standard rat chow (Growers mash, maize offal and ground nut cake in the ratio of 4:2:1, respectively) and water was provided ad libitum.

Chemical source

Glyphosate (Bushfire®, Monsanto Europe S. A) which contains 360 g glyphosate/l in the form of 441 g/l isopropylamine salt and zinc chloride with the following specification: M.W. 136.29, cat no. 45114, lot no. 11601 (BDH Chemical Ltd Poole England) is a white deliquescent granule with minimum assay 98.0 %, maximum limits of impurities: acid-insoluble matter 0.005 %, zinc oxide (ZnO) 1.2 %, sulphate (SO₄) 0.002 %, cadmium (Cd) 0.0005 %, calcium (Ca) 0.001 %, copper (Cu) 0.0005 %, iron (Fe) 0.001 %, lead (Pb) 0.001 %, magnesium (Mg) 0.001 %, potassium (K) 0.001 % and sodium 0.001 % were purchased from a reputable chemical store in Zaria.

Subchronic toxicity study

Forty-eight adult male and female Wistar rats used for the study were randomized into six groups of eight Wistar rats each as described below:

- Group I (DW) served as the control and were administered 2 ml/kg of distilled water daily.
- Group II (Z) were administered zinc at the dose rate of 50 mg/kg body weight (Ambali et al. 2010).

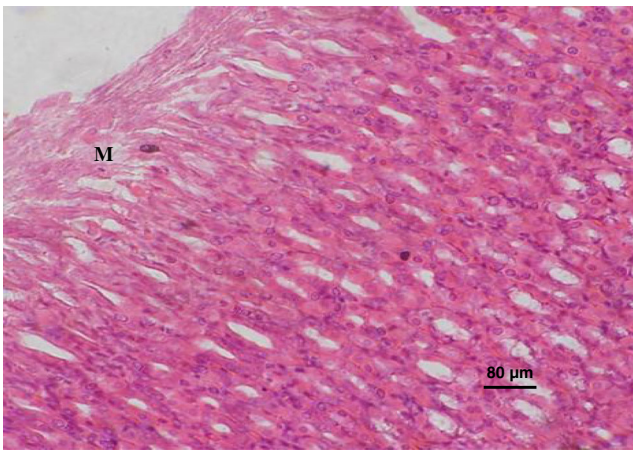


Fig. 1 Photomicrograph of a section of the stomach of a rat exposed to glyphosate only at 375 mg/kg. Note the degenerated mucosal epithelial cells (*M*) (H & E stain)

Group III (G) were administered glyphosate (10 % of the LD_{50}), 375 mg/kg (Tizhe 2012).

Group IV (Z + G) were administered zinc at 50 mg/kg + glyphosate (10 % of the LD_{50}), 375 mg/kg body weight.

Group V (GC) were administered glyphosate at the concentration of 1:50 glyphosate and distilled water, respectively, 14.4 mg/kg body weight.

Group VI (Z + G) were administered zinc at 50 mg/kg + glyphosate at the concentration of 1:50 glyphosate and distilled water, respectively, 14.4 mg/kg body weight.

The dose regimens were administered per os by gavage once daily for a period of 8 weeks. The rats were monitored for clinical signs and death.

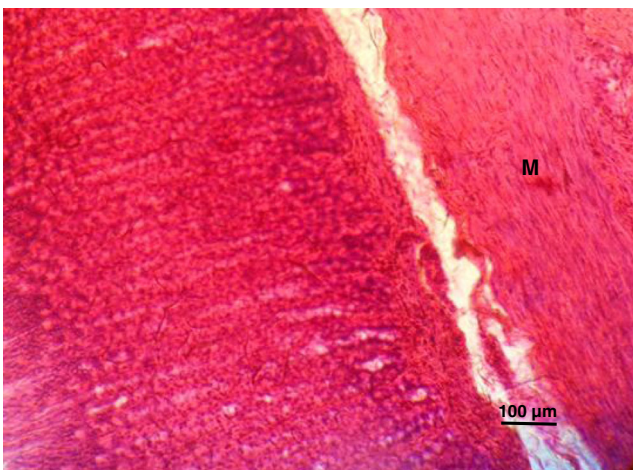


Fig. 2 Photomicrograph of a section of the stomach of a rat exposed to zinc and glyphosate at 375 mg/kg. Note no observable microscopic lesions in the mucosal epithelial cells (*M*) (H & E stain)

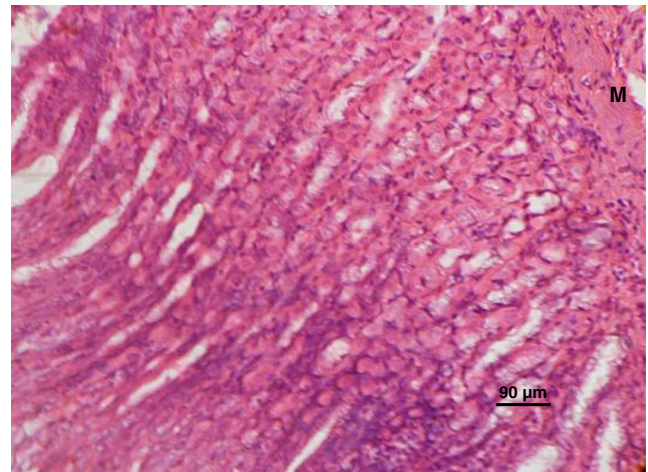


Fig. 3 Photomicrograph of a section of the stomach of a rat exposed to distilled water only. Note no observable microscopic lesions in the mucosal epithelial cells (*M*) (H & E stain)

Histopathological examination

The sections of the stomach, liver, kidney, brain, pancreas and spleen were taken for histopathological preparation and examination. The samples collected were fixed in 10 % buffered neutral formalin. They were processed for histopathological assessment using the method outlined by Baker et al. (2000) and viewed under light microscope at $\times 400$ magnification.

Results

Stomach Degenerated mucosal epithelial cells and the glands in the stomachs of rats in group III (G) were observed (Fig. 1).

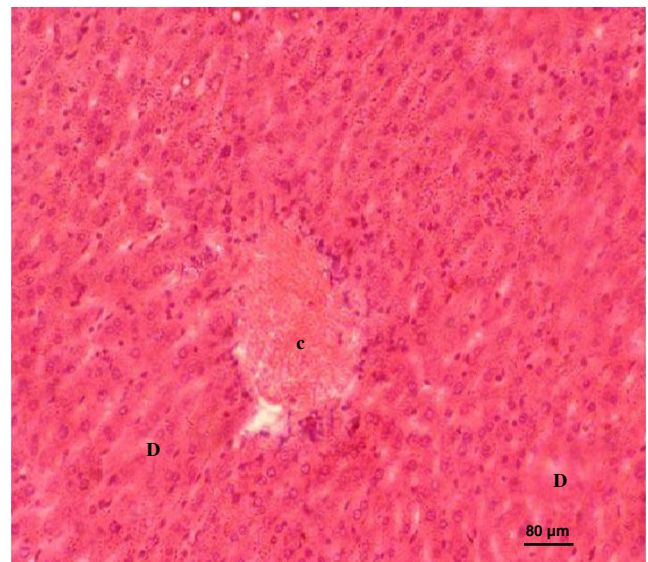


Fig. 4 Photomicrograph of a section of a liver of a rat exposed to glyphosate only at 375 mg/kg. Note the degenerated hepatic cells (*D*) and congested central vein (*C*) (H & E stain)

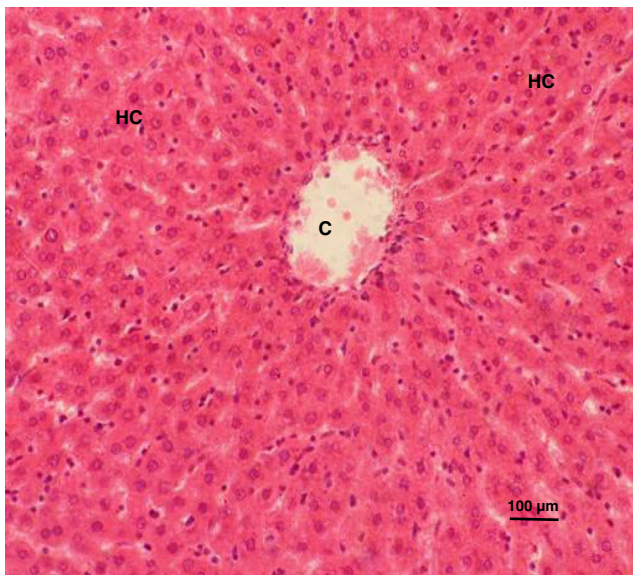


Fig. 5 Photomicrograph of a section of the liver of a rat exposed to zinc and glyphosate at 375 mg/kg. Note the relatively preserved architectural morphology of the hepatic cells (*HC*) and the central vein (*C*) of the liver (H & E stain)

The stomach of rats exposed to zinc and glyphosate showed no observable microscopic lesion; group IV (Fig. 2). The stomachs of rats in the other groups showed no observable microscopic lesion as seen in group I (DW) (Fig. 3).

Liver There were degenerative changes in some hepatocytes especially at the portal areas of the livers of rats in group III (G) (Fig. 4). The livers of rats exposed to zinc and glyphosate showed no observable microscopic lesions, group IV (Fig. 5). The liver of rats in the other group showed no observable microscopic changes as seen in group I (DW) (Fig. 6).

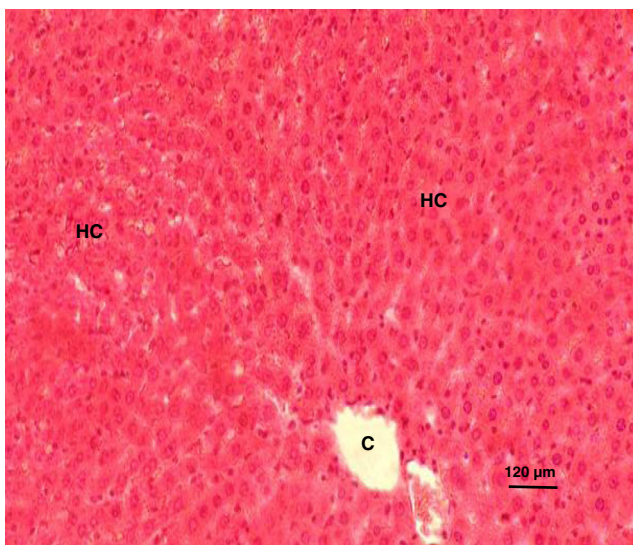


Fig. 6 Photomicrograph of a section of the liver of a rat exposed to distilled water only. Note no observable microscopic lesions in the hepatic cells (*HC*) and the central vein (*C*) of the liver (H & E stain)

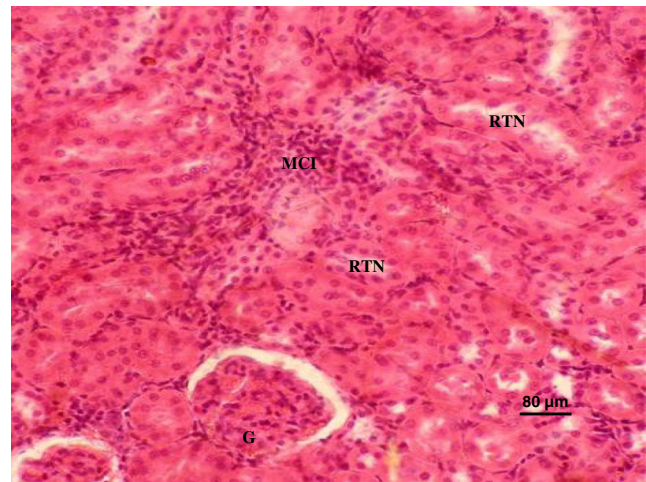


Fig. 7 Photomicrograph of a section of the kidney of a rat exposed to glyphosate at 375 mg/kg. Note the glomerular degeneration (*G*) and renal tubular necrosis (*RTN*) with mononuclear cellular infiltration into the interstices (H & E stain)

Kidney There were glomerular degeneration, mononuclear cells infiltration into the interstices and tubular necrosis in the kidneys of rats in group III (G) (Fig. 7). The kidneys of rats exposed to zinc and glyphosate showed no observable microscopic lesions, group IV (Fig. 8). The kidneys of rats in the other groups showed no observable microscopic changes as seen in group I (DW) (Fig. 9).

Brain There was neuronal degeneration in the brains of rats in group III (G) (Fig. 10) with vacuolations in the brain of rats in group II (Z) (Fig. 11). The brains of rats in group IV (Z+G) showed reduced vacuolations (Fig. 12). The brains of rats in the other groups showed no observable microscopic lesion as seen in group I (DW) (Fig. 13).

Pancreas There were degenerated pancreatic acinar cells in the pancreas of rats in group III (G) (Fig. 14). The pancreas of

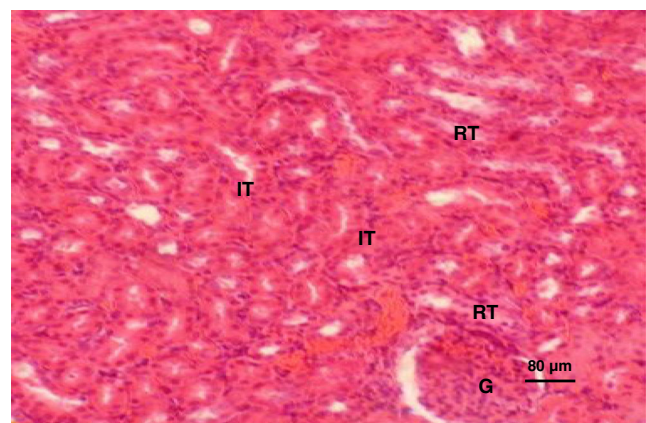


Fig. 8 Photomicrograph of a section of the kidney of a rat exposed to zinc and glyphosate at 375 mg/kg. Note no observable microscopic lesions in the glomerulus (*G*), renal tubules (*RT*) and the interstices of the tubules (*IT*) (H & E stain)

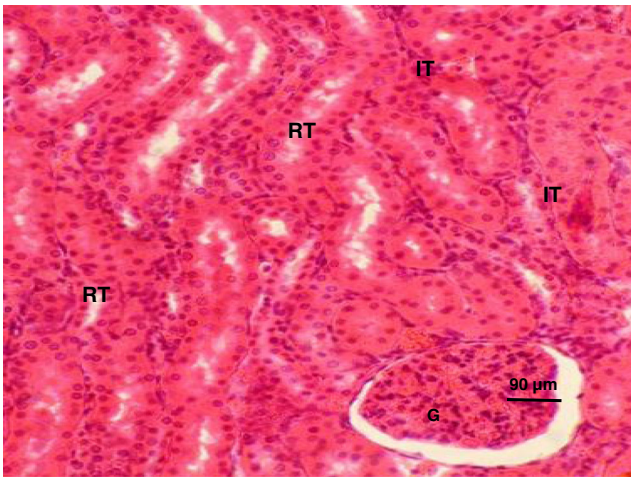


Fig. 9 Photomicrograph of a section of the kidney of a rat exposed to distilled water only. Note no observable microscopic lesions in the glomerulus (*G*), renal tubules (*RT*) and the interstices of the tubules (*IT*) (H & E stain)

rats in group IV (Z+G) (Fig. 15) was hyperplastic with distension of the interlobular septa with transudate, but the pancreas of the rats of the other groups showed no observable microscopic lesion as seen in group I (DW) (Fig. 16).

Spleen There were depopulated splenic cells (lymphoblast and lymphocytes) in both the red and the white pulps of the rats in group III (G) (Fig. 17). There was also haemosiderosis in the spleen of rats in group II and IV (Z and Z+G) (Figs. 18 and 19, respectively). The spleen of rats in the other groups showed no observable microscopic lesion as recorded in group I (DW) (Fig. 20)

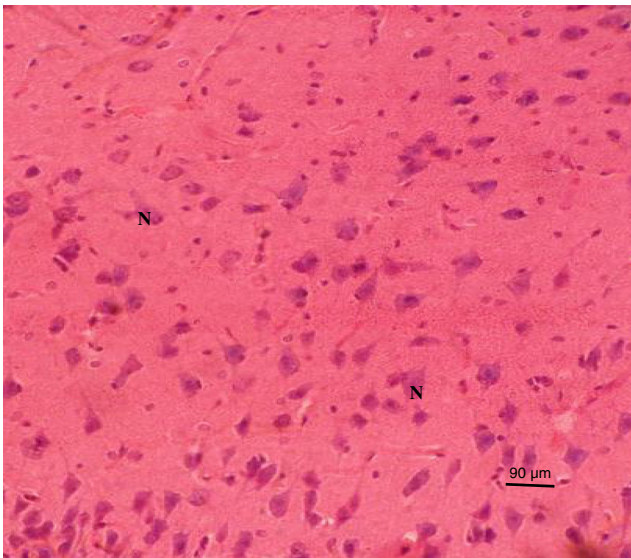


Fig. 10 Photomicrograph of a section of the brain of a rat exposed to glyphosate only at 375 mg/kg showing neuronal (*N*) degeneration (H & E stain)

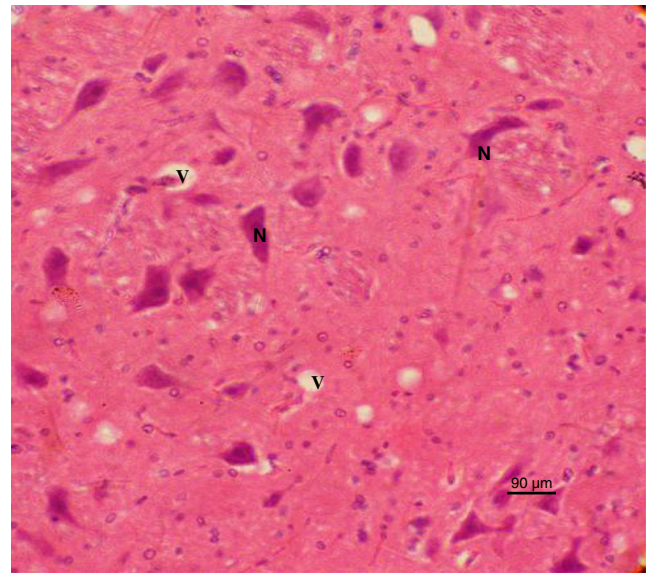


Fig. 11 Photomicrograph of a section of the brain of a rat exposed to zinc only at 50 mg/kg. Note the vacuoles (*V*) and no observable microscopic lesions in the neurons (*N*) (H & E stain)

Discussion

Histomorphology of stomach specimens exposed sub-chronically to glyphosate in the G group showed degenerated mucosal epithelial cells which involved the glands which might be sequel to the oxidative damage in mucosal epithelial cells since the pathophysiology of glyphosate toxicity has been reported to be through oxidative stress (Beuret et al. 2004; Vivian and Claudia 2007). Sastry and Sharma (1981) had reported erosion of the gastric mucosa as the only visible lesion probably caused by oxidative stress following exposure to sub-lethal concentration of diazinon in fresh water teleost

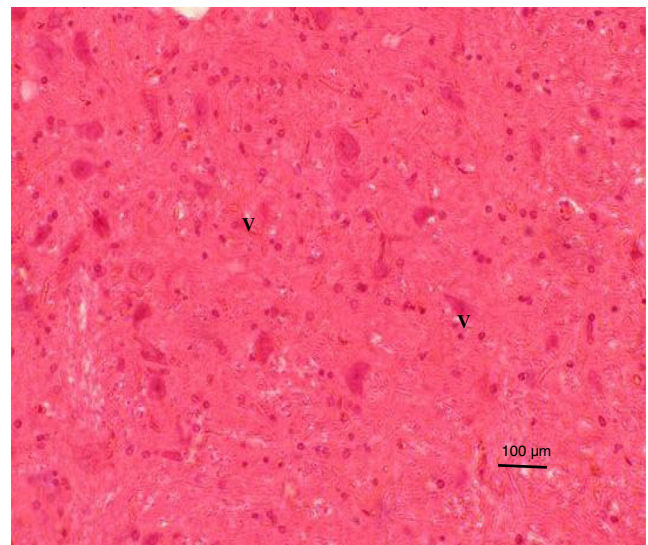


Fig. 12 Photomicrograph of a section of the brain of a rat exposed to zinc and glyphosate at 375 mg/kg. Note the reduced vacuolations (*V*) (H & E stain)

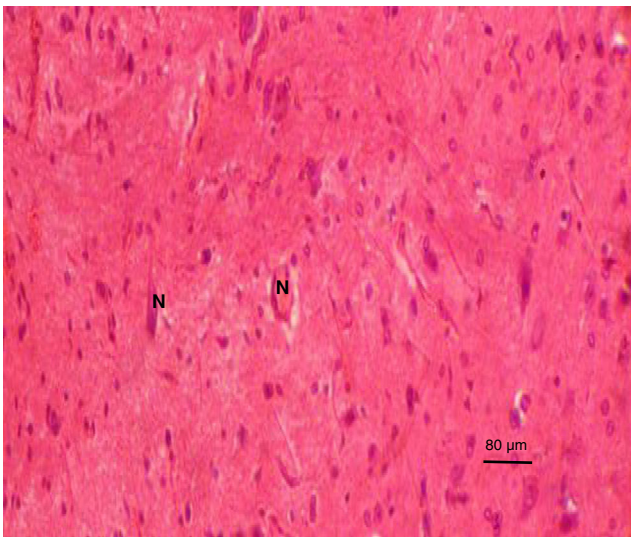


Fig. 13 Photomicrograph of a section of the brain of a rat exposed to distilled water only. Note no observable microscopic lesions in the neurons (*N*) (H & E stain)

fish, *Ophiocephalus punctatus*. However, the stomach specimens of rats in the GC group in this study showed no observable microscopic lesions.

The stomach specimens of rats in the Z, Z+GC and the DW group also had no recognizable microscopic lesion; however, administration of Zinc in the Z+G group ameliorated the histomorphologic changes in the stomach by acting as an antioxidant as reported by Powell (2000).

Histomorphologically, the portal areas, of the livers had degeneration, focal degeneration to diffusely degenerated hepatocytes in some rats sub-chronically exposed to glyphosate in the G group which might be due to oxidative stress. The rats exposed to the low dose of glyphosate in the GC group had no

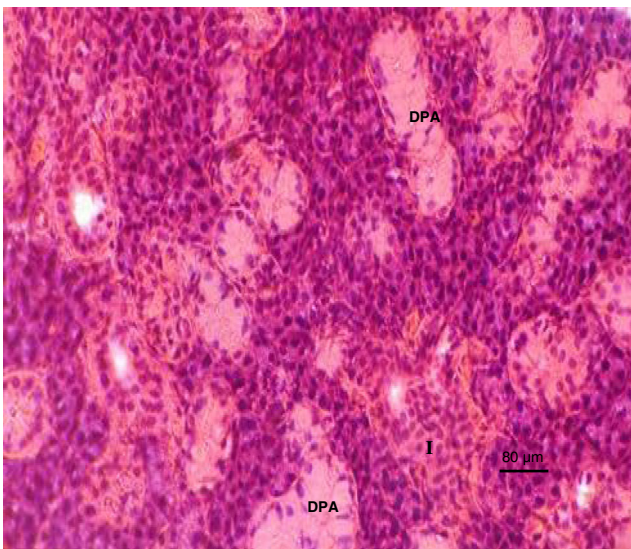


Fig. 14 Photomicrograph of a section of the pancreas of a rat exposed to glyphosate at 375 mg/kg. Note the degenerated glandular pancreatic acinar cells (*DPA*) and islet of Langerhans (*I*) (H & E stain)

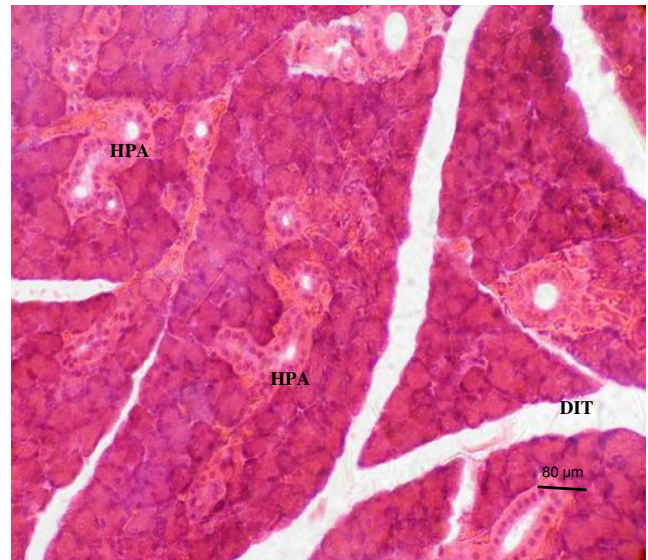


Fig. 15 Photomicrograph of a section of the pancreas of a rat exposed to zinc and glyphosate at 375 mg/kg. Note the hyperplastic glandular pancreatic acinar cells (*HPA*) and distension of the interlobular septa by transudate (*DIT*) (H & E stain)

observable microscopic lesion. These observations are in tandem with the previous studies (Benedetti et al. 2004; Caglar and Kolankaya 2008) where increased Kupffer cells were seen in hepatic sinusoids of glyphosate-treated rats exposed to higher doses, 487 and 560 mg/kg, respectively, unlike in those rats exposed to 4.87, 48.7 or 56 mg/kg. The infiltration of Kupffer cells were followed by large deposition of reticular fibers, mononuclear cell infiltration and congestion of the liver tissues Benedetti et al. (2004) reported that these could have

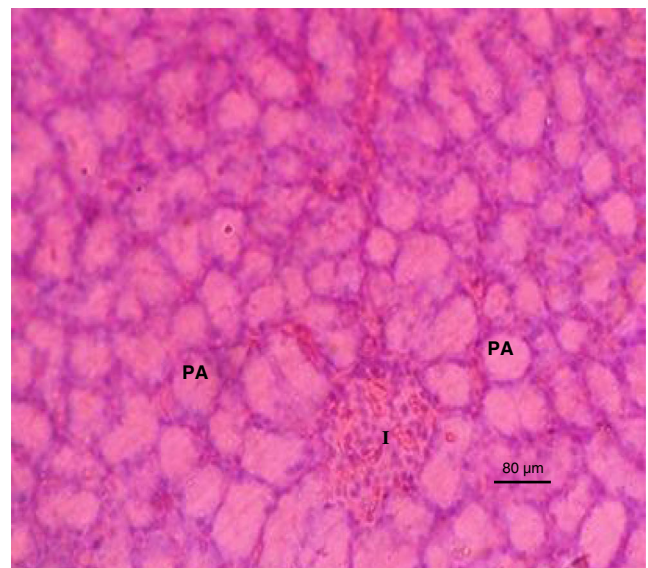


Fig. 16 Photomicrograph of a section of the pancreas of a rat exposed to distilled water only. Note no observable microscopic lesions in the glandular pancreatic acinar cells (*PA*) and the islet of Langerhans (*I*) (H & E stain)

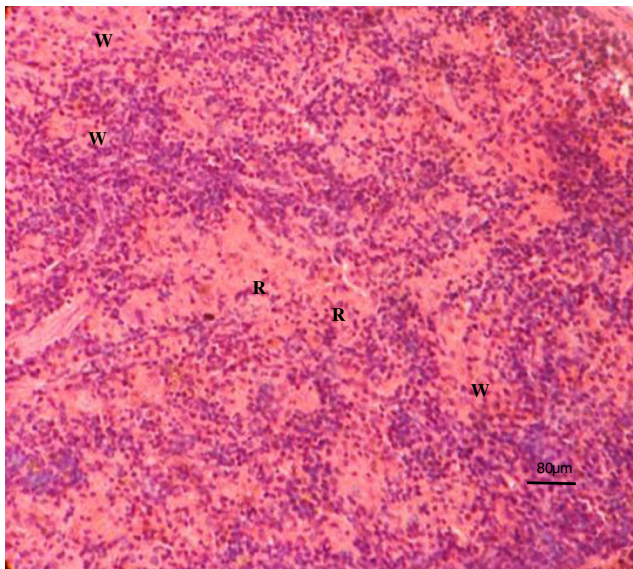


Fig. 17 Photomicrograph of a section of the spleen of a rat exposed to glyphosate only at 375 mg/kg. Note the depopulated splenic cells in both the white (*W*) and the red (*R*) pulps (H & E stain)

contributed to the impairment of regular function of the liver due to xenobiotics modification in detoxification processes.

There were no observable microscopic lesions in the Z, Z+GC and the DW groups. However, supplementation with zinc in Z+G showed an abolishing effect of zinc in the hepatotoxicity induced by the glyphosate in G group, thus demonstrating the antioxidant effect of zinc since there was a positive relationship between the oxidative damage due to glyphosate and the ameliorative effect therein by the zinc. The hepatoprotective effect of zinc had been previously observed in an oxidative stress study (Goel and Dhawan 2001).

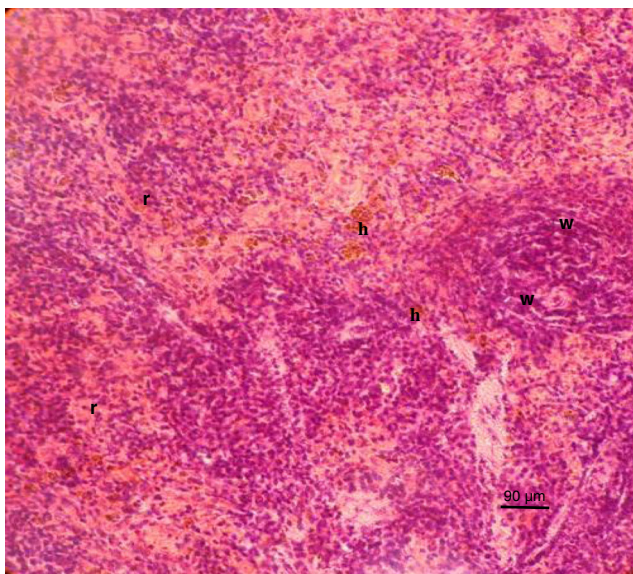


Fig. 18 Photomicrograph of a section of the spleen of a rat exposed to zinc only at 50 mg/kg. Note hemosiderosis (*h*) with no other observable microscopic lesions in both the red (*r*) and the white (*w*) pulps (H & E stain)

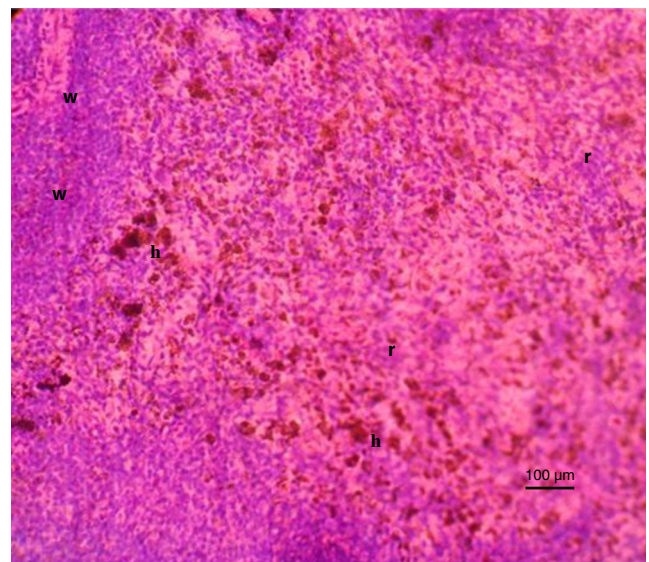


Fig. 19 Photomicrograph of a section of the spleen of a rat exposed to zinc and glyphosate at 375 mg/kg. Note the hemosiderosis (*h*) with no other observable microscopic lesions in both the red (*r*) and the white (*w*) pulps (H & E stain)

Histopathologic lesions seen in the kidney of the rats sub-chronically exposed to glyphosate in the G group were glomerular and renal tubular degeneration with infiltration of mononuclear cells to the interstices of the kidney which might be consequent upon increased free radicals production in the rats which overwhelmed the endogenous antioxidants produced by the body. In a recent study, mild congestion and haemorrhage, mild focal coagulative necrosis and sloughing of tubular epithelial cells in oxidative stress condition in chickens followed chronic chlorpyrifos (CPF) exposure (Kammon et al. 2011). Oxidative stress was also said to cause

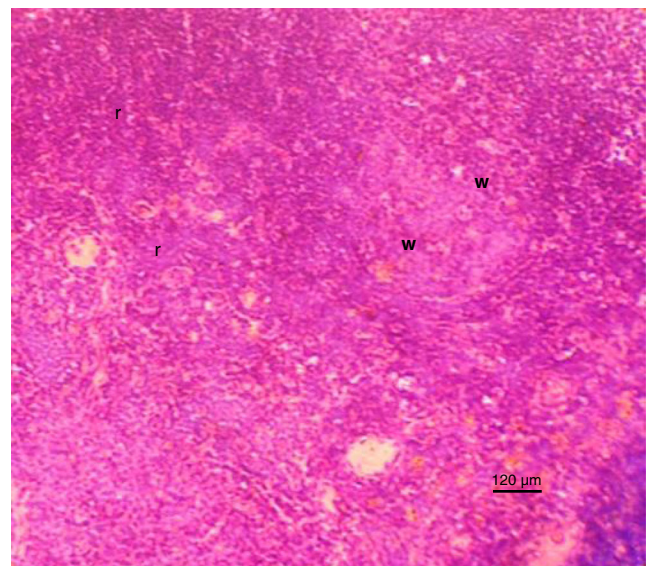


Fig. 20 Photomicrograph of a section of the spleen of a rat exposed to distilled water only. Note no observable microscopic lesions in both the red (*r*) and the white (*w*) pulps (H & E stain)

Shrinkage of the glomerular network, necrosis of proximal tubules and ruptured distal collecting tubules (Sastry and Sharma 1981).

The renal tubules are particularly sensitive to toxic influences because they have high oxygen consumption, vulnerable enzyme systems and complicated transport mechanisms that may be used for transport of toxins and may be damaged by such toxins during excretion and/or elimination (Tisher and Brenner 1989). The presence of necrosis might be related to the depletion of ATP (Shimizu et al. 1996), possibly through the direct toxic effect on the cell function (Kammon et al. 2011), which might involve reactive free radicals, oxidative stress or both (Alden and Frith 1992).

Such nephrotoxic effects induced by glyphosate were absent in the rats in the Z, Z+GC and the DW groups and might have been ameliorated in the Z+G group by the antioxidant effect of zinc.

The histopathologic changes induced sub-chronically in rats brains exposed to high dose of glyphosate in G group in this study was neuronal cells degeneration which was believed to be caused by oxidative stress. However, those exposed to low glyphosate concentration in GC group showed no recognizable lesion. This finding is similar to the result of previous study by Ayoola (2008), who reported neuronal degeneration, mononuclear cells infiltration and severe spongiosis in catfish exposed to acute concentrations of glyphosate for 96 h. Such neuronal degeneration and mild degeneration in purkinge cells had been similarly observed in oxidative stress condition in chickens (Kammon et al. 2011).

The brain of rats in Z group showed vacuolations probably due to the pro-oxidant function of zinc as reported by Abdallah and Samman (1993). There was no recognizable lesion in the brains of rats in the Z+GC and the DW groups. Supplementation with zinc in the Z+G showed ameliorative effects in the brain of the rats since there were relatively preserved neuronal cells in the brains of the rats in the group. Thus, the degeneration of neuronal cells in both the glyphosate-treated group and the combination of the glyphosate with zinc-treated group indicated that its toxic effects in the brains were not abolished, but ameliorated and that probably, the severity of the neurotoxicity were not reversible or abolished by the antioxidant effect of zinc within the experimental period and condition. Similar oxidative stress condition was shown to be attenuated by the antioxidant effect of zinc following neuronal degenerative changes sub-chronically induced by malathion in rats (Brocardo et al. 2007).

The oxidative damage seen in the pancreas of rats in the G group was focal areas of degenerated pancreatic acinar cells and the haemosiderosis recorded might be due to erythrophagocytosis whereas rats in GC group showed no observable microscopic lesion.

Kammon et al. (2011) similarly recorded degeneration of glandular acini, mild necrosis of the glandular cells and mild

degeneration of beta islets of Langerhans with distension of interlobular septa of pancreas probably induced by oxidative stress in chickens following chronic CPF exposure. The rats in the Z, Z+GC and the DW groups had histomorphologically normal pancreas.

In the Z+G zinc-supplemented group, there was amelioration of the degenerative changes caused by the glyphosate at 375 mg/kg and the pancreases of the rats were hyperplastic with distension of the interlobular septa by transudate.

Histopathological examination in the present study showed depopulation of splenic cells which involved the lymphoblasts and lymphocytes in both red and white pulps of rats in the G group. These changes might be associated with the oxidative stress caused by the exposure to glyphosate. The rats had no observable microscopic changes in their spleens in the GC group. Based on the observed degenerative changes of splenic cells, glyphosate appears to be a potent immuno-suppressive agent under the present experimental condition and period. The probable immuno-suppressive effect of glyphosate was earlier reported by Blackley (1997). The absence of microscopic lesions in the spleens of rats in the Z and the DW groups and the lymphocytes proliferation in both red and white pulps of the spleens from rats with administration of zinc in the Z+G and the Z+GC groups tend to suggest that there was an ameliorative effect, probably due to zinc administration which prevented the immuno-suppressive effect that was observed in the G group by its antioxidant function as reported by Rostan et al. (2002).

Conclusion

It was concluded that zinc supplementation ameliorated the histopathological changes observed sequel to subchronic glyphosate exposure in the stomach, liver, kidney, brain, pancreas and spleen of rats.

Open Access This article is distributed under the terms of the Creative Commons Attribution License which permits any use, distribution, and reproduction in any medium, provided the original author(s) and the source are credited.

References

- Abdallah SM, Samman S (1993) The effect of increasing dietary zinc on the activity of superoxide dismutase and zinc concentration in erythrocytes of healthy female subjects. *Eur J Clin Nutr* 47:327–332
- Alden CL, Frith CH (1992) Urinary system. In: Hashek WM, Rousseaux CG (ed) 1992. *Handbook of toxicologic pathology*. Academic Press, San Diego, pp. 316–379
- Amara S, Abdelmelek H, Garrel C, Guiraud P, Douki T, Ravanat J, Favier A, Sakly M, Ben RK (2008) Preventive effect of zinc against cadmium-induced oxidative stress in the rat testis. *J Reprod Dev* 54(2):129–134

- Ambali SF, Abubakar AT, Shittu M, Yaqub SL, Anafi SB, Abdullahi A (2010) Chlorpyrifos-induced alteration of haematological parameters in Wistar rats: ameliorative effects of zinc. *Res J Environ Toxicol* 4:55–66
- Ayoola SO (2008) Histopathological effects of glyphosate on Juvenile African Catfish (*Clarias gariepinus*). *Am-Eur J Agric Environ Sci* 4(3):362–367
- Baker J, Silverton RE and Pillister CJ (2000) Dehydration, impregnation, embedding technique and section preparation. *Introduction to Medical Laboratory Technology*, 7th edition, pp. 199–242
- Belongia EA, Berg R, Liu KA (2001) A randomized trial of zinc nasal spray for adults. *Am J Med* 111(2):103–108
- Benedetti AL, Vituri C, Trentin AG, Domingues MAC, Alvarez-Silva M (2004) The effects of sub-chronic exposure of Wistar rats to the herbicide glyphosate-biocarb. *Toxicol Lett* 153(2004):227–232
- Beuret CJ, Fanny Z, Maria SG (2004) Effects of the herbicide glyphosate on liver lipoperoxidation in pregnant rats and their fetuses. *Reprod Toxicol* 19(4):501–504
- Blakley BR (1997) Effect of round up and tordon 202C herbicides on antibody production in mice. *Vet Hum Toxicol* 39:204–206
- Brocardo PS, Assin F, Franco JL, Pandolfo P, Muller YMR, Takahashi RN, Dafre AL, Rodrigues ALS (2007) Zinc attenuates malathion-induced depressant-like behaviour and confers neuroprotection in the rat brain. *Toxicol Sci* 97(1):140–148
- Caglar S, Kolankaya D (2008) The effect of sub-acute and sub-chronic exposure of rats to the glyphosate based herbicide Roundup. *Environ Toxicol Pharmacol* 25:57–62
- Cox C (1995) Herbicide factsheet: glyphosate, part 1. *Toxicol J Pestic Reform* 15:3
- Franz JE, Mao MK, Sikorski JA (1997) Glyphosate: a unique global herbicide (Acs Monograph 189). American Chemical Society, Washington
- Goel A, Dhawan DK (2001) Zinc supplementation prevents liver injury in chlorpyrifos-treated rats. *Biol Trace Elem Res* 82(1–2):185–200
- Howe CM, Berrill M, Pauli DB, Helbing CC, Werr K, Veldhoen N (2004) Toxicity of glyphosate-based pesticides to four North American frog species. *Environ Toxicol Chem* 23:1928–1938
- Kammon AM, Brar RS, Sodhi S, Banga HS, Singh J, Nagra NS (2011) Chlorpyrifos chronic toxicity in broilers and effect of vitamin C. *Open Vet J* 1:21–27
- Kumar A, Malhotra A, Nair P, Garg M, Dhawan DK (2010) Protective role of zinc in ameliorating arsenic-induced oxidative stress and histopathological changes in rat liver. *J Environ Pathol Toxicol Oncol* 29(2):91–100
- Malik J, Barry G, Kishore G (1989) The herbicide glyphosate. *Biofactor* 2:17–25
- McClain CJ, Staurt M, Vivian B (1992) Zinc status before and after zinc supplementation of eating disorders in patients. *J Am Coll Nutr* 11: 694–700
- Olurunsogo O, Bababunmi E, Bassir O (1979) Effect of glyphosate on rat liver mitochondria in vivo. *Bull Environ Toxicol* 2:257–264
- Powell SR (2000) The Antioxidant Properties of Zinc. *J Nutr* 130:1447S–1454S
- Rebecca LT, Guang-Yang Y, Wei-Jin T, Hsiao-min C, Jou-Fang D (1991) Survey of glyphosate-surfactant herbicide ingestion. *Clin Toxicol* 29(1):91–109
- Rostan EF, DeBubys HV, Madey DL, Pinnell SR (2002) Evidence supporting zinc as an important antioxidant for skin. *Int J Dermatol* 49(9):606–611
- Santillo DJ, Leslie DM, Brown PW (1989) Responses of small mammals and habitat to glyphosate application on clearcuts. *J Wildl Manag* 53(1):164–172
- Santos JB, Ferreira EA, Kasuya MCM, Silva AA, Procopio SO (2005) Tolerance of Bradyrhizobium strains to glyphosate formulations. *Crop Prot* 24:543–547
- Sastry KV, Sharma K (1981) Diazinon-induced histopathological and hematological alterations in a fresh water teleost, *Ophiocephalus punctatus*. *Ecotoxicol Environ Saf* 5(3):329–340
- Shimizu S, Eguchi Y, Kamiike W, Waguri S, Uchiyama Y, Matsuda H, Tsujimoto Y (1996) Retardation of chemical hypoxia-induced necrotic cell death by Bcl-2 and ICE inhibitors: possible involvement of common mediators in apoptotic and necrotic signal transductions. *Oncogene* 12:2045–2050
- Tisher CC, Brenner BM (1989) Renal pathology with clinical and functional correlation, vol 1. Lippincott, Philadelphia
- Tizhe EV (2012) Influence of zinc supplementation on the pathology of subchronic exposure of Wistar rats to glyphosate. Unpublished M.Sc Thesis, Ahmadu Bello University, Zaria
- Vivian DCL, Claudia BRM (2007) Toxicity and effects of a glyphosate-based herbicide on the Neotropical fish *Prochilodus lineatus*. *Comp Biochem Physiol C: Toxicol Pharmacol* 147(2):222–231
- World Health Organization (1994) Glyphosate Environmental Health Criteria No. 159. UNEP/ILO/WHO, Geneva, 177