



## Case report

## Use of the pericoronal tissue of impacted third molar in subgingival connective tissue autograft: A case report

Alice Becker<sup>a,d,\*</sup>, Jean-François Garnier<sup>c</sup>, Nabil Benahmed<sup>a</sup>, Rémi Curien<sup>d</sup>, Julie Guillet<sup>a,b</sup><sup>a</sup> Faculté d'odontologie de Lorraine, Département de chirurgie orale, Université de Lorraine, 7 avenue de la forêt de Haye-BP 20199, 54505 Vandœuvre-lès-Nancy CEDEX, France<sup>b</sup> Service d'Odontologie, CHRU de Nancy, Hôpitaux de Brabois, rue Morvan, 54511 Vandœuvre-lès-Nancy, France<sup>c</sup> Service de Chirurgie-Maxillo-Faciale et Plastique, Hôpitaux Universitaires de Strasbourg, Hôpital de Hautepierre, avenue Molière, 67200 Strasbourg, France<sup>d</sup> Service d'odontologie, CHR Metz-Thionville, 1 Allée du Château CS45001, 57085 Metz CEDEX 3, France

## ARTICLE INFO

## Keywords:

Pericoronal tissue  
Subepithelial autograft  
Dental follicle  
Periodontal recession  
Case-report

## ABSTRACT

**Introduction and importance:** The pericoronal tissue, or dental follicle, is a connective tissue found around impacted teeth crown. The dental follicle is involved in odontogenesis, dental eruption and periodontogenesis. **Case presentation:** A young woman presented a vestibular U-shaped periodontal recession localized in tooth 26. After consent the patient underwent a local intervention combining the extraction of her included 28 and a mucogingival management of her periodontal recession localized in 26, using the pericoronal sac of the tooth of 28 has been used as a subepithelial connective autograft.

The results 6 weeks after surgery showed a significant gain in thickness and a gain in height of attached gingiva of 26.

**Clinical discussion:** The success of the use of pericoronal sac in subepithelial connective autograft may allow to spare the use of a healthy harvesting site. Furthermore, the dental follicle is often available in young patients with prophylactic extraction of impacted 3rd molars. However, one pericoronal sac may provide enough connective tissue, only for the surgical treatment of a unique recession site.

**Conclusion:** The use of the pericoronal sac has shown promising results in the treatment of periodontal recessions. Wider applications could be investigated using the pericoronal sac in the future.

## 1. Introduction

Periodontal recessions correspond to a migration of the marginal gingiva apically of the cemento-enamel junction, and are endemic lesions found in oral cavity [1].

The autograft of connective tissue requires a palatal sampling, leading to the multiplication of operating sites and consequently increasing the risk of morbidity. The extractions of impacted teeth are a daily procedure in oral surgery. The pericoronal tissue, or dental follicle, is a connective tissue involved in the development of the dental organ and periodontal support tissues, located around the crown of impacted or erupting teeth [2,3]. Henceforth, it seemed possible to use this untapped pluripotent connective tissue for the surgical treatment of periodontal recessions, at the same session as the extraction of impacted teeth.

We present here a case of use of the dental follicle of a wisdom tooth

in the surgical treatment of a periodontal recession.

Henceforth, it seems possible to use this untapped pluripotent connective tissue for the surgical treatment of periodontal recessions, at the same session as the extraction of impacted teeth.

This work has been reported in line with SCARE criteria [4].

## 2. Case presentation

A 19-years-old woman, with no significant medical history and reporting only an occasional smoking, went to her attending dentist in a liberal city practice. She described a significant dentine hypersensitivity in the upper left jaw. The prophylactic indication for avulsion of the 4 impacted wisdom teeth had been established few months ago, after having lately completed an orthodontic treatment (Fig. 1) [5].

The clinical examination revealed a good oral hygiene. In the upper left jaw, a gingival U-shaped recession, measuring 4 mm high and 3 mm

\* Corresponding author at: CHR Mercy, 1 allée du château, 57530 Ars-Laquenexy, France.

E-mail address: [researchmailbeckeralice@gmail.com](mailto:researchmailbeckeralice@gmail.com) (A. Becker).

<https://doi.org/10.1016/j.ijscr.2021.106045>

Received 22 April 2021; Received in revised form 24 May 2021; Accepted 26 May 2021

Available online 28 May 2021

2210-2612/© 2021 Published by Elsevier Ltd on behalf of IJS Publishing Group Ltd. This is an open access article under the CC BY-NC-ND license

(<http://creativecommons.org/licenses/by-nc-nd/4.0/>).

large, is present on the labial surface of the tooth 26. The papillae were preserved, and a 1 mm high attached gingival border was present in the apical part of the lesion (Fig. 2). The recession corresponded to stage I of Miller's classification, which is managed first medically and then surgically according to the therapeutic gradient rule. No other periodontal or endodontic damage were noted concerning the tooth 26. The patient's general periodontium was healthy and without significant inflammation or gingival bleeding. The periodontal biotype was defined as a type 3 of Wilson's classification, with a keratinized gingiva of normal thickness but a thin scalloped bone support [6]. According to Chicago's Classification of periodontal diseases (2017), this lesion is considered to be a clinical healthy reduced periodontium in a patient with no history of periodontitis [7].

A medical treatment was first carried out for one month. A single application of a 5% fluoride dental varnish at 22,600 ppm has been performed during the appointment. Then the patient was asked to use a toothpaste containing tin and sodium fluorides at the concentration of 1450 ppm every day.

However, the patient did not notice any significant improvement in her dentine hypersensitivity and a surgical treatment was therefore considered. According to scientific evidences, a surgical approach using a subepithelial connective tissue graft in combination with a coronally positioned flap has been proposed [6,8]. The multiplicity of surgical procedures and sites worried the patient. Indeed, she had to undergo the extraction of the 4 wisdom teeth by her dentist, then the subepithelial connective tissue graft on tooth 26 with a palatal harvest. It was therefore decided, in agreement with the patient, to use the pericoronal tissue as an autologous graft to allow the management of the recession, and avoid the palate harvesting site surgery. Written post-operative instructions were given to the patient (cold, liquid or soft food, total avoidance of smoking after the operation, strict oral hygiene). Once the 15-days reflexion period has elapsed, the patient signed a consent form before undergoing the surgery.

The extraction of the tooth 28 was performed and the pericoronal tissue was carefully harvested. The dental follicle was placed in a saline solution to maintain cell activity while awaiting revascularization by the graft procedure. At the same time, a vestibular intrasulcular incision was made in teeth 25, 26 and 27, preserving the interdental papillae. A partial thickness dissection was carried out up to the mucogingival junction, using the Allen's tunnelling technique, to limit the

devascularization of the gingival tissues (e.g. Fig. 3) [9].

The graft was previously cut to the dimensions of the loss of gingival substance, then deposited directly in contact with tooth 26 allowing the covering of the exposed part of the roots. The graft was then sutured with 5-0 prolene without compressing the tissue to ensure its neo-vascularization. No immediate post-operative complications.

The patient was medicated with an association of paracetamol and codeine (500 mg/30 mg 4 to 6 times a day) and mouthwash with chlorhexidine (0,2%) twice a day for 7 days.

At 8 days, the patient reported no pain. The integrity of the graft was clinically confirmed by the presence of a pale pink colour with no sign of necrosis. While the thickness gain was preserved, a loss of height with a slight retraction of the graft was noted (Fig. 4). At 45 days, the thickness gain increased. The gain in height was estimated at 2 mm compared to the initial situation (Fig. 5).

At 6 months, the gain in volume obtained by the sub-epithelial connective tissue graft was stable. However, the mesial root of 26 was not completely covered by this surgical procedure. A gingival recession of 1 mm high persisted on the mesial root.

The patient no longer reported any sensitivity. She did not wish to resort to a second surgical procedure to obtain a complete coverage of the gingival recession and felt completely satisfied with the obtained results.

### 3. Clinical discussion

The aim of this clinical case was to report the use of pericoronal tissue in the treatment of periodontal recession by subepithelial grafting of this tissue. To our knowledge, this use has never been described before.

It has been shown that human dental follicle cells (DFC) have a similar phenotype to the periodontal ligament dental cells (PLDC), but are assimilated to pluripotent stem cells [10]. PLDC have a differentiation potential into cells which constitute the periodontal ligament, the cementum, and the alveolar bone.

Guo S. et al. explored the use of DFCs and PDLCs in periodontal regeneration *in vitro* and *in vivo*, and showed in their study that better results were obtained with DFCs [10].

In embryogenesis, DFCs derive from neural crest cells, which have remarkable embryonic attributes both *in vitro* and *in vivo*. In addition,

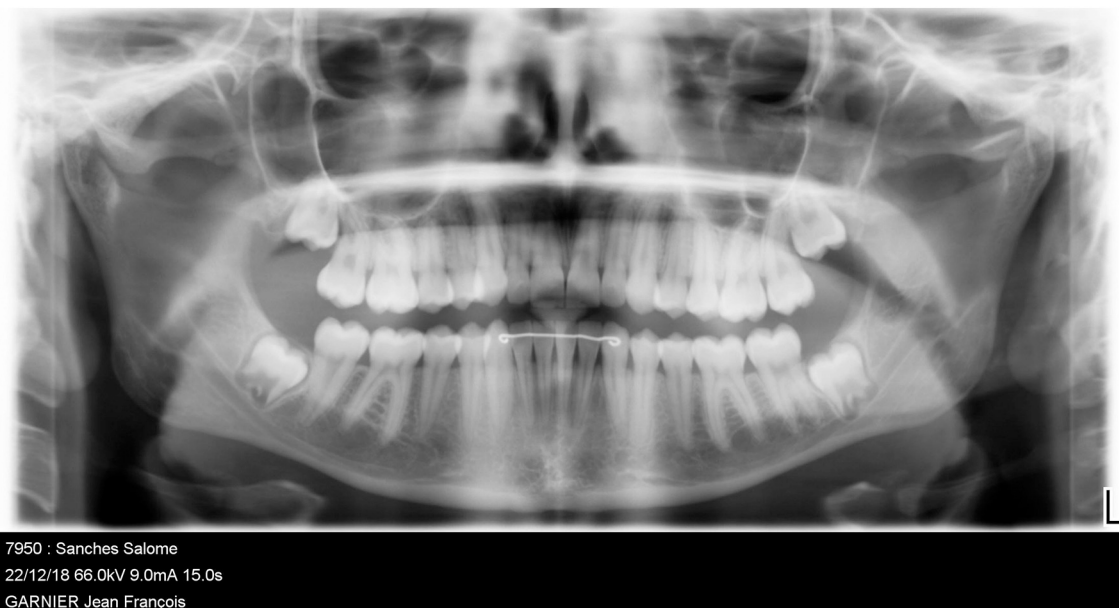


Fig. 1. Initial panoramic radiography before surgery.

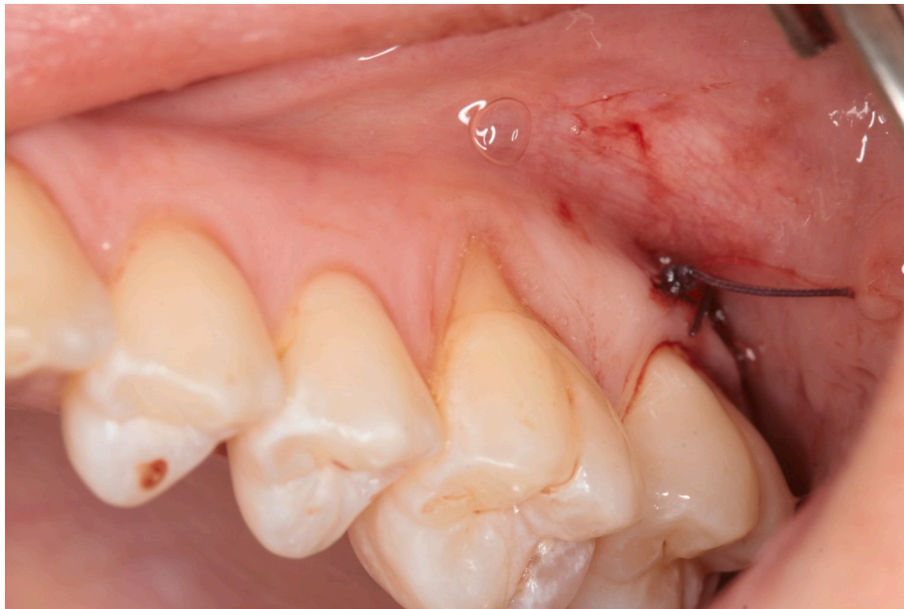

Fig. 2. Initial vestibular lesion observed in the tooth 26 before muco-gingival management.

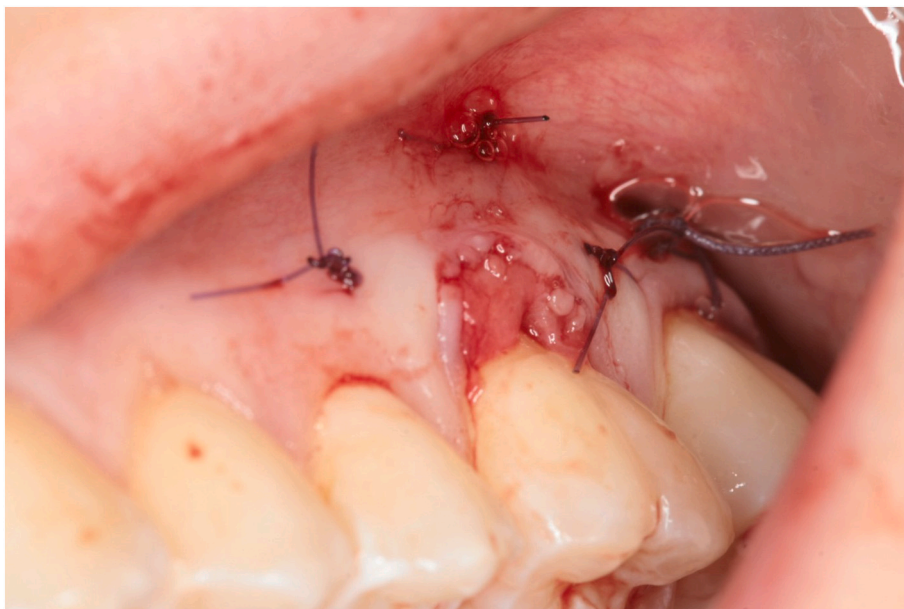


Fig. 3. Root coverage by the pericorony sac of 28 after muco-gingival management of 26.

foetal stem cells have very low immunogenicity and tumorigenicity, making them great candidates for regenerative techniques [11].

However, the dental follicle around impacted teeth may be a potential source of cystic and tumoral pathologies of the jaws, due to the degeneration of odontogenic cells [2]. Satheesan et al. showed that the dental follicle of impacted teeth can lead to pathological changes, such as cysts, benign or even very exceptionally malignant tumors. These pathologies have still only been observed in case of impacted teeth [2].

The technique presented previously does not allow a regeneration *ad integrum* of the periodontium. Existing grafting techniques do not recreate all the tissues of the periodontium, especially the alveolar bone and the desmodont [9]. In our clinical case, it is hoped that tissue regeneration would bring a better tissue regeneration than other grafting technics.

The use of the dental follicle as a subepithelial connective tissue

autograft shows its interest in the treatment of gingival recession in our clinical case, especially to gain in thickness of attached tissue. Subepithelial connective tissue grafting requires a healthy harvesting site. The main harvesting sites are either the palatal connective tissue, edentulous ridge, or maxillary tuberosity [9]. This prerequisite leads to a risk of complications at the harvesting site, particularly in terms of bleeding, infection, delayed healing and pain [9]. There are several advantages in our case: 1) avoid a palatal harvest and thus warding off the possible complications of another surgical site, 2) decrease the number of surgical procedures 3) use a very easy harvesting tissue. Using the tunnelling technique first described by Allen allows limiting the devascularization of the gingival tissues and promoting the grafting of the dental follicle [9].

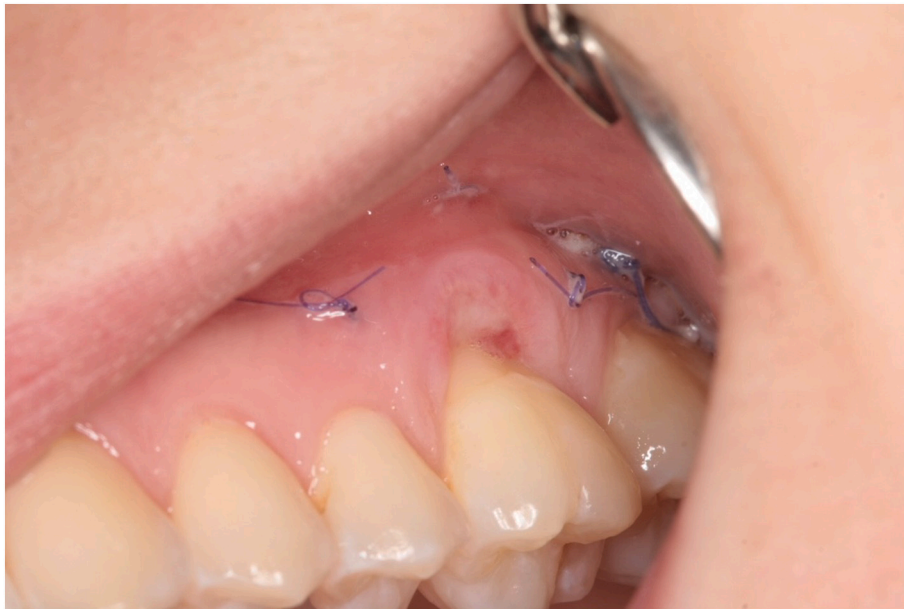

Fig. 4. Situation 8 days after root-covering surgery on tooth 26.

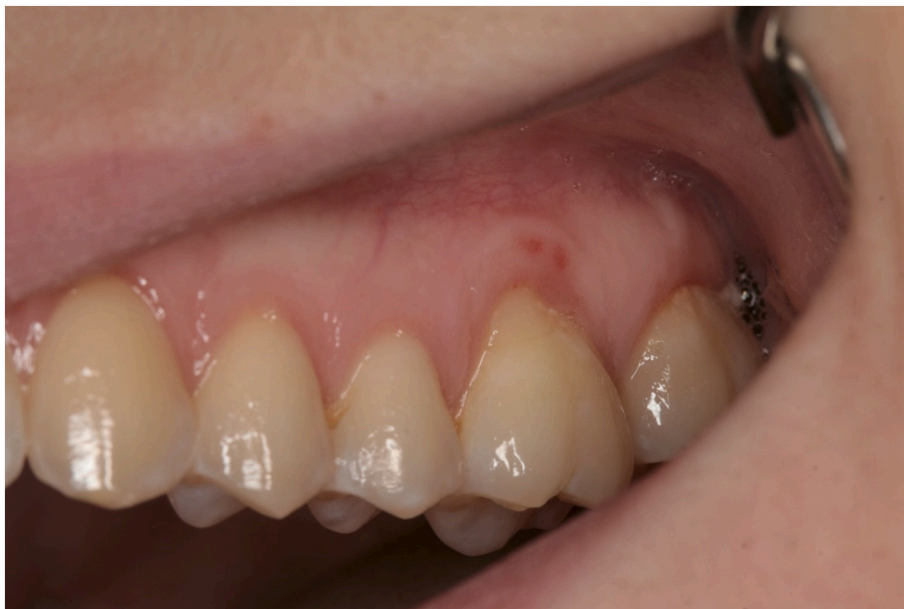

Fig. 5. Situation 45 days after root-covering surgery on tooth 26.

#### 4. Conclusion

Even though the use of the pericoronal tissue increased the thickness of the attached gum, the indications for this procedure remain limited. This technique can only be proposed when there is an associated indication to extract an impacted third molar, an impacted supernumerary tooth or an impacted non-preservable tooth. This constraint prevents our technique to replace routinely palatal sampling. However, this case shows the histophysiological potential of pluripotent cells of the dental follicle and has the merit of raising the question of the fantastic possibilities of healing of the oral cavity.

Knowing the fate of the follicular sac and its involvement in periodontal establishment, would it be possible to consider the pericoronal sac by using it in the treatment of other oral tissue loss or periodontal diseases?

#### Consent

Written informed consent was obtained from the patient for publication of this case report and accompanying images. A copy of the written consent is available for review by the Editor-in-Chief of this journal on request.

#### Provenance and peer review

Not commissioned, externally peer-reviewed.

#### Ethical approval

Exception from ethical approval because the study was a case report. The patient provided her consent to undergo the procedures described in

this case report and for her data and images to be published.

### Funding

No funding was received.

### Guarantor

Becker, Alice.

### Research registration number

None declared.

### CRediT authorship contribution statement

**Alice Becker:** Writing – Original draft.

**Jean-François Garnier:** Conceptualization.

**Benahmed Nabil:** Writing – Review and editing.

**Rémi Curien:** Writing – Review and editing.

**Julie Guillet:** Writing – Review and editing, Supervision.

### Declaration of competing interest

All authors declare that there are no financial and personal relationships with other people or organisations that could inappropriately influence their work.

### Acknowledgment

The authors would like to thank the patient for his compliance and

his authorization to publish this case.

### References

- [1] M.M. Kassab, R.E. Cohen, The etiology and prevalence of gingival recession, *J. Am. Dent. Assoc.* Feb;134 (2) (2003) 220–225.
- [2] Satheesan E, Tamgadge S, Tamgadge A, Bhalerao S, Periera T. Histopathological and radiographic analysis of dental follicle of impacted teeth using modified Gallego's stain. *J. Clin. Diagn. Res.* 2016 May;10(5):ZC106–111.
- [3] M.J. Honda, M. Imaizumi, S. Tsuchiya, C. Morsczech, [Dental follicle stem cells and tissue engineering](#), *J. Oral Sci.* 52 (4) (2010) 541–552.
- [4] Agha RA, Franchi T, Sohrabi C, Mathew G, Kerwan A, Thoma A, et al. The SCARE 2020 guideline: updating consensus Surgical CAse REport (SCARE) guidelines. *Int. J. Surg.* 2020 Dec;84:226–30.
- [5] Richardson M. Some aspects of lower third molar eruption. *Angle Orthod.* vol 44. 1974 Apr;141–5.
- [6] Kahn S, Almeida R, Dias A, Rodrigues W, Barceleiro M, Taba M. Clinical considerations on the root coverage of gingival recessions in thin or thick biotype. *Int J Periodontics Restorative Dent* 2016 May;36(3):409–15.
- [7] Caton JG, Armitage G, Berglundh T, Chapple ILC, Jepsen S, Kornman KS, et al. A new classification scheme for periodontal and peri-implant diseases and conditions - introduction and key changes from the 1999 classification. *J. Clin. Periodontol.* 2018 Jun;45:S1–8.
- [8] Chambrone L, Chambrone D, Pustiglioni FE, Chambrone LA, Lima LA. Can subepithelial connective tissue grafts be considered the gold standard procedure in the treatment of Miller Class I and II recession-type defects? *J. Dent.* 2008 Sep;36 (9):659–71.
- [9] [V. Monnet-Corti, M. Pignoly, C. Goubron, C. Fouque, S. Melloul, H. Lugari, Chirurgie plastique parodontale: indications et techniques, 2019, p. 17.](#)
- [10] Guo S, Guo W, Ding Y, Gong J, Zou Q, Xie D, et al. Comparative study of human dental follicle cell sheets and periodontal ligament cell sheets for periodontal tissue regeneration. *Cell Transplant.* 2013 Jun;22(6):1061–73.
- [11] Tan Z, Su Z, Wu R, Gu B, Liu Y, Zhao X, et al. Immunomodulative effects of mesenchymal stem cells derived from human embryonic stem cells in vivo and in vitro. *J Zhejiang Univ Sci B* 2011 Jan;12(1):18–27.