

Case report

Retinal vasoproliferative tumor in a case of X-linked retinoschisis detachment

Nimesh A. Patel^a, Diana Laura^a, Kimberly D. Tran^a, Stanley Chang^b, Gaetano Barile^c,
Audina M. Berrocal^{a,*}

^a Department of Ophthalmology, Bascom Palmer Eye Institute, 900 NW17th St., Miami, FL 33136, USA

^b Department of Ophthalmology, Edward S. Harkness Eye Institute, 635 W 165th St., New York, NY 10032, USA

^c Department of Ophthalmology, Manhattan Eye, Ear, & Throat Hospital, 210 E 64th St. #3, New York, NY 10065, USA

ARTICLE INFO

Keywords:

X-linked retinoschisis
Vasoproliferative tumor
Retinal detachment

ABSTRACT

Purpose: To describe the first published case of X-linked retinoschisis (XLRS) detachment with retinal vasoproliferative tumor (RVPT) and provide a literature review of the subject.

Observations: The authors describe a case of a 17 year old male with X-linked retinoschisis who presented with a retinal detachment and a retinal vasoproliferative tumor. The patient was treated with pars plana vitrectomy, endolaser, subtenon's kenalog and anti-VEGF (vascular endothelial growth factor) intravitreal injections. He regained 20/60 vision with a flat macula and had significant resolution of the associated vasoproliferative leakage seen on fluorescein angiography.

Conclusions and importance: This case adds XLRS to the conditions associated with RVPT and gives support for treatment with laser photocoagulation and anti-VEGF therapy with bevacizumab to control the exudative process.

1. Introduction

X-linked Retinoschisis (XLRS) was first described by Joseph Haas in 1898¹. It is a congenital retinal dystrophy caused by mutations of the RS1 gene with the locus on the X chromosome, Xp22.1². The RS1 gene encodes for the retinoschisin protein. Retinoschisin is believed to function in cellular adhesion and intercellular interactions. The characteristic clinical finding is foveal schisis with a spoke pattern which contain microcystic cavities in the neurosensory retina.^{1,3,4}

Solitary peripheral retinal vascular masses, first termed “presumed acquired retinal hemangiomas” by Shields et al., in 1983⁶, and later renamed “vasoproliferative retinal tumors” have been described.^{6,7} Retinal Vasoproliferative tumors (RVPT) are benign masses, and are preferentially located inferotemporally between the equator and ora serrata.^{7,8} Some authors propose that the RVPT may be caused by reactive astrocytic hyperplasia, and that “reactionary retinal gliovascularization” is a more descriptive term for this clinical entity.⁹ They are categorized as primary, if they are idiopathic, or secondary, if they are associated with an underlying ocular condition.⁸

In this report, we describe the first known case of RVPT in association with a XLRS detachment.

2. Case

This is a case of a 17-year-old male with known diagnosis of XLRS presenting with decreased vision in the left eye with symptoms of flashes and floaters for 6 weeks. History includes prosthesis in the right eye after attempted retinal detachment repair as a child. The left eye had undergone encircling, non-segmented, scleral buckling surgery for a nasal, rhegmatogenous retinal detachment 3 years prior. The eye had recovered central acuity to the 20/60 range OS. Increasing outer retinal fluid with posterior extension toward the macula led to consultation and considerations for surgical intervention.

Upon presentation, visual acuity in the left eye was 20/100-1. An early posterior capsular opacity was present in the lens. Fundus exam of the left eye revealed large schisis retinal cavities, inferior retinal detachment (Fig. 1) with macula involvement, and a mass with enlarged vessels inferotemporally (Fig. 2). Optical coherence tomography (OCT) revealed exudative retinal detachment. Intra-operative fluorescein angiography displayed enlarged vessels with late leakage inferiorly (Fig. 3) consistent with RVPT.

The patient was managed surgically with a pars plana vitrectomy, hyaloid removal, endolaser to the vasoproliferative tumor, silicone oil placement, intravitreal bevacizumab and subtenon's kenalog injection.

Post-operatively the patient received four rounds of intravitreal bevacizumab as well as further indirect diode laser applied to the tumor

* Corresponding author.

E-mail address: ABerrocal@med.miami.edu (A.M. Berrocal).

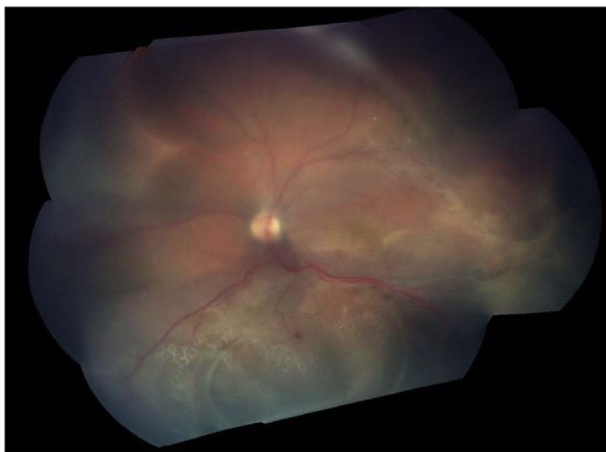


Fig. 1. Fundus photo with inferior schisis detachment.

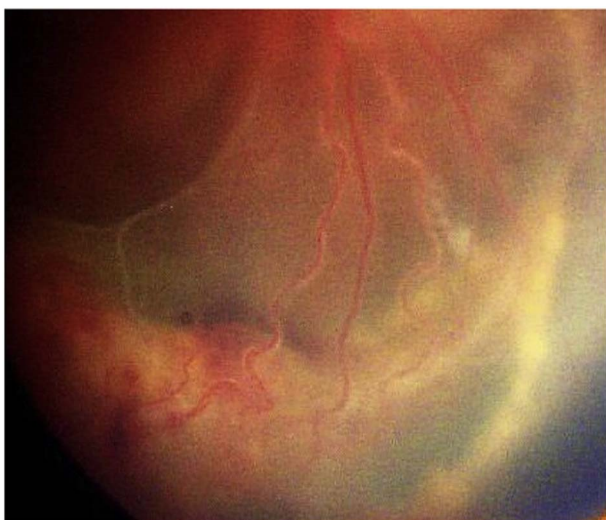

Fig. 2. Fundus photo with inferior vasoproliferative tumor.

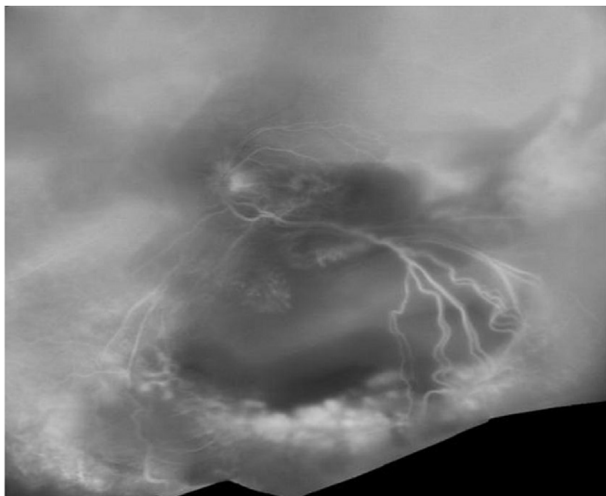


Fig. 3. Late phase wide field fluorescein angiography with enlarged vessels with late leakage inferiorly.

in the inferotemporal periphery under anesthesia. He had a 2 + posterior subcapsular cataract that was later removed and a 3 piece IOL was inserted into the sulcus. Silicone oil was left in place for stability.

After 2 years of follow-up examination, the patient had improved

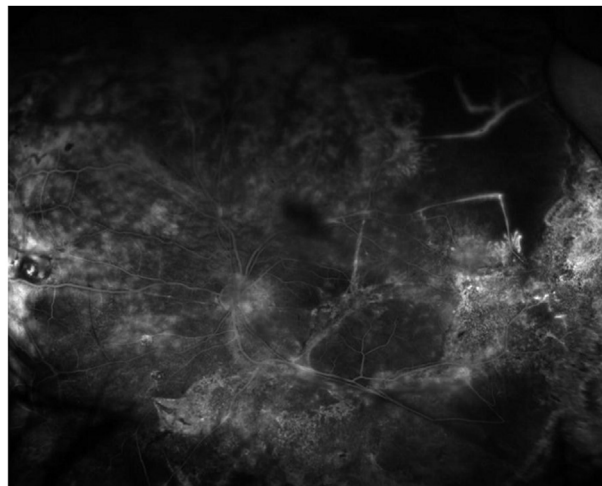


Fig. 4. Fluorescein angiography post treatment with regression of the vasoproliferative tumor.

visual final acuity of 20/60. The macula was flat and there was regression of the vasoproliferative tumor peripherally (Fig. 4).

3. Discussion

The pathogenesis for RVPT is unknown. The literature suggests that the significant proliferative activity is astrocytic, and that the vascular component is secondary to vasoformative factors released by the glial cells.^{9,10} Microscopically, these tumors are seen to have thrombosis and intraluminal endothelial cell proliferation and fibrin deposits, and RPE proliferation within a glial mass.⁹

Treatment for RVPT has been achieved with multiple methods.^{11,15} In this case anti-VEGF using bevacizumab therapy in conjunction with diode laser photocoagulation was used. There was no change in the dose of anti-VEGF in the setting of silicone oil. The role of photocoagulation in this case was to cause direct tissue damage to the telangiectatic vessels.¹⁶ This was effective in achieving regression of the exudation of the glial mass.

RVPT has been described in several juvenile conditions.¹³ There have been previous accounts of vascular lesions in association with XLS. In 1992, prior to Shields description of RVPT, De Laey et al. described a typical “angioma” in a patient with XLS. It was hypothesized that this occurrence was a coincidental finding.¹² It is possible that this was a report of RVPT prior to it being well described.

Other vascular abnormalities have been associated with XLS. In 1998, Fong et al. described two cases of exudative retinal detachment associated in XLS and conducted a literature review. These authors concluded that there was vascular incompetence as well as “telangiectatic dendrites” seen in prior reports. In addition, certain aneurysmal formations have been found. It is possible that these vascular changes represent part of the spectrum of RVPT as has been described by Shields.^{6,7}

RVPT has been reported in association with scleral buckle. It is possible that ischemia from the buckle contributed in this case by leading to angiogenic factors.^{13,17}

There have been prior reports of RVPT in conjunction with peripheral retinoschisis. However, these were secondary schisis in the setting of pars planitis, which was not present in our case.¹⁸

4. Conclusion

Our report demonstrates a RVPT in association with XLS retinal detachment. Previous reports have shown several vascular abnormalities associated with XLS. This case adds XLS to the conditions associated with RVPT and gives support for treatment with laser

photocoagulation and anti-VEGF therapy with bevacizumab to control the exudative process.

Patient consent

Patient verbally consented to the use of the case for publication. This report does not contain any personal information that could lead to the identification of the patient.

Acknowledgements and disclosures

Funding

No funding or grant support.

Conflicts of interest

The authors have no financial disclosures.

Authorship

All authors attest that they meet the current ICMJE criteria for Authorship.

Other contribution

None.

References

1. Tantri A, Vrabec TR, Cu-Unjieng A, Frost A, Annesley WH, Donoso LA. X-linked retinoschisis: a clinical and molecular genetic review. *Surv Ophthalmol*. 2004;49(2):214–230.
2. Iordanous Y, Sheidow TG. Vitrectomy for x-linked retinoschisis: a case report and review of the literature. *Can J Ophthalmol*. 2013;48:e71–e74.
3. Fong DS, Frederick AR, Blumenkranz MS, Walton DS. Exudative retinal detachment in x-linked retinoschisis. *Ophthalmic Surg Laser*. 1998;29:332–335.
4. Molday RS, Kellner U, Weber BHF. X-linked juvenile retinoschisis: clinical diagnosis, genetic analysis, and molecular mechanisms. *Prog Retin Eye Res*. 2012;31(3):195–212.
5. Shields JA, Decker WL, Sanborn GE, Augsburger JJ, Goldberg RE. Presumed acquired retinal hemangiomas. *Ophthalmology*. 1983;90:1292–1300.
6. Shields CL, Shields JA, Baret J, De Potter P. Vasoproliferative tumors of the ocular fundus. *Arch Ophthalmol*. 1995;113:615–623.
7. Shields CL, Kaliki S, Al-Dahmash S, et al. Retinal vasoproliferative tumors. *JAMA Ophthalmol*. 2013;131(3):328–334.
8. Irvine F, O'Donnell N, Kemp E, Lee WR. Retinal vasoproliferative tumors: surgical management and histological findings. *Arch Ophthalmol*. 2000;118:563–569.
9. Khawly JA, Matthews JD, Machermer R. Appearance and rapid growth of retinal tumor (reactive astrocytic hyperplasia?). *Graefes Arch Clin Exp Ophthalmol*. 1999;273:78–81.
10. Cebeci Z, Oray M, Tuncer S, Tugal Tutkun I, Kir N. Intravitreal dexamethasone implant (Ozurdex) and photodynamic therapy for vasoproliferative retinal tumours. *Can J Ophthalmol*. 2014;49(4):e83–84.
11. De Laey JJ, Heintz B, Pollet L. Retinal angioma and juvenile sex-linked retinoschisis. *Ophthalmic Paediatr Genet*. 1992;13:73–76.
12. Shields JA, Reichstein D, Mashayekhi A, Shields CL. Retinal vasoproliferative tumors in ocular conditions of childhood. *JAAPOS*. 2012;16(1):6–9.
13. Garcia-arumi J, Distefano LN, Fonollosa A, Quijano C, Corcostegui B. Management of vision-threatening complications of vasoproliferative tumors of the retina. *Ophthalmic Res*. 2015;54(1):34–40.
14. Krivosic V, Massin P, et al. Management of idiopathic retinal vasoproliferative tumors by slit lamp laser or endoplaser photocoagulation. *Am J Ophthalmol*. 2014;158:154–161.
15. Parlitsis GJ, Warden SM, D'Amico DJ. Vasoproliferative tumor of the retina in association with scleral buckle for retinal detachment. *IOVS*. April 2009;50:3178.
16. Pollack A, McDonald H, Shields C, et al. Peripheral retinoschisis and exudative retinal detachment in pars planitis. *Retina*. Dec. 2002;22(6):pp719–724.
1. Tantri A, Vrabec TR, Cu-Unjieng A, Frost A, Annesley WH, Donoso LA. X-linked