



# Revision knee surgery: the practical approach

Paolo Salari  
Andrea Baldini

- Revision total knee arthroplasty (rTKA) is a challenging procedure with often unreproducible results. A step-by-step approach is fundamental to achieving good outcomes.
- Successful surgery requires a correct diagnosis of the original cause of failure. Only with an accurate and detailed plan can surgeons overcome difficulties presented in this scenario.
- Any bone loss should be prevented during prosthetic component removal. Efficient tools must be chosen to avoid time-consuming manoeuvres.
- Joint reconstruction based on a 'dual-zone' fixation is essential to provide a long-term survivorship of the implant. The use of relatively short fully cemented stems combined with a biological metaphyseal fixation is highly recommended by authors.
- Flexion and extension gaps are accurately balanced after the establishment of the tibial platform.
- Varus-valgus laxity is commonly managed with a condylar constrained prosthesis. If hinged implants are required, a stronger implant fixation is needed to counteract constraints forces.

**Keywords:** reconstruction; revision total knee arthroplasty; surgical techniques

Cite this article: *EFORT Open Rev* 2021;6:495-500.  
DOI: 10.1302/2058-5241.6.210018

## Introduction

Revision total knee arthroplasty (rTKA) is a challenging procedure and is usually associated with worse results when compared with primary knee arthroplasty.<sup>1</sup> In this scenario, surgeons have to deal with different technical issues related to surgical exposure, bone loss management and implant selection.<sup>2</sup> In the current article, authors provide a practical guide to approach revision knee surgery.

## Preoperative evaluation

Understanding the cause of the prosthetic failure before proceeding to joint revision is of primary importance. Revision surgery in 'good looking' TKAs often results in a failure and a wait-and-see phase with more accurate diagnostic assessment is recommended. Preoperative evaluation protocol should be standardized to avoid bias from missing data.<sup>3</sup> Patient history and medical records are analysed to seek for any anomalies and discrepancies with a standard perioperative course. It is always mandatory to ask for the original knee radiographs. Revision of painful prostheses, performed in pre-arthritic knees, is doomed to fail if a major cause of failure is not identified and corrected. Walking gait, knee range of motion and ligamentous stability have to be closely evaluated during clinical examination. Laboratory examinations of erythrocyte sedimentation rate and C-reactive protein are routinely performed as preoperative screening for periprosthetic joint infection in all patients undergoing revision.<sup>4</sup> In patients with laboratory abnormalities or in suspected cases with an unclear cause of failure, joint aspiration is highly recommended.<sup>5</sup> Synovial fluid analysis permits, with a single procedure, assessment of leucocyte count, polymorphonuclear cells percentage and to obtain fluid cultures. Results should follow the validated criteria of the International Consensus Meeting.<sup>6</sup> Do not hesitate to retry intraarticular aspiration in 'dry tap' knees. Aspiration with joint flexion in the 'drop-and-dangle' position puncturing through the patellar tendon using a spinal needle and pointing into the intercondylar notch of the implant may be a helpful trick for dry and scarred joints. Routine radiographic evaluation is based on standing anteroposterior (AP) and lateral X-rays to assess implant fixation status, position and size. Knee X-rays tangential to the bone-implant interface, performed with a fluoroscopic guide, could show radiolucency lines and are needed to detect subtle loosening.<sup>7</sup> The role of nuclear medicine scans in the evaluation of failed TKA is unclear and often confusing

if not performed with strict criteria.<sup>8</sup> Magnetic resonance imaging (MRI) with sequences for reduction of metal artefacts is a valuable option, when the type of failure is difficult to recognize or in the presence of soft tissue problems as in tumour-like lesions.

### Planning the revision with proper X-rays

Planning an rTKA requires a complete bilateral knee joint X-ray series which includes a standing AP view tangential to the tibial platform, a lateral view tangential to the femoral condyles, a full limb AP standing view, and an axial 45° Merchant patellar view. These X-rays should be done with a spherical metal marker to format the film dimension in the digital Picture Archiving and Communication System (PACS) which enables the surgeon to carefully plan angles and implant dimensions with such detail as to resemble a ‘preoperative navigation’. This radiographic navigation procedure should be performed in the digital PACS, having in mind all the clinical parameters of the patient (gait type, deforming forces, patient type, etc.) and the fixation rules of the ‘zonal’ fixation which requires at least two zones of adequate fixation out of the three available (epiphysis, metaphysis, diaphysis).<sup>9</sup> Canal dimensions, degrees of axial correction to match the single bone mechanical axis, and epiphyseal entry points will dictate the type and length of the stems (Fig. 1).

### Surgical approach

The skin has to be inspected to determine the mobility of the superficial layers from the fascia, and previous scar incisions should be marked out before prepping and draping. It is always recommendable to use the previous skin incision. In case of different surgical scars, the most

lateral should be used to prevent devascularization of the lateral skin flap.<sup>10</sup> It is safe to ignore previous short skin incisions (< 1.5 cm) or to cross at a perpendicular angle transverse incisions (such as those of tibial osteotomies). Creation of skin flaps at an acute angle of less than 60° at the intersection of other incisions is a risk for the blood supply.<sup>11</sup> Short skin bridges of less than 6–7 cm between incisions are not recommended. In complex situations with multiple incisions or skin adherence, plastic surgeons should be involved for skin incision design and for muscle flap procedures.<sup>12</sup> Subcutaneous tissue and skin have to be elevated in a singular thick flap to avoid damages at the microvascular plexus.

Moving deeply, the medial para-patellar capsulotomy is considered, for its extensile capabilities, the workhorse approach to the knee. Afterwards a sub-periosteal dissection of the medial structures of the proximal tibia with the release of the deep medial collateral ligament (MCL) to the postero-medial capsule is performed. The superficial MCL may be elevated more distally to extend the medial release. To gain adequate joint exposure, intraarticular adhesions are released and wide synovectomy is performed in the supra-patellar pouch, medial and lateral gutters. Lateral retinacular release and lateral patellar facetectomy are helpful to increase patellar mobility as part of the initial approach to the lateral gutter. At this point the tibia can be externally rotated to gain exposure and to reduce tension on the extensor mechanism, and the patella can be subluxated laterally, avoiding any releasing of the patellar ligament. We generally do not evert the patella, as it may increase the risk of injury to the patellar tendon and is often unnecessary for adequate exposure.<sup>13</sup>

### Component removal

Different techniques have been described in the literature for implant removal.<sup>14</sup> An optimized tool set composed of a reciprocating saw, a bone impactor, a small osteotome and a pointed impactor make this phase fast and effective. Implant extraction should be performed cautiously and in a systematic manner to avoid major bone loss and periprosthetic fractures. The first step is the modular polyethylene liner removal that can be easily performed with the use of a lever (i.e. the tip of a standard Hohmann retractor) or cutting the pivot in rotating implants. Implant-specific instrumentations have to be used in systems with a screw or interlocking parts. Destruction of the plastic liner with saws or osteotomes through sagittal cuts should be considered if specific instruments are missing. Removal of the space-occupying insert reduces the tension in the patellar and femoro-tibial structures, increasing the level of exposure. The second step is the removal of the femoral component. A reciprocating sawblade is used to undermine the femur from the medial

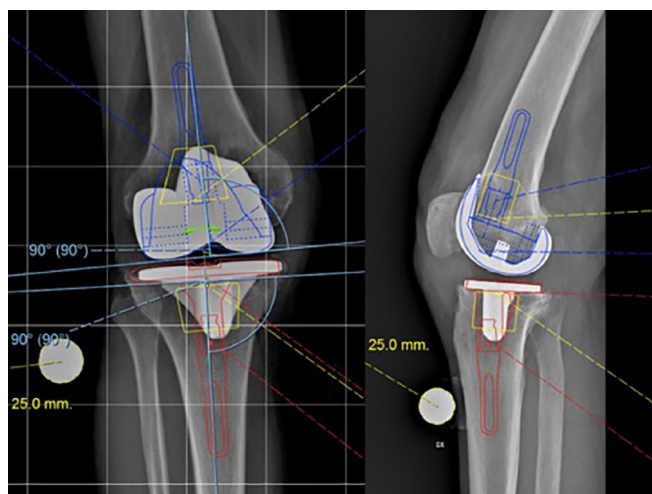
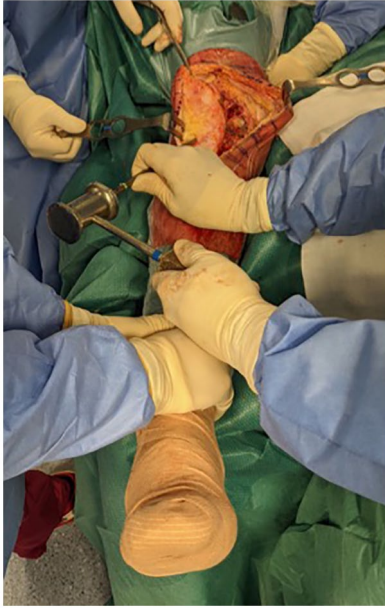

Fig. 1 Digital templating.



**Fig. 2** Tibial component extraction.

and lateral side. It is advanced below the component's surface as much as possible until the pegs or the box area is reached. Posterior chamfer and posterior condyle are undermined with osteotomes to avoid damage to the surrounding soft tissues. In patients with a stemmed implant, an anterior femoral cortex osteotomy or a complete window may be created to allow component loosening or to remove residual cement.<sup>15</sup> The last step is to remove the tibial component. The inferior tibial surface is approached with the use of the reciprocating saw in a parallel direction from the anterior and posterior aspect of the tibial keel taking care of the surrounding soft tissue. Then a pointed blunt impactor is inserted through the metaphyseal tibial bone lateral to the patellar tendon to hammer the component (Fig. 2). The removal of cones or sleeves is one of the biggest challenges due to the bone ingrowth. In a modular implant, components should be disengaged firstly to expose the sleeve/cone–bone interface. This allows the disruption of the bone ingrowth into the porous metal, then a universal stem extractor can be used to remove the remaining implant.

### Extensile approaches

Extensile approaches, other than a long medial parapatellar approach with patellar dislocation, are required very rarely. The best modern indications for a tibial tubercle osteotomy (TTO) are: in combination with a lateral approach (for previous incisions or simultaneous hardware removal), with the aim of elevating a patella baja which will impinge the tibial insert in flexion, in knee ankylosis,

and as a way to open the tibial metaphysis to approach a well-fixed cone or sleeve. A TTO should always be considered after proximal dissection and after executing a manipulation in flexion of the joint. A TTO without these actions would open the joint window just for the surgeon but will prevent the mobilization of the quadriceps and the elongation of the packed fibres of the retracted muscle with subsequent poor performance of the patient regarding postoperative knee flexion. The tibial tubercle is longitudinally osteotomized for at least 7 cm on the medial side and a periosteal is maintained laterally.<sup>16</sup> The distal end of the fragment is obliquely cut to avoid stress-riser tibial fractures. The fragment is reattached with wires passed behind the tibial stem and fixation is usually reinforced with medullary screws. These also avoid proximo-distal migration with subsequent de-tension of the cerclage wiring. If the dimensions of the bone block are fulfilled and the fixation is stable the joint may be protected only during stair-climbing and straight-leg-raise exercises for 3–4 weeks postoperatively.

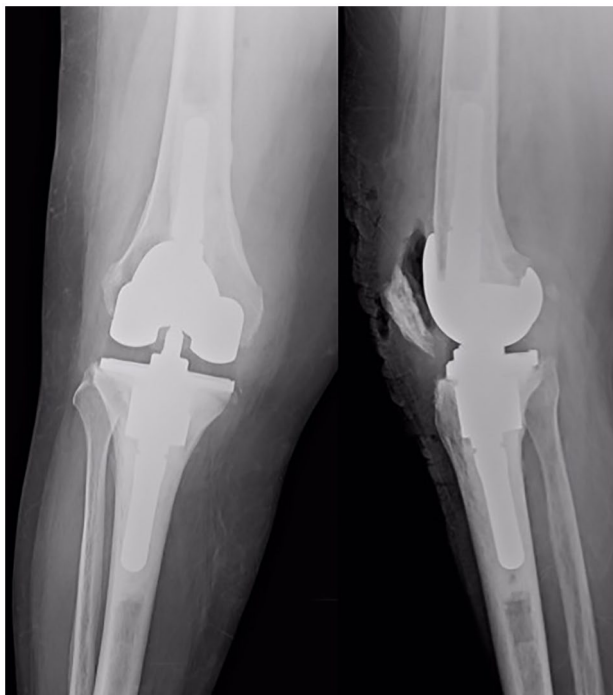In the late 90s, the quadriceps snip (QS) was popularized as a non-invasive extensile approach which facilitates exposure when patellar eversion was difficult to accomplish.<sup>17</sup> The popularity of this approach, where the proximal and lateral extension of the medial parapatellar arthrotomy act as a 'snip' into the vastus lateralis muscle, was related to its simplicity and because it does not change rehabilitation protocols. After the minimally invasive era in knee arthroplasty, patellar eversion has become unpopular and inconvenient in primary and especially in rTKA. Consequently the usefulness of a snip in non-everted patella has become very negligible.

As a final note, given the risks of postoperative extensor lag, patella avascular necrosis and rehabilitation restrictions, V-Y quadricepsplasty is rarely considered by the authors.<sup>18</sup>

## Reconstruction

### Fixation

In the revision scenario, the primary arthroplasty technique based on bone cuts is switched to a surgery of bone build-up. A main principle of TKA revision is to minimize additional bone resection. Saw usage should be limited to the implant removal, and to surface reshaping. A common mode of failure of rTKA is loosening due to insufficient fixation. A multizonal reconstruction combined with a rationalized use of cemented and cementless parts is vital to obtain a solid and durable fixation. Joint reconstruction is started with diaphyseal reaming. In aseptic cases, it is advisable to ream the tibia and femur together to save time and to stop at smaller diameters on the tibial side. Motor-driven reaming is more accurate;



**Fig. 3** Standard fixation for ‘easy-revision’ cases.

it allows a more gradual and progressive preparation of the diaphyseal canal and avoids component malposition because the surgeon can impose the reaming direction. Zone 3 (diaphyseal) fixation remains fundamental in rTKA to protect the juxta-articular bone until metaphyseal implant integration or when these zones are absent or highly compromised. Two methods of fixation may be used: fully cemented or press-fit cementless stems. The authors favour the former technique, particularly in combination with relatively short (60 mm long) stem extensions (Fig. 3), even if, in the available literature, no clear superiority of any type of stem fixation has been found.<sup>19</sup> Disadvantages of the use of cementless stems include a possible inferior immediate fixation, the possibility of ‘end-of-stem’ pain for diaphyseal edge loading, and distortion of proper condylar implant position in cases with anatomical deformities in either metaphyseal or diaphyseal regions. The geometrical centres of the tibial epiphysis and diaphysis are often not aligned, and linking zone 1 to zone 3 with an offset stem is required to avoid component overhang and bone uncoverage. Unfortunately, the use of offset stems in rTKA is related to an increased complexity of surgical actions and instruments. We feel that use of a relatively short cemented stem bypasses this problem and enhances fixation.

The second important surgical step is the establishment of the tibial platform. Reconstruction is started at the tibia as it affects both flexion and extension gaps. At this stage the surgeon is building the ‘basement’ of the

reconstruction. Only weak bone is removed, and surface contouring is performed. Correction of implant axial malalignment is the first action and is performed according to the planning. In case of component collapse, intramedullary resection guides should be placed to perform a stepped cut. The tibial component can be easily sized comparing the remaining tibial bone with a flipped trial component. It is afterwards connected to a trial stem and inserted into the prepared bone. An internally rotated tibia is a common finding. The tibial keel can be manually re-prepared in appropriated rotation using a bone nibbler or reciprocating saw. If a medial or a lateral peripheral bone defect is present a trial augment is added under the plastic tibia on the corresponding side and the varus-valgus alignment is re-checked. The use of a porous metal cones or sleeves revision system is mandatory in the presence of central defects in this area. The metaphysis (zone 2) is considered as the most important zone for a long-term implant fixation, as it avoids stress shielding phenomena correlated with a diaphyseal-only fixation. A closer fixation to the joint line also provides a better restoration of joint line and axial/rotational stability, and it is possible to remove in case of re-revision, much more easily than extensive cemented or osteo-integrated stems. Trabecular metal cones are used to reconstruct large cavitory defects and, recreating the cortical rim, they can also manage cortical defects eliminating the need for structural grafting.<sup>20</sup> In the presence of a good quality cancellous bone in the metaphysis a safely fixation may be reached using a short stem extension and a pressurized cementation technique. The epiphyseal region (zone 1) is partially or completely compromised in every revision by the failure process or the hardware removal. Peripheral defects can be filled up with cement augmented with screws or metal augments if the thickness is superior to 10 millimeters.<sup>21</sup> After completing the trial tibial reconstruction, the knee is maintained in flexion and a trial femoral component is chosen. The new component has to fit the medio-lateral width of the residual femur. The resulting antero-posterior size should be the size which better fills the flexion gap. The femoral component must be correctly rotated using the tibial platform as a main guide to recreate a symmetric flexion gap with collateral ligament equally tensioned. Obviously, this is all based on an accurate tibial resection. To avoid patellar maltracking problems, the epicondylar axis should be considered as a complementary guide. Posterior augments, preferentially on the lateral side, can be used to correct the internal rotation. At this point a ‘fine-tuning’ between flexion and extension gaps is carried out, changing the thickness of the polyethylene liner and the thickness of the distal femoral augments. If the flexion gap is too loose a larger component can be used. Porous metal augments can be fixed with screws to the bone of the epiphyseal zone to increase resistance to the rotational force.

Rarely, the surgeon may resect additional distal femur to stabilize the knee in extension if a fixed flexion contracture is present. ‘Mephistophelian’ is trying to restore the joint line with a millimetre accuracy at the anatomic joint line height. Soft tissue status including extensor mechanism tightness in rTKA should be weighted at least as much as the joint line bony landmarks to determine the final compromise for femoral component position and dimension. The patellar tendon is often retracted, and maintaining a pseudo patella baja is an acceptable balance between component fixation, patella kinematic and joint stability.<sup>22,23</sup> Attention must be paid only to avoid patella-liner impingement in deep flexion in particular with semi-constrained implants.

### Constraint

The constraint choice depends primarily on the state of the collateral ligaments and posterior capsule. Moreover, implant stability is indirectly related to the bone stock. Indeed, severe bone loss, generally on the distal femur, may affect the insertion of these peripheral stabilizers.<sup>24</sup> In case of component malposition or loosening, flexion and extension gap are unbalanced, resulting in a condition of ‘pseudo-instability’. In this case, the soft tissue envelope is maintained, and component revision allows a correct realignment and fixation with balanced flexion and extension gaps without using more constrained implants. Different solutions can be adopted, based on physical examination, to solve instability problems. Isolated polyethylene exchange should be considered in very selected patients with a global mild instability:  $< 5^\circ$  of recurvatum deformity and  $< 10\text{--}15$  mm of AP translation at  $90^\circ$  of flexion.<sup>25</sup> Liner exchange is also a valuable option in case of posterior cruciate insufficiency in cruciate-retaining implants: in this case, an ultracongruent polyethylene insert may be implanted if commercially available. In case of a mild asymmetric instability, a thicker liner may be implanted after a partial release of the medial or lateral structure. Despite isolated polyethylene exchange resulting in low morbidity, it is reported that this procedure has usually poor and unpredictable results. The cam-post mechanism of posterior stabilized (PS) implants is an artificial substitute for the posterior cruciate ligament, providing mainly AP stability but its function on varus-valgus stability is poor. When the going gets tough, a varus-valgus constrained insert (VVC) provides a greater varus-valgus stability, and it is primarily indicated in knees with a singular deficient collateral ligament.<sup>26</sup> VVC inlays provide some additional AP stability due to their rotational stabilizing effect. The ratio between femoral box and post dimensions of VVC implants differ between manufacturers, allowing different degrees of varus-valgus and rotational freedom. Some prosthetic designs, defined as semi-constrained, should be carefully evaluated, as their

constraining performances are overrated and are comparable to ‘reinforced’ PS implants. Because this greater constrained mechanism often lacks a rotational freedom, greater attention must be paid in choosing femoral and tibial component rotation, otherwise a limb torsional defect would be evident and early implant failure would be a consequence. Only mild recurvatum deformities can be corrected with femur distalization and a PS or VVC implant. Patients who have been chronically walking on this deformity with a quadriceps-avoidance gait could stretch the posterior capsule to the point that correction cannot be managed by just stuffing the joint, but would require the adjunction of an anti-recurvatum mechanism of hinged implants.<sup>27</sup> It is important to notice that positive varus-valgus stress in full extension is indicative of postero-medial or postero-lateral structure deficiency and a hinged prosthesis is required. These types of implants have limited usage among relatively young and active patients because they are associated with increased risk of a secondary revision due to early loosening caused by excessive stress at the fixation interface. Moreover, several rotating-hinge implants have a bulky rotating hinge mechanism that, associated with a long-stem for a strong fixation, cannot be implanted in small diameter tibial diaphysis as seen in women and even more in the presence of deformities. In conclusion, revising a TKA for instability always requires a frank diagnosis. Defining a mild pathological laxity is often not obvious, and surgeons must be cautious with sophisticated diagnosis of minor instability, such as mid-flexion instability.<sup>28</sup>

### Conclusion

TKA revisions are not all the same if the different failure mechanisms and patients’ characteristics are considered. In this heterogeneous situation, surgeons should adopt an algorithm to approach these cases and avoid failures. Pragmatically, stiff failed TKAs tend to fail in stiffness again and almost never in instability, while unstable TKAs tend to fail for instability again and almost never for stiffness. A meticulous preoperative evaluation and patient selection are essential for success. Knee revisions are time-consuming procedures, and only with an accurate preoperative plan and a narrow execution in the operating room could the surgical time be kept under 90–120 minutes to maintain acceptable periprosthetic joint infection incidence. We provided a surgical step-by-step procedure to overcome the majority of the challenges you might encounter in a revision setting. An important and often underestimated aspect is the patient counselling phase. Revisions, even though systematically approached, do not have reproducible outcomes like primary arthroplasty. Therefore, patients’ and surgeons’ expectation should be aligned before starting this surgical path.

**AUTHOR INFORMATION**

Institute for Complex Arthroplasty and Revisions (ICAR), Villa Ulivella Clinic, Florence, Italy.

Correspondence should be sent to: Andrea Baldini, Institute for Complex Arthroplasty and Revisions (ICAR), Villa Ulivella Clinic, via del Pergolino 4, 50139 Florence, Italy.  
Email: drbaldiniandrea@yahoo.it

**ICMJE CONFLICT OF INTEREST STATEMENT**

PS declares no conflict of interest relevant to this work.  
AB reports royalties from Zimmer-Biomet, consultancy for Permedica, Ethicon, Zimmer-Biomet and ConvaTec, all outside the submitted work.

**FUNDING STATEMENT**

No benefits in any form have been received or will be received from a commercial party related directly or indirectly to the subject of this article.

**OPEN ACCESS**

© 2021 The author(s)  
This article is distributed under the terms of the Creative Commons Attribution-Non Commercial 4.0 International (CC BY-NC 4.0) licence (<https://creativecommons.org/licenses/by-nc/4.0/>) which permits non-commercial use, reproduction and distribution of the work without further permission provided the original work is attributed.

**REFERENCES**

1. **Bae DK, Song SJ, Heo DB, Lee SH, Song WJ.** Long-term survival rate of implants and modes of failure after revision total knee arthroplasty by a single surgeon. *J Arthroplasty* 2013;28:1130–1134.
2. **Lombardi AV Jr, MacDonald SJ, Lewallen DG, Fehring TK.** Four challenges in revision total knee arthroplasty: exposure, safe and effective component removal, bone deficit management, and fixation. *Instr Course Lect* 2019;68:217–230.
3. **Hofmann S, Seitlinger G, Djahani O, Pietsch M.** The painful knee after TKA: a diagnostic algorithm for failure analysis. *Knee Surg Sports Traumatol Arthrosc* 2011;19:1442–1452.
4. **Saleh A, George J, Faour M, Klika AK, Higuera CA.** Serum biomarkers in periprosthetic joint infections. *Bone Joint Res* 2018;7:85–93.
5. **Yee DK, Chiu KY, Yan CH, Ng FY.** Review article: joint aspiration for diagnosis of periprosthetic infection. *J Orthop Surg (Hong Kong)* 2013;21:236–240.
6. **Parvizi J, Tan TL, Goswami K, et al.** The 2018 definition of periprosthetic hip and knee infection: an evidence-based and validated criteria. *J Arthroplasty* 2018;33:1309–1314.e2.
7. **Fehring TK, McAvoy G.** Fluoroscopic evaluation of the painful total knee arthroplasty. *Clin Orthop Relat Res* 1996;331:226–233.
8. **Nicoli G, Mercurio D, Cortese F.** Bone scan in painful knee arthroplasty: obsolete or actual examination? *Acta Biomed* 2017;88:68–77.

9. **Morgan-Jones R, Oussedik SI, Graichen H, Haddad FS.** Zonal fixation in revision total knee arthroplasty. *Bone Joint J* 2015;97-B:147–149.
10. **Della Valle CJ, Berger RA, Rosenberg AG.** Surgical exposures in revision total knee arthroplasty. *Clin Orthop Relat Res* 2006;446:59–68.
11. **Hirtler L, Lübbers A, Rath C.** Vascular coverage of the anterior knee region: an anatomical study. *J Anat* 2019;235:289–298.
12. **Rao AJ, Kempton SJ, Erickson BJ, Levine BR, Rao VK.** Soft tissue reconstruction and flap coverage for revision total knee arthroplasty. *J Arthroplasty* 2016;31:1529–1538.
13. **Reid MJ, Booth G, Khan RJ, Janes G.** Patellar eversion during total knee replacement: a prospective, randomized trial. *J Bone Joint Surg Am* 2014;96:207–213.
14. **Mason JB, Fehring TK.** Removing well-fixed total knee arthroplasty implants. *Clin Orthop Relat Res* 2006;446:76–82.
15. **Pasquier GJM, Hutten D, Common H, Migaud H, Putman S.** Extraction of total knee arthroplasty intramedullary stem extensions. *Orthop Traumatol Surg Res* 2020;106:5135–5147.
16. **DeHaan A, Shukla S, Anderson M, Ries M.** Tibial tubercle osteotomy to aid exposure for revision total knee arthroplasty. *JBS Essential Surg Tech* 2016;6:e32.
17. **Garvin KL, Scuderi G, Insall JN.** Evolution of the quadriceps snip. *Clin Orthop Relat Res* 1995;321:131–137.
18. **Abdel MP, Della Valle CJ.** The surgical approach for revision total knee arthroplasty. *Bone Joint J* 2016;98-B:113–115.
19. **Driesman AS, Macaulay W, Schwarzkopf R.** Cemented versus cementless stems in revision total knee arthroplasty. *J Knee Surg* 2019;32:704–709.
20. **Scott KL, Abdel MP, Hanssen AD.** Metaphyseal sleeves and cones in revision total knee arthroplasty. In: Bono J, Scott R, eds. *Revision total knee arthroplasty*. Cham: Springer, 2018.
21. **Lei PF, Hu RY, Hu YH.** Bone defects in revision total knee arthroplasty and management. *Orthop Surg* 2019;11:15–24.
22. **Grelsamer RP.** Patella baja after total knee arthroplasty: is it really patella baja? *J Arthroplasty* 2002;17:66–69.
23. **Bellemans J.** Restoring the joint line in revision TKA: does it matter? *Knee* 2004;11:3–5.
24. **Cottino U, Sculco PK, Sierra RJ, Abdel MP.** Instability after total knee arthroplasty. *Orthop Clin North Am* 2016;47:311–316.
25. **Mortazavi SMJ, Razzaghof M, Noori A, Okati A.** Late-onset de novo genu recurvatum after primary total knee arthroplasty: a potential indication for isolated polyethylene exchange. *Arthroplast Today* 2020;6:492–495.
26. **Nakano N, Matsumoto T, Muratsu H, Ishida K, Kuroda R, Kurosaka M.** Revision total knee arthroplasty using modern constrained condylar knee prosthesis. *Acta Ortop Bras* 2016;24:304–308.
27. **Rodríguez-Merchán EC.** Total knee arthroplasty using hinge joints: indications and results. *EFORT Open Rev* 2019;4:121–132.
28. **Vince K.** Mid-flexion instability after total knee arthroplasty: woolly thinking or a real concern? *Bone Joint J* 2016;98-B:84–88.