

# The Usefulness of Compliant Balloon for Recanalization of Acute Ischemic Stroke

Mun Soo Kang, MD, Jae Hoon Kim, MD, Hee In Kang, MD, Byung Gwan Moon, MD, Seung Jin Lee, MD, Joo Seung Kim, MD

Department of Neurosurgery, Eulji Hospital, Eulji University, Seoul, Korea

**Objective** : We report on our experience using a compliant balloon for treatment of thrombi resistant to simple mechanical thrombolysis.

**Methods** : We conducted a retrospective investigation of 46 consecutive acute ischemic stroke patients who were treated by intraarterial thrombolysis (IAT) between January 2008 and July 2010. We compared IAT results between the balloon group (BG) and the simple mechanical thrombolysis (with microcatheter and microguidewire) group (SG). The Thrombolysis in Myocardial Infarction (TIMI) grading system was used for grading of the degrees of vessel recanalization. In addition, a modified Thrombolysis in Cerebral Infarction (TICI) score was used for post-IAT TIMI grade 2 patients. Modified Rankin Scale scores were used at three months for assessment of clinical outcomes.

**Results** : Twenty of the 46 subjects were treated with a compliant balloon. The mean initial National Institutes of Health Stroke Scale score was 15.1 in the BG and 14 in the SG. The mean time from symptom onset to initiation of IAT was 225 minutes in the BG and 177 in the SG ( $p = 0.004$ ). The overall rate of successful recanalization (TIMI grade 2 or 3) was 85% in the BG and 73% in the SG ( $p = 0.476$ ). In the TIMI grade 2 group, modified TICI 2b was 90% in the BG and 16% in the SG ( $p = 0.001$ ). Postprocedure intraparenchymal hemorrhage occurred in two subjects in the BG and 10 subjects in the SG ( $p = 0.029$ ). No significant difference in clinical outcomes was observed between the BG and SG ( $p = 0.347$ ).

**Conclusions** : The compliant balloon showed high potential for recanalization following acute ischemic stroke, especially when simple mechanical thrombolysis had failed.

**Keywords** Balloon, Thrombolysis, Recanalization

J Cerebrovasc Endovasc Neurosurg.  
2012 September;14(3):141~147

Received : 2 July 2012

Revised : 27 July 2012

Accepted : 17 August 2012

Correspondence to Jae Hoon Kim, MD

Department of Neurosurgery, Eulji Hospital, 280-1 Hagye1-dong, Nowon-gu, Seoul 139-711, Korea

Tel : (001) 82-2-970-8268

Fax : (001) 82-2-979-8268

E-mail : grimi2@hanmail.net

This is an Open Access article distributed under the terms of the Creative Commons Attribution Non-Commercial License (<http://creativecommons.org/licenses/by-nc/3.0>) which permits unrestricted non-commercial use, distribution, and reproduction in any medium, provided the original work is properly cited.

## INTRODUCTION

The effectiveness of intraarterial thrombolysis (IAT) with recombinant pro-urokinase for treatment of acute ischemic stroke (AIS) has been demonstrated in a randomized controlled study; however, the disadvantages of this treatment include increased risk of post-procedure hemorrhage, failure to restore blood flow

in approximately one third of subjects, and excessive time requirements.<sup>4)</sup> In addition, neurovascular toxic effects of thrombolytic agents, including blood brain barrier disruption, have been suggested.<sup>7)</sup>

Many investigators studying the safety and usefulness of mechanical thrombolysis have asserted that it is associated with successful recanalization and better clinical outcomes for subjects with AIS.<sup>2)6)8-12)14)15)18)20-23)</sup>

Mechanical techniques include microcatheter and microguidewire aided clot disruption, balloon angioplasty, suction thrombectomy, clot retrieval, and stent placement. Among them, mechanical disruption using balloons is one of useful methods for improvement of the recanalization rate; however, balloon angioplasty is associated with a potential risk of vessel rupture and injury to perforators.<sup>6)</sup> To prevent this complication, we used low-pressure, compliant balloons.

The aim of this study is to evaluate the effectiveness of a mechanical technique using a compliant balloon in AIS patients in whom simple mechanical thrombolysis had failed.

## MATERIALS AND METHODS

### Subject selection

Forty six subjects who had undergone IAT at our center between January 2008 and July 2010 were selected from a database. Twenty six subjects were treated with a simple mechanical thrombolysis (microcatheter and microguidewire). The other 20 subjects were treated with a compliant balloon and subsequent low dose IA urokinase, if necessary, for distal emulsification of thrombus. Using subjects in the simple mechanical thrombolysis group (SG) as controls, we investigated the treatment results of the balloon group (BG).

Non-contrast computed tomographic (CT) scans were performed for initial evaluation of subjects presenting with AIS. Additional images, including CT angiography, diffusion weighted magnetic resonance (MR) image, perfusion MR image, and MR angiography were acquired when available. Subjects who presented within three hours after symptom onset were initially treated with intravenous tissue plasminogen activator (IV tPA), if there were no contraindications. Subjects who presented beyond three hours from symptom onset or with failed IV tPA therapy were treated with IAT. Initially, simple mechanical thrombolysis, including low dose urokinase and microcatheter/microguidewire was attempted. If the tar-

get vessel was still occluded, initiated use of a compliant balloon.

### Procedures

The endovascular procedure was performed under local anesthesia in a neuroangiography suite. Standard femoral artery access was obtained, and a 7F or larger bore guiding catheter was placed in the target vessel, just proximal to the occlusion. A microcatheter was introduced beyond the thrombus, and local angiography was performed in order to identify the distal burden of the thrombus and the exact location of the occlusion. Simple mechanical disruption using microguidewires and microcatheters was attempted before administration of a local injection of urokinase (50,000 U). When the target vessel was still occluded, a compliant balloon was used. Under road-mapping, a compliant 4 × 15 mm balloon (Hyperglide, ev3, Irvine, CA) was advanced into the thrombus. The balloon was slowly inflated several times for 20-30 seconds using a 1cc graduated pressure inflation syringe at the middle portion of the thrombus until recanalization was achieved. Then, multiple simple to-and-fro passages through the thrombus were performed using the deflated balloon, followed by an additional infusion of urokinase (20,000~50,000 U). If balloon angioplasty failed to restore blood flow, additional treatment was left to the discretion of the treatment physician. On average, the procedure was terminated around six hours after the onset of stroke.

### Data collection and outcome measurement

Data collected included demographics, stroke risk factors (diabetes, hypertension, and atrial fibrillation), initial National Institutes of Health Stroke Scale (NIHSS) score, thrombus location, and time to intervention. The Thrombolysis in Myocardial Infarction (TIMI) grade, with a TIMI grade 2 or 3, which is considered to represent successful recanalization, was used for assessment of angiographic recanalization.<sup>19)</sup> The modified Thrombolysis in Cerebral Infarction (TICI) score (grade 2a, partial perfusion with in-

complete distal filling of < 50% of the expected territory; grade 2b, partial perfusion with incomplete distal filling of 50-90% of expected territory) was used for post-IAT TIMI grade 2.<sup>5)</sup> DynaCT scanning was performed immediately in the angiography suite for assessment of intraparenchymal hemorrhage (IPH). We used a modified Rankin Scale (mRS) score (favorable outcome, score 0-2) at three months as a measure of clinical outcome.

### Statistical analysis

The Mann-Whitney U test was used for analysis of continuous variables, and chi-square statistics were used for analysis of categorical variables. We considered a value of  $p = 0.05$  as a level of statistical significance.

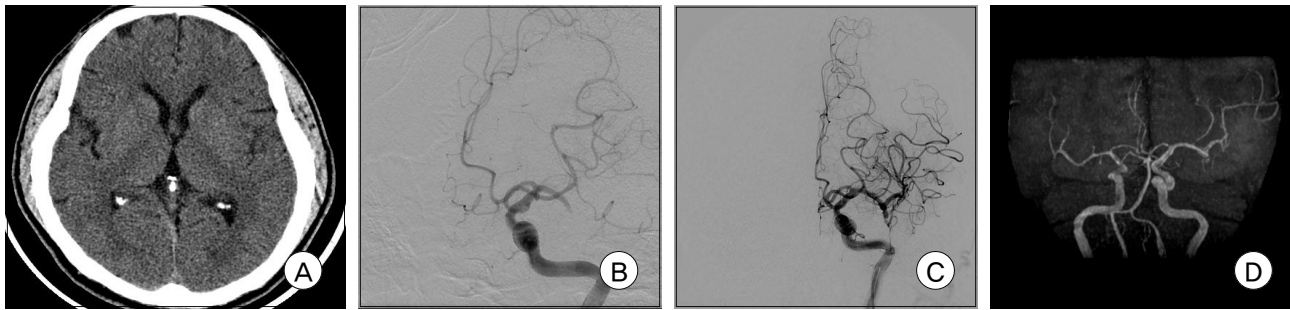
## RESULTS

The mean age of subjects in the BG was 67 years (range 36-85 years), and 12 subjects were male. The mean NIHSS score on admission was  $15.1 \pm 4.05$ . Eighteen subjects (90%) had anterior circulation stroke. Eleven subjects underwent IV tPA thrombolysis. The mean time from the onset of symptoms to the beginning of endovascular thrombolysis was  $225 \pm 52$  minutes. The mean age in the SG was 68 years (range 35-91 years), and nine of the subjects were men. The mean NIHSS score on presentation was  $14 \pm 5.11$  and 22 subjects (81%) had anterior circulation stroke. Twelve subjects underwent IV tPA thrombolysis. The mean time from the onset of symptoms to the begin-

**Table 1. Clinical and radiographic data for the balloon group and the simple mechanical thrombolysis group**

Variables	BG	SG	<i>p</i> value
Sex			0.087
Male	12	9	
Female	8	17	
Age (years $\pm$ SD)	$67.10 \pm 14.95$	$68.11 \pm 14.19$	0.815
Initial NIHSS score	$15.10 \pm 4.05$	$14.03 \pm 5.11$	0.450
Hypertension			0.348
Yes	12	19	
No	8	7	
Diabetes			1.000
Yes	8	10	
No	12	16	
Atrial fibrillation			0.552
Yes	9	14	
No	11	12	
IV tPA			0.552
Yes	11	12	
No	9	14	
Location of thrombus			0.783
ICA	10	11	
MCA	8	8	
VB system	2	5	
tandem	0	2	
TIMI 2-3			0.476
Yes	17	19	
No	3	7	
Modified TICl			0.001
2a	1	10	
2b	9	2	
Hemorrhage (any type)			0.029
Yes	2	10	
No	18	16	
Time to intervention (min)	$225.70 \pm 52.60$	$177.96 \pm 51.72$	0.004
mRS score 0-2 at 3 months			0.347
Yes	10	11	
No	10	15	

BG = balloon group; SG = simple mechanical thrombolysis group; NIHSS = National Institutes of Health Stroke Scale; IV tPA = intravenous tissue Plasminogen Activator; ICA = internal carotid artery; MCA = middle cerebral artery; VB = vertebrobasilar; TIMI = thrombolysis in myocardial infarction; TICl = thrombolysis in cerebral infarction; mRS = modified Rankin Scale



**Fig. 1.** A computed tomographic scan reveals no low density lesion in the left cerebral hemisphere (A). An angiography shows occlusion of the proximal portion of the left middle cerebral artery (B) and complete recanalization of the occluded vessel after balloon thrombolysis (C). Follow-up magnetic resonance angiography one week later demonstrates complete recanalization of the left middle cerebral artery (D).

ning of endovascular therapy was  $177 \pm 51$  minutes. The demographic and baseline clinical characteristics of the study sample are shown in Table 1.

Successful recanalization was achieved in 17 subjects (85%) in the BG, and in 19 subjects (73%) in the SG. In the TIMI grade 2 group, a modified TICI 2b was 90% in the BG and 16% in the SG ( $p = 0.001$ ). IPH (any type) occurred in two subjects in the BG and 10 subjects in the SG ( $p = 0.043$ ). A favorable outcome (mRS scores 0-2) was noted in 10 subjects (50%) in the BG and 11 subjects (42%) in the SG.

#### Case illustration

A 57-year-old male patient presented with a sudden onset of right hemiplegia and motor aphasia (NIHSS score 17). No apparent low density lesion was observed on the initial CT scan (Fig. 1-A). An angiography performed 223 minutes after the onset of symptoms revealed an occlusion of the proximal portion of the left middle cerebral artery (MCA) (Fig. 1-B). After identification of the exact location of the thrombus, we performed simple mechanical thrombolysis using a microcatheter and microguidewire, however, we did not achieve successful recanalization. Therefore, a thrombus disruption was performed using a compliant balloon, and angiography demonstrated complete recanalization (Fig. 1-C). A follow-up MR angiography obtained seven days later showed successful recanalization of the left MCA (Fig. 1-D). The patient showed good recovery with a three-month mRS score of 2.

## DISCUSSION

Findings of the present study provide evidence that thrombus disruption using a compliant balloon is a useful therapeutic method for subjects in whom simple mechanical thrombolysis has failed.<sup>1)</sup> In the current study, we analyzed differences in outcomes and other factors between the BG and SG. The mean time from symptom onset to initiation of IAT was longer in the BG than in the SG (225 minutes vs. 177,  $p = 0.004$ ). This discrepancy may be explained by the fact that we attempted recanalization of the occluded vessel using a balloon instead of repetitive simple mechanical disruption in patients who were delayed to IAT. The occurrence of IPH after procedures was the only significantly different factor observed between the two groups. IPH (any type) occurred more frequently in the SG than in the BG (38.4% vs. 10%,  $p = 0.029$ ). This result may be attributed to the fact that aggressive simple mechanical thrombolysis may have a potential to damage the endothelium of the occluded vessel and can result in hemorrhage or reperfusion injury into the infarcted tissue. As well as low-pressure, use of a compliant balloon may help to minimize vessel injury.

Although clinical outcomes and the rate of successful recanalization did not differ significantly between the two groups, a trend toward better outcomes and recanalization rates was observed in the BG (50% vs.

42.3% and 85% vs. 73%, respectively). Among post-IAT TIMI 2 patients, modified TICI 2b recanalization rate was higher in the BG than in the SG (90% vs. 16.7%).

Our results showed an 85% rate of partial or complete recanalization and a good clinical outcomes (mRS  $\leq$  2) rate of 50% in the BA group. In comparison with the PROACT trial using IA infusion of thrombolytics, these findings demonstrate a high recanalization rate and good clinical outcomes. Our data are consistent with the results of recent studies demonstrating that intracranial mechanical thrombolysis was effective in successful recanalization.<sup>4)6)13-15)20)21)</sup>

Symptomatic IPH is the most disastrous complication of IAT. In this study, the IPH (any type) rate of 10% (n = 2) is similar to a previously reported rate in a balloon series and there was no occurrence of symptomatic IPH.<sup>11-13)</sup> Nakano et al.<sup>12)</sup> performed angioplasty using coronary balloons. The incidence of symptomatic IPH in their BG was 2.9%. In a retrospective, multicenter trial with 59 AIS patients, Tokunaga et al.<sup>20)</sup> shown that seven subjects (12%) experienced hemorrhagic events after procedures and that severe IPH with neurologic deterioration was observed in only two subjects (4%).

Although the effectiveness of pharmacological thrombolysis has been reported, 40% of intracranial occlusions were resistant to thrombolytics.<sup>4)</sup> Many reports have thus stressed the importance of mechanical techniques as alternative therapy. Mechanical methods, including the simple microcatheter/microguidewire technique, clot retrieval device, balloon angioplasty, and stent deployment have been suggested as effective methods for recanalization of the occluded cerebral vessel.

Several mechanical devices for clot retrieval, including the MERCI Retrieval System and Penumbra Stroke System, have been devised. Many studies using these devices have reported that endovascular mechanical thrombectomy resulted in improvement of recanalization rates and patient outcomes.<sup>3)18)</sup> However, these devices are very expensive and are not always avail-

able, especially in developing countries.

Stent placement with balloon-mounted or self-expanding stents has been shown to be an effective therapy for AIS patients.<sup>2)10)23)</sup> However, stent placement has some drawbacks. First, in-stent thrombosis may occur. Second, the long-term patency of stents is still unknown. Also, the limited sample sizes of these studies may hinder the validity of comparisons to other trials. Recently, a retrieval stent was used for mechanical recanalization. Stampfl et al.<sup>17)</sup> reported a high rate of recanalization (88.8%) and a good outcome in 33.3% of patients with application of a retrieval stent. Further study will elucidate the efficacy and safety of this system.

Thrombus disruption using balloons is a simple and effective technique for achievement of successful recanalization within a short period of time. Ikushima et al.<sup>6)</sup> documented good angiographic and clinical outcomes with mechanical thrombus disruption, using deflated balloons. The rate of partial or complete recanalization among their patients was 100%. In that study, there were no cases of IPH and a good outcome was reported in 71% of patients at three months (mRS  $\leq$  2). Lum and colleagues<sup>11)</sup> performed thrombus disruptions using soft, silicone balloons in nine AIS patients. Recanalization (TIMI 2 or 3) was achieved in 89% of subjects and five subjects (56%) had good outcomes (mRS  $\leq$  2).

BA is associated with some potential risks, including vessel rupture, distal migration of thrombi during inflation, perforator injury, and spasm.<sup>6)</sup> Because cerebral vessels are suspended in subarachnoid space, they are susceptible to dissection and intimal tears during BA.<sup>3)</sup> To prevent vessel rupture or dissection, it is important to inflate balloons slowly. Verification of the exact sizes of vessels and the use of compliant balloons may reduce this disastrous complication. Ikushima et al.<sup>6)</sup> stressed that the use of deflated balloons can lower the risk of BA. We used a simple to-and-fro technique with deflated balloons after BA and did not experience vessel rupture or dissection.

Although distal embolism of fragmented thrombi is another potential risk of BA, intra-arterial administration of a small amount of urokinase (20,000~50,000 U) is expected to resolve this problem.

This study has some limitations. First, this study is inherently limited by small sample sizes. Second, this study is not a randomized trial and therefore has the limitation of methodology. Initially, we attempted to recanalize the occluded vessel by use of simple mechanical techniques. When simple mechanical thrombolysis had failed, we used a compliant balloon. Therefore, direct comparison between the SG and the BG may lower the statistical power of this study. Third, the current study is intended to demonstrate the effectiveness of balloons in recanalization of occluded arteries. Therefore, we did not correlate angiographic recanalization with follow-up image outcome. Nonetheless, when compared with the SG, the BG tended to show a longer time to IAT, but a better recanalization rate and a lower incidence of symptomatic hemorrhage. Therefore, mechanical thrombolysis using a balloon is a useful treatment for obtaining faster recanalization in patients who received delayed IAT.

## CONCLUSION

The use of compliant balloons showed high potential for recanalization of occluded vessels in AIS, especially in subjects in whom simple mechanical thrombolysis had failed. Further investigations will be needed in order to elucidate the effectiveness of BA in prospective and randomized trials.

## REFERENCES

1. Adams HP Jr, del Zoppo G, Alberts MJ, Bhatt DL, Brass L, Furlan A, et al. Guidelines for the early management of adults with ischemic stroke: a guideline from the American Heart Association/American Stroke Association Council, Clinical Cardiology Council, Cardiovascular Radiology and Intervention Council, and the Atherosclerotic Peripheral Vascular Disease and Quality of Care Outcomes in Research Interdisciplinary Working Groups: the American Academy of Neurology affirms the value of this guideline as an educational tool for neurologists. *Stroke*. 2007 May;38(5):1655-711.
2. Brekenfeld C, Schroth G, Mattle HP, Do DD, Remonda L, Mordasini P, et al. Stent placement in acute cerebral artery occlusion: use of a self-expandable intracranial stent for acute stroke treatment. *Stroke*. 2009 Mar;40(3):847-52.
3. Cohen JE, Itshayek E, Moskovic S, Gomori JM, Fraifeld S, Eichel R, et al. State-of-the-art reperfusion strategies for acute ischemic stroke. *J Clin Neurosci*. 2011 Mar;18(3):319-23.
4. del Zoppo GJ, Higashida RT, Furlan AJ, Pessin MS, Rowley HA, Gent M. PROACT: a phase II randomized trial of recombinant pro-urokinase by direct arterial delivery in acute middle cerebral artery stroke. PROACT Investigators. *Prolyse in Acute Cerebral Thromboembolism*. *Stroke*. 1998 Jan;29(1):4-11.
5. Higashida RT, Furlan AJ, Roberts H, Tomsick T, Connors B, Barr J, et al. Trial design and reporting standards for intra-arterial cerebral thrombolysis for acute ischemic stroke. *Stroke*. 2003 Aug;34(8):e109-37.
6. Ikushima I, Ohta H, Hirai T, Yokogami K, Miyahara D, Maeda N, et al. Balloon catheter disruption of middle cerebral artery thrombus in conjunction with thrombolysis for the treatment of acute middle cerebral artery embolism. *AJNR Am J Neuroradiol*. 2007 Mar;28(3):513-7.
7. Kidwell CS, Latour L, Saver JL, Alger JR, Starkman S, Duckwiler G, et al. Thrombolytic toxicity: blood brain barrier disruption in human ischemic stroke. *Cerebrovasc Dis*. 2008;25(4):338-43.
8. Kim D, Jahan R, Starkman S, Abolian A, Kidwell CS, Vinuela F, et al. Endovascular mechanical clot retrieval in a broad ischemic stroke cohort. *AJNR Am J Neuroradiol*. 2006 Nov-Dec;27(10):2048-52.
9. Kim DJ, Kim DI, Byun JS, Jung JY, Suh SH, Kim EY, et al. Simple microwire and microcatheter mechanical thrombolysis with adjuvant intraarterial urokinase for treatment of hyperacute ischemic stroke patients. *Acta Radiol*. 2008 Apr;49(3):351-7.
10. Levy EI, Mehta R, Gupta R, Hanel RA, Chamczuk AJ, Fiorella D, et al. Self-expanding stents for recanalization of acute cerebrovascular occlusions. *AJNR Am J Neuroradiol*. 2007 May;28(5):816-22.
11. Lum C, Stys PK, Hogan MJ, Nguyen TB, Srinivasan A, Goyal M. Acute anterior circulation stroke: recanalization using clot angioplasty. *Can J Neurol Sci*. 2006 May;33(2):217-22.
12. Nakano S, Iseda T, Yoneyama T, Kawano H, Wakisaka S. Direct percutaneous transluminal angioplasty for acute middle cerebral artery trunk occlusion: an alternative option to intra-arterial thrombolysis. *Stroke*. 2002 Dec;33(12):2872-6.
13. Nogueira RG, Schwamm LH, Buonanno FS, Koroshetz WJ, Yoo AJ, Rabinov JD, et al. Low-pressure balloon angioplasty with adjuvant pharmacological therapy in patients with acute ischemic stroke caused by intracranial arterial occlusions. *Neuroradiology*. 2008 Apr;50(4):331-40.
14. Ringer AJ, Qureshi AI, Fessler RD, Guterman LR, Hopkins

- LN. Angioplasty of intracranial occlusion resistant to thrombolysis in acute ischemic stroke. *Neurosurgery*. 2001 Jun;48(6):1282-8;discussion 1288-90.
15. Sorimachi T, Fujii Y, Tsuchiya N, Nashimoto T, Harada A, Ito Y, et al. Recanalization by mechanical embolus disruption during intra-arterial thrombolysis in the carotid territory. *AJNR Am J Neuroradiol*. 2004 Sep;25(8):1391-402.
  16. Srinivasan A, Goyal M, Stys P, Sharma M, Lum C. Microcatheter navigation and thrombolysis in acute symptomatic cervical internal carotid occlusion. *AJNR Am J Neuroradiol*. 2006 Apr;27(4):774-9.
  17. Stampfl S, Hartmann M, Ringleb PA, Haehnel S, Bendszus M, Rohde S. Stent placement for flow restoration in acute ischemic stroke: a single-center experience with the solitaire stent system. *AJNR Am J Neuroradiol*. 2011 Aug;32(7):1245-8.
  18. Struffert T, Köhrmann M, Engelhorn T, Nowe T, Richter G, Schellinger PD, et al. Penumbra stroke system as an "add-on" for the treatment of large vessel occlusive disease following thrombolysis: first results. *Eur Radiol*. 2009 Sep;19(9):2286-93.
  19. The Thrombolysis in Myocardial Infarction (TIMI) trial. Phase I findings. TIMI Study Group. *N Engl J Med*. 1985 Apr;312(14):932-6.
  20. Tokunaga K, Sugiu K, Yoshino K, Terai Y, Imaoka T, Handa A, et al. Percutaneous balloon angioplasty for acute occlusion of intracranial arteries. *Neurosurgery*. 2010 Sep;67 (3 Suppl Operative): ons 189-96;discussion ons 196-7.
  21. Yoneyama T, Nakano S, Kawano H, Iseda T, Ikeda T, Goya T, et al. Combined direct percutaneous transluminal angioplasty and low-dose native tissue plasminogen activator therapy for acute embolic middle cerebral artery trunk occlusion. *AJNR Am J Neuroradiol*. 2002 Feb;23(2):277-81.
  22. Yoon W, Park MS, Cho KH. Low-dose intra-arterial urokinase and aggressive mechanical clot disruption for acute ischemic stroke after failure of intravenous thrombolysis. *AJNR Am J Neuroradiol*. 2010 Jan;31(1):161-4.
  23. Zaidat OO, Wolfe T, Hussain SI, Lynch JR, Gupta R, Delap J, et al. Interventional acute ischemic stroke therapy with intracranial self-expanding stent. *Stroke*. 2008 Aug;39(8):2392-5.