

## Erratum to: Small Left Atrial Size Complicating Percutaneous Transcatheter Device Closure of Secundum Atrial Septal Defect with Conventional Approach

Hong Ki Ko, MD<sup>1</sup>, So Yeon Kang, MD<sup>2</sup>, Jeong Jin Yu, MD<sup>2</sup>, Jae-Kon, Ko, MD<sup>2</sup>, and Young-Hwue Kim, MD<sup>2</sup>

<sup>1</sup>Department of Pediatrics, Ajou University Hospital, Ajou University School of Medicine, Suwon,

<sup>2</sup>Division of Pediatric Cardiology, Department of Pediatrics, Asan Medical Center, University of Ulsan College of Medicine, Seoul, Korea

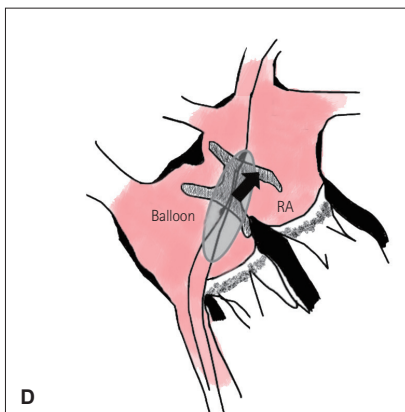
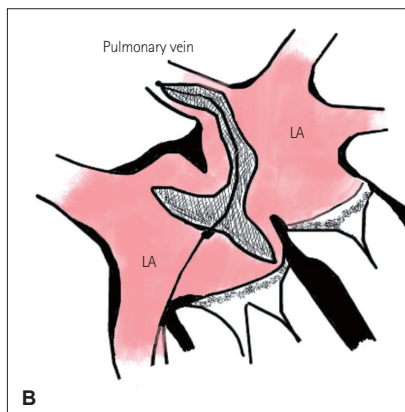
Korean Circ J 2015;45:216-224

<http://dx.doi.org/10.4070/kcj.2015.45.3.216>

In this article, on page 218, Fig. 2B and D have errors. Labeling of LA and RA was misplaced. We print the correct figure below.

The Publishing Company (Jin Publishing & Printing Co.) apologizes for the error made in the article and inconvenience it may have caused.

**Before correction**



**After correction**

